

Splenic hemangiosarcoma with abdominal dissemination in a dog

M. Yavuz GÜLBAHAR

Department of Pathology, Faculty of Veterinary Medicine, University of Yüzüncü Yıl, Van-TURKEY

Tolga GÜVENÇ

Department of Pathology, Faculty of Veterinary Medicine, University of Ankara, Ankara-TURKEY

Ömer BEŞALTI

Department of Surgery, Faculty of Veterinary Medicine, University of Ankara-TURKEY

Received: 10.12.1997

Abstract: A case of spontaneously ruptured splenic hemangiosarcoma with abdominal dissemination in a 12-year-old male German shepherd dog is described. At necropsy, a ruptured tumor mass was seen in the ventral region of the visceral surface of the spleen, and disseminated tumor masses were seen throughout the peritoneal cavity. Histologically, in both the primary tumor mass and disseminated tumor masses, atypical endothelial cells lining vascular spaces as small clefts or as cavernous channels were observed. Some immunological properties of tumor cells were determined for endothelial cell markers (factor VII-related antigen= von Willebrand's factor [vWf] and CD31 antigen), mesenchymal tissue marker (vimentin) and pericyte-smooth muscle marker (α -smooth muscle actin [α -SMA]). Tumor cells were positive for CD31, vimentin and α -SMA, whereas they were negative for vWf. According to morphological and immunohistochemical results, this case was diagnosed as hemangiosarcoma arising from the spleen with abdominal dissemination.

Key Words: Splenic hemangiosarcoma, dog, factor VIII-related antigen, CD31, vimentin, α -smooth muscle actin

Bir Köpekte Abdominal Yayılımlı Dalak Hemangiosarkomu Olgusu

Özet: Bu çalışmada 12 yaşlı, erkek, Alman Kurt köpeğinde spontan ruptur gösteren, abdominal yayılımlı dalak hemangiosarkomu olgusu tanımlandı. Nekropside dalağın visseral yüzeyinin ventralinde ruptur olmuş tümör kitlesi ile karın boşluğuna yayılım gösteren çok sayıda tümöral oluşumlar gözlemlendi. Histolojik olarak, hem primer hem de dissemine tümör kitlelerinde, kavernoöz kanallar ya da küçük yarıklar şeklindeki vasküler boşlukları çevreleyen atipik endotel hücreleri ile karşılaşıldı. Tümör hücrelerinin bazı immunolojik özellikleri belirlendi. Bu hücreler CD31, vimentin ve α -smooth muscle actin için pozitif, factor VIII related-antigen için negatif bulundu. Olgu, morfolojik ve immunohistokimyasal bulgulara göre abdominal yayılım gösteren dalak hemangiosarkomu olarak teşhis edildi.

Anahtar Sözcükler: Dalak hemangiosarkomu, köpek, factor VIII related-antigen, CD31, vimentin, α -smooth muscle actin

Introduction

Hemangiosarcoma (HS) is a malignant tumor of endothelial cells. Hemangiosarcoma occurs frequently in dogs, arising from the spleen, right atrium and liver. Splenic HS can closely resemble nodular hyperplasia or hematoma of the spleen, and its clinical diagnosis may be difficult (1, 2). It typically metastasizes widely through blood or lymphatic vessels since the tumor cells have easy access to vascular channels, especially the lungs, but can be found in almost any tissue (1). In the some cases, splenic HS may be ruptured and implants of the tumor may be found on the peritoneum (2, 3). In this study, various morphological and immunohistochemical features of spontaneously ruptured splenic HS with abdominal dissemination in a dog were determined, such as characteristic endothelial markers (factor VIII-related antigen = von Willebrand's factor [vWf], and CD31 antigen), mesenchymal tissue marker (Vimentin) and pericyte-smooth muscle marker (α -smooth muscle actin [α -SMA]).

Materials and Methods

The case was a 12-year-old, male, German shepherd dog. The animal was referred to the clinic with a history of progressive weight loss, anorexia and indifference to his surrounding over approximately the last twenty days, according to the owner. On clinical examination, the animal was thin, with marked skeletal muscle weakness. Radiography revealed numerous radiopaque masses of varying sizes throughout the abdomen. Fluid obtained by abdominal paracentesis was bloody, but did not coagulate. The results of laboratory examinations performed were as follows: erythrocyte $4.25 \times 10^6/\mu\text{l}$; Hb 10.4 g/dl; Htc 33%; WBC $19.6 \times 10^3/\mu\text{l}$. An exploratory laparotomy was performed for clinical diagnosis. In view of its critical conditions, the dog was euthanized by an overdose of pentobarbital sodium, with the owner's assent. The dog was necropsied and tissue samples were fixed in 10% buffered formalin, embedded in paraffin, sectioned at 5 μm and stained routinely with hematoxylin and eosin (HE). Selected section of the tumor tissue were

stained by Masson's trichrome and Gridley's reticulin staining methods. Immunohistochemical staining was used to detect characteristic endothelial markers (vWf and CD31), mesenchymal tissue marker (Vimentin), and pericyte-smooth muscle marker (α -SMA).

Immunohistochemical examinations for all markers were performed on formalin-fixed, paraffin-embedded tissues using an avidin biotin peroxidase complex (ABPC) method (4). All incubations were at room temperature. Deparaffinized sections were incubated 30 min in 0.3% H_2O_2 in methanol to inhibit endogenous peroxidase. Nonspecific binding of the secondary antibody was blocked with undiluted normal goat serum for 10 min. Sections were incubated with primary antisera (mouse anti-human F VIII-RAG, mouse anti human CD31, mouse anti vimentin, mouse anti-human actin smooth muscle DAKO, Denmark) at the optimal dilution of 1/100 for 1 hour. Biotinylated goat anti mouse immunoglobulin G and avidin-biotin peroxidase complex were administered according to the method described in the manual (Sigma). The chromogen used was 3-amino-9-ethylcarbazole (AEC substrate-chromogen, DAKO, Denmark). The sections were counterstained with Mayer's hematoxylin and coverslipped with aqueous mounting medium (DAKO, Denmark).

Results

Gross Findings:

At necropsy, a ruptured tumor mass, about 10 cm in size, in the ventral region of visceral surface of spleen was found. The free fluid-stained blood, about 300 ml, was detected in the abdominal cavity. The tumor was soft, reddish black to black in color, and there were hemorrhagic and necrotic areas on the cut surface. Tumor masses arising from the spleen, ranging from a pin head to 3 cm in size, were scattered throughout the abdominal cavity (Fig. 1). Metastatic tumor masses were encountered on the serosa of the pancreas and stomach, and the corpus of the vesica urinaria, diaphragm and omentum. They were easily removed from the organs. Small impression foci were seen on the parietal surface of the liver, in contact with diaphragmatic masses. These diaphragmatic tumoral masses were not implanted with liver serosa or paranchyma. Grossly, disseminated or metastasised masses were not seen in other organs or cavities.

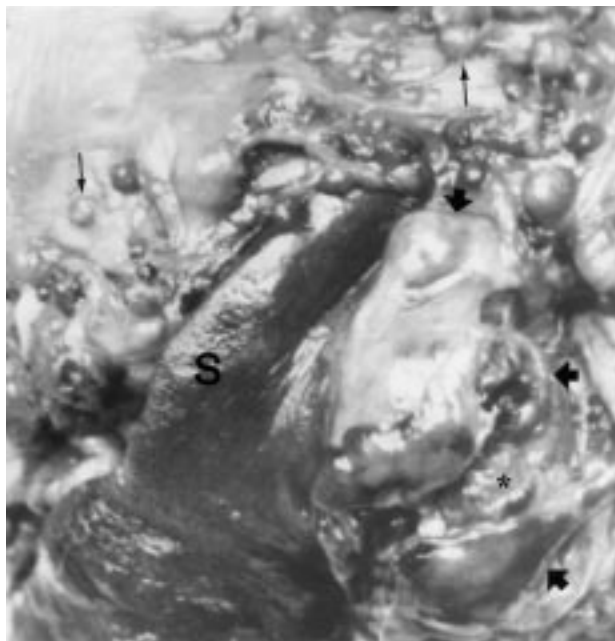


Figure 1. Primary tumor mass in the spleen(thick arrows) and numerous disseminated tumoral masses on the omentum (thin arrows). Note the ruptured region on the primary tumor mass (*). S=spleen.

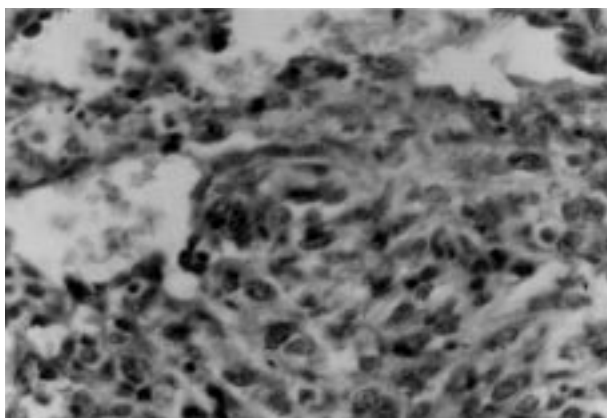


Figure 2. Neoplastic endothelial cells formed blood-filled cavernous spaces and solid areas from splenic tumor mass. HE. x 240.

Histological findings:

Diffuse necrotic and hemorrhagic areas were seen between the primary tumor tissue and normal tissue in the spleen. The tumor tissue was composed of immature endothelial cells forming solid areas or vascular spaces as small clefts but fewer, as cavernous channels separating and supported by collagen which were detected with Masson's trichrome stain. The vascular spaces lining

single or multiple layers of endothelial cells filled erythrocytes in small amounts were noticed in the tumor tissue. Higher magnification of the solid areas of some sections showed the small size of the splits, which were lined by a single layer of undifferentiated pleomorphic plump endothelial cells with hyperchromatic nuclei and pale staining abundant cytoplasm forming irregular vascular spaces (Fig. 2). Mitoses were uncommon in either cell element. Reticulin fibers around vascular spaces and also scattered reticulin in the solid tumor tissue were found positive with Gridley's reticulin staining method. All the scattered tumor masses limited to the serosal surface of the pancreas, stomach, vesica urinaria, and diaphragm and omentum showed the same histopathological features as those in the primary splenic tumor. They were enveloped by clear fibrous tissue. There were no tumoral or other lesions in any organs.

Immunohistochemically, tumor cells from primary tumor or disseminated tumor masses were negative for vWf (Fig. 3), whereas antigen was detected for CD31.




Figure 3. Negative reaction for vWf. ABPC. Mayer's hematoxylin counterstain. x 240.

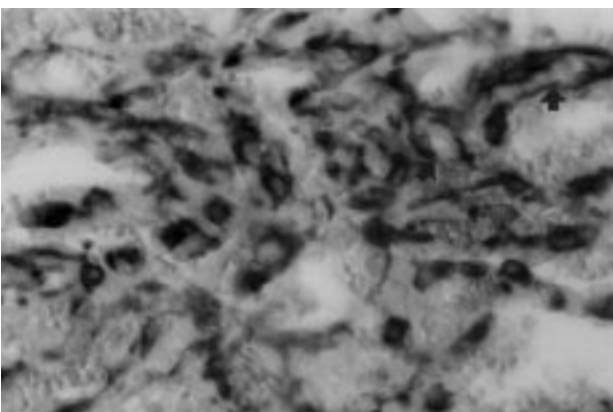


Figure 4. CD31 antigen positive neoplastic endothelial cells lining vascular structure (arrows). ABPC. Mayer's hematoxylin counterstain. x 320.

The monoclonal antibody CD31 reacted specifically with endothelial cells surrounding the blood-filled vascular spaces or/and solid areas in all tumor masses. The reaction was strong in the cytoplasm of cells and/or on cell surfaces (Fig. 4). Vimentin was identified in tumor cells as well as other mesenchymal components of the section. The cytoplasm of the atypical endothelial cells showed patchy staining for vimentin (Fig. 5). The monoclonal antibody against α -SMA reacted within the cytoplasm of stromal cells at the adjacent of plump endothelial cells lining the vascular spaces or within solid areas. The reaction was frequently discrete cytoplasmic unassociated with the vascular lumina (Fig. 6). The spindle-shaped to flattened cells forming the fibrous tissue enveloping tumoral growths which were disseminated in the abdominal cavity exhibited strong and diffuse reaction to α -SMA and vimentin. The sections from both the primary splenic tumor site and disseminated tumor implants showed same immunohistochemical staining properties.

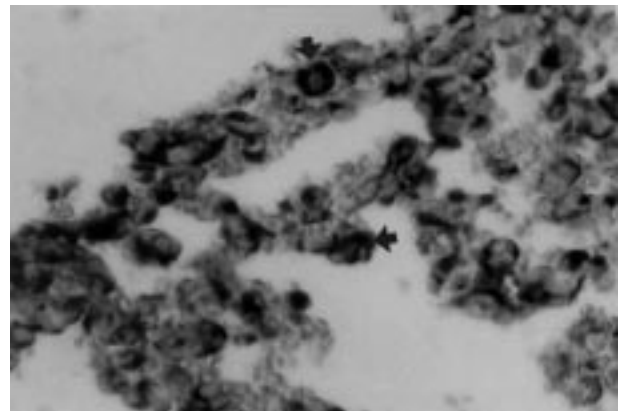


Figure 5. Immunoreaction with the anti-vimentin antibody in the cytoplasm of neoplastic endothelial cells lining the vascular structures (arrows). ABPC. Mayer's hematoxylin counterstain. x 320.

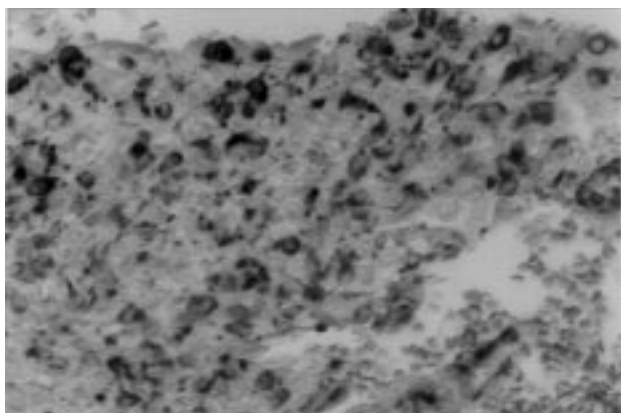


Figure 6. α -smooth muscle actin positive neoplastic cells in solid areas. ABPC. Mayer's hematoxylin counterstain. x 96.

Discussion

The gross and microscopic lesions reported in this study were typical of splenic hemangiosarcoma with abdominal dissemination following rupture. There are a few detailed reports of the disseminated pattern of splenic HS following tumor rupture in dogs (2, 3), although it is one of the most common metastatic pattern in human beings (5, 6). Early splenectomy has been found to minimize risk of metastasis before rupture is advisable, since the prognosis of untreated splenic hemangiosarcoma is poor (6). In this study, because splenic rupture occurred even though early splenectomy was not performed, the metastatic lesions were not seen in the other organs or cavities with the exception of the abdominal implants, without deep invasion.

For diagnostic purposes, vWf (7-9) and CD31 (10, 11) have been firmly established as neoplastic endothelial cell markers in paraffin wax-embedded, formalin-fixed tissue sections in human beings. Miller et al. (12) found that tumor cells of all cutaneous hemangiomas and hemangiosarcomas examined in cats were positive for vWf antigen. The immunohistochemical detection of both markers is a superior implement for canine neoplasms originating from the endothelial cells (13, 14). Ferrer et al. (14) reported that eleven of 15 hemangiosarcomas were positive for vWf and all 15 expressed the CD31 antigen. Von Beust et al. (13) also reported that four out of 36 canine hemangiosarcomas were negative in equivocal staining with vWf. The results of this study showed that immunohistochemical detection of the CD31 antigen had a higher value than vWf antigen, as has been reported in previous studies (10, 14).

The endothelial nature of the angiosarcomas is conclusive, but in the poorly differentiated angiosarcomas, it may be disputed whether the origin of the endothelial cells is a lymphatic vessel (lymphangiosarcoma) or blood vessel (hemangiosarcoma) for CD31 and vWf markers. Lymphatic endothelium generally does not stain for vWf (15) but may stained for

CD31 (14). In this study, tumor cells were negative for vWf, but CD31 was positive in the cells lining the blood-filled vascular spaces, indicating derivation of the tumor from blood vascular endothelium. Some immunohistochemical studies suggest a lymphatic origin, whereas ultrastructural studies imply derivation from blood vessels in human cutaneous angiosarcoma (16). Because markers specific for distinguishing lymphatic and blood vessel endothelium are not available yet, differential diagnosis of these tumors should be based on ultrastructural features such as basal lamina, micropinocytotic vesicles, intercellular tight junction and pericytes (1, 16, 17).

Vimentin is an intermediate filament and it has been identified in tumor cells of mesenchymal origin. Moore et al. (18) reported that canine hemangiosarcomas are positive for vimentin, but not for other intermediate filaments. Identification of vimentin in the tumor cells of this case is consistent with its mesenchymal origin. Many vascular neoplasms have a typical macroscopic and histologic appearance but poorly differentiated mesenchymal tumors may be a diagnostic risk (1).

Alpha-SMA is expressed in vascular tunica media, pericytes, and myoepithelial cells (15, 19). In this study, α -SMA had a disperse reaction in the cytoplasm of stromal cells located between the vascular spaces lining the plump endothelial cells. Johnson et al. (15) have established the distribution of supportive elements such as pericytes or smooth muscle cells to be a concentric arrangement around the endothelium, and that some unassociated with vascular lumina stained with antibody to α -SMA in benign vascular neoplasms of young horses. Since pericytes are associated with the early stages of capillary proliferation, they must be distinguished from smooth muscle cells (15, 20). For this purpose, Little et al. (8) reported that desmin staining could be useful in differentiating between positive smooth muscle cells and negative pericytes, but in our study desmin-staining was not performed.

References

1. Pulley, L.T. and Stannard, A.A.: Tumors of the skin and soft tissues. In: Tumors of Domestic Animals, 3rd Edit., ed. Moulton, J.E., University of California Press, Berkeley, California, p. 23-87, 1990.
2. Robinson, W.F. and M.G. Maxie: The Cardiovascular System. In: Pathology of Domestic Animals, ed. Jubb, K. V. F., Kennedy, P.C., and Palmer, N., 4th ed. Academic Press, Inc., California, p. 98-100, 1993.
3. Zhao, D., Yamaguchi, R., Tateyama, S., Ogawa, H. and Yamazaki, Y.: Canine splenic hemangiosarcoma with abdominal dissemination. J. Vet. Med. Sci., 1994; 56: 753-55.
4. Hsu, S.M., Raine, L. and Fanger, H.: The use of avidin-biotin-peroxidase complex (ABC) in immunoperoxidase techniques: a comparison between ABC and unlabelled antibody (PAP) procedures. J. Histochem. Cytochem. 1980; 29: 577-80.

5. Stutz, F.H., Tormey, D.C. and Blom, J.: Hemangiosarcoma and pathologic rupture of the spleen. *Cancer*, 1973; 31: 1213-15.
6. Autry, J.R. and Weitzner, S.: Hemangiosarcoma of spleen with spontaneous rupture. *Cancer*, 1975; 33: 534-39.
7. Sehested, M. and Hou-Jensen, K.: Factor VIII-related antigens as an endothelial cell marker in benign and malignant diseases. *Virchows Arch. [A]*, 1981; 391: 217-25.
8. Little, D., Said, T.W., Siegel, R.J., Fealy, M. and Fishbein, M.C.: Endothelial cell markers in vascular neoplasms: an immunohistochemical study comparing factor VIII-related antigen, blood group specific antigens, 6-keto-PGF1 alpha and *Ulex europaeus* 1 lectin. *J. Pathol.*, 1986; 149: 89-95.
9. Weidner, N., Semple, J.P., Welch, W.R. and Folkman, J.: Tumor angiogenesis and metastasis-correlation in invasive breast carcinoma. *N. Engl. J. Med.*, 1991; 324: 1-8.
10. Parums, D.V., Cordell, J.L., Micklem, F., Heryet, A.R., Gatter, K.C. and Masons, D.Y.: JC70: a new monoclonal antibody that detects vascular endothelium associated antigen on routinely processed tissue sections. *J. Clinical Pathol.*, 1990; 43: 752-57.
11. Kuzu, I., Bicknell, R., Fletcher, C.D. and Gatter, K.C.: Expression of adhesion molecules on the endothelium of normal tissues vessels and vascular tumors. *Lab. Invest.*, 1993; 69: 322-28.
12. Miller, M.A., Ramos, J.A. and Kreeger, J.M.: Cutaneous vascular neoplasia in 15 cats: Clinical, morphological, and immunohistochemical studies. *Vet. Pathol.*, 1993; 29: 329-36.
13. Von Beust, B.R., Suter, M.M. and Summer, B.A.: Factor VIII-related antigen in canine endothelial neoplasms: an immunohistochemical study. *Vet. Pathol.*, 1988; 25: 251-55.
14. Ferrer, L., Fondevila, D., Rabanal, R.M. and Vilafranca, M.: Immunohistochemical detection of CD31 antigen in normal and neoplastic canine endothelial cells. *J. Comp. Pathol.*, 1995; 112: 319-26.
15. Johnson, G.C., Miller, M.A., Floss, J.L. and Turk, J.R.: Histologic and immunohistochemical characterization of hemangiomas in the skin of seven young horses. *Vet. Pathol.*, 1996; 33: 142-49.
16. Holden, C.A., Spittle, M.F., and Jones, E.W.: The histogenesis of angiosarcoma of the face and scalp: an immunohistochemical and ultrastructural study. *Histopathology*, 1987; 11: 37-51.
17. Swayne, D.E., Mahaffey, E.A. and Haynes, S.G.: Lymphangiosarcoma and haemangiosarcoma in a cat. *J. Comp. Pathol.*, 1989; 100: 91-6.
18. Moore, H.S., Madewell B.R. and Lund, J.K.: Immunohistochemical evaluation of intermediate filament expression in canine and feline neoplasms. *Am. J. Vet. Res.*, 1989; 50: 88-92.
19. True, L.D.: Other antigens. In: *Atlas of Diagnostic Immunohistopathology*, ed. True LD, J.B. Lippincott, Philadelphia, p. 8. 7., 1990.
20. Nehls, V., Denzer, K. and Drenckhahn, D.: Pericyte involvement in capillary supporting during angiogenesis in situ. *Cell Tissue Res.*, 1992; 270: 469-74.