

Sexual analysis in turkey (*Meleagris gallopavo*) neurocranium using geometric morphometric methods

Ozan GÜNDEMİR¹, Ermiş ÖZKAN¹, Mustafa Orhun DAYAN², Sedat AYDOĞDU^{2*}

¹Department of Anatomy, Faculty of Veterinary Medicine, İstanbul University-Cerrahpaşa, İstanbul, Turkey

²Department of Anatomy, Faculty of Veterinary Medicine, Selçuk University, Konya, Turkey

Received: 28.10.2019 • Accepted/Published Online: 28.03.2020 • Final Version: 02.06.2020

Abstract: The aim of this study was to obtain morphometric data by applying geometric analysis to the neurocranium of the turkey and to statistically reveal the differences between males and females using these data. In the present study, 14 (7 males, 7 females) turkey skulls were used. The neurocrania of the samples were photographed and put into an electronic environment to be marked. Neurocrania were examined from 4 different regions (caudal, ventral, dorsal, and lateral). Compared to PC1 obtained in dorsal sampling, the difference between points 9 and 10 and 3 to 2 was significantly higher in males. Caudal examination showed that male samples were wider laterally. In ventral measurements, it was seen that points 3 and 7 in the male were more anterior and point 1 was more posterior. The lateral area was seen to be higher in females and longer in the anterior-posterior direction in males. The greatest statistical difference was seen in landmark 4 (middle point of foramen magnum's dorsal margin), obtained as a result of caudal geometric analysis ($P < 0.001$). The conditions of the points determined in this study in comparison with each other were determined in the coordinate system, and the differences were revealed. Geometric analysis was done in 4 different views, and statistical values were determined for sex differences in the landmarks used.

Key words: Anatomy, geometric morphometry, neurocranium, turkey

1. Introduction

The skulls of the poultry were examined in 2 parts (neurocranium and splanchnocranium), as in mammals [1]. The neurocranium is composed of the occipital bone, sphenoid bone, parietal bone, frontal bone, and temporal bone. Unlike mammals, there is no interparietal bone. The occipital condyle is also single in poultry [1,2]. Sutures close at early ages in the bones of poultry. In adult poultry, the borders of the sutures disappear and they become indistinguishable [3].

The morphological and morphometric studies of skull in poultry are presented in the references. The differences between males and females have been revealed statistically through morphometric measurements in a study conducted with turkeys [4]. In another study, the differences between guinea fowl and turkey have been revealed by using the neurocrania of these 2 species [5]. In addition, in recent years, morphometric measurements have been made on 3-dimensional poultry skull models obtained using medical imaging methods [6].

Geometric morphometry is a kind of shape analysis that has come into use in recent years. In this technique,

specific points are determined on the sample and geometric shapes are obtained. These shapes are examined independently from the original sample. The geometric shape is analyzed using the distances, angles, and slopes between these points [7,8]. The anatomical measurements are limited in normal morphological anatomy. However, these points are transferred to the coordinate system in geometric morphometry, and more information and better visualization are obtained [9]. A comparative study has been conducted on geometric morphometry and conventional geometric methods [10]; it was stated in this study that the landmark method provided more information.

Geometric analysis studies have been initiated in the veterinary field. In a previous study, hare bones were examined using the geometric morphometry method to determine the differences between males and females [11]. In mammals with large morphological differences in the skull bones, differences within the same species have been revealed with this method. According to the results of the geometric analysis of the equine skull in different domestic breeds, it has been determined that smaller

* Correspondence: saydogdu@selcuk.edu.tr

species have shorter faces and wider skulls than larger species [12,13]. In a study in which the skull bones of Anatolian sheep and Akkaraman sheep were investigated by geometric morphometry, percentages of the principal component obtained as results of the study have been reported to explain the differences between species [14]. In another study, the differences between these 2 species were demonstrated by taking the measurements of the mandible bones of both species [15]. In a study where the morphometric variation of the skull was analyzed in the Magellanic penguin, it was determined that the minimum variation in the skull bones was in the development groove of the salt gland, and the maximum variation was in the extension of the temporal fossa [16].

Principal component analysis reveals dominant patterns on graphics [17]. This method finds the eigenvalues and eigenvectors of the matrix which comprises the distances between the points determined on the shape. Eigenvalues and eigenvectors are parameters used to assess the absolute contribution of each of the principal component bands [18]. The highest eigenvalue data result obtained is called PC1 (principal component 1). The results of the analysis obtained by geometric analysis programs are used to reveal the differences between nonlinear shapes. By using principal components, shape variations between groups can also be compared and evaluated statistically [19].

The motivation of the study was not to examine the skull of the turkey in terms of sex with the new geometric morphometric methods; the aim of this study was to obtain morphometric data using geometric analysis for the neurocranium of the turkey, and to statistically reveal the differences between the males and females using these data.

2. Materials and methods

In this study, 14 healthy American Bronze turkey (7 males, 7 females) skulls were obtained from slaughterhouses around İstanbul. The male and female skulls were separated before the measurements were taken. The photos of the skulls of the samples were taken using a Canon 650D at a right angle from a distance of 20 cm. The photos were then transferred to a computer. Macro shooting mode was used for clarity in all photos. The study was approved by the Local Ethics Committee of İstanbul University – Cerrahpaşa, Faculty of Veterinary Medicine (approval number: 2019/38; date: 19/09/2019).

The turkey neurocrania were examined in 4 different regions, using 11 landmarks from dorsal examination (Figure 1), 6 landmarks from caudal examination (Figure 2), 9 landmarks from ventral examination (Figure 3), and 5 landmarks from lateral examination (Figure 4).

In order to mark the landmarks, the photos were first recorded as tps files using tpsUtil (v. 1.74). These files were transferred into the tpsDig (v. 2) program in which the

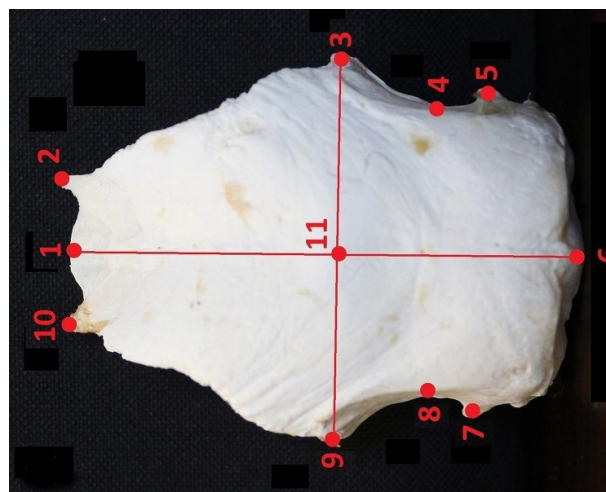


Figure 1. Dorsal landmarks; (1) Middle point of frontonasal suture; (2) Craniolateral terminal point of os frontale (right); (3) Processus postorbitalis (right); (4) Middle point of crista temporalis (right); (5) Outermost point of crista nuchalis transversa (right); (6) Prominentia cerebellaris; (7) Outermost point of crista nuchalis transversa (left); (8) Middle point of crista temporalis (left); (9) Processus postorbitalis (left); (10) Craniolateral terminal point of os frontale (left); (11) Middle of maximum neurocranial width.

marking was performed; each photo was marked one by one. The marked data were converted into a text file and opened in the Past (v. 4.01) program for statistical analysis. The data were also converted into 2 dimensions for morphoJ (v. 1.07a) morphometry software through this program. Principal component analysis was applied in Past, and the shape variations were obtained. Each principal component was arranged based on order of importance. The morphoJ (v. 1.07a) morphometry program was then used in order to explain the changes caused by the results using visual data. In this program, the visual printouts of the statistical data obtained by applying principal component analysis were taken again and the points of shape deformations were determined. Canonical variate analysis (CVA) and a discriminant analysis were performed using morphoJ. The landmarks were connected to each other through this program and the shape images were obtained. In order to determine the difference between female and male more clearly, the set scale factor as “5 number” and landmark point as “12 number” were used.

One-way ANOVA test was done to statistically reveal the difference between the females and males for the landmarks examined in the geometrical plane. Sum of squares and mean square were obtained. The difference levels of landmarks among themselves were determined statistically using F and T-tests (2 samples). In addition,

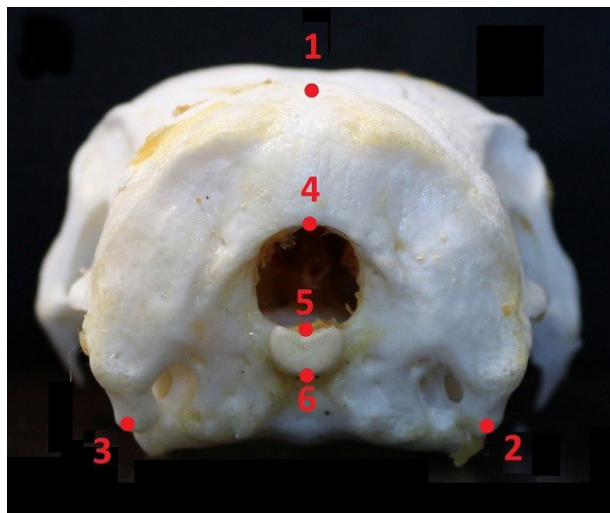


Figure 2. Caudal landmarks; (1) Middle point of crista nuchalis temporalis; (2) Terminal point of processus paroccipitalis (right); (3) Terminal point of processus paroccipitalis (left); (4) Middle point of foramen magnum's dorsal margin; (5) Middle point of foramen magnum's ventral margin; (6) Middle point of ventral margin of condylus occipitales.

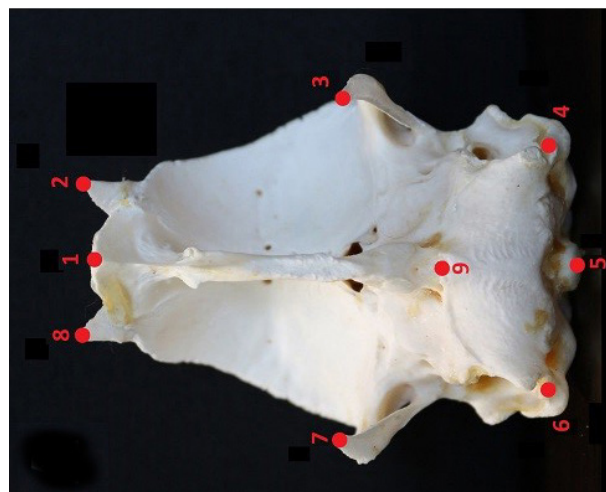


Figure 3. Ventral landmarks; (1) Middle point of frontonasal suture; (2) Craniolateral terminal point of os frontale (right); (3) Point of processus postorbitalis (right); (4) Point of processus paroccipitalis (right); (5) Condylus occipitalis; (6) Point of processus paroccipitalis (left); (7) Point of processus postorbitalis (left); (8) Craniolateral terminal point of os frontale (left); (9) Point of rostral parasphenoidale.

graphics of 95% confidence analysis of the female and male geometric features were applied; how many of the samples were in this range was also shown with graphics. The Past (v. 4.01) program was used for all statistical analysis.

3. Results

Thirteen principal components were obtained with 11 landmarks performed in dorsal sampling. Among these components, the first principal component alone constituted 39.6% of the total variation. The second principal component constituted 17.12% of the total variation, and the third principal component constituted 11.96% of the total variation (Table 1). The first 3 principal components explained 68% of sex discrimination with these rates using turkey neurocrania. It was determined that the majority of the samples used in the study were within the confidence range of the 95% confidence analysis created between the sexes on the ellipse graph. Only 1 male sample was observed to differentiate from the females definitely. According to PC1, the greatest differences between male and female were observed at points 2, 3, 8, 9, 10, and 11 in the graphics obtained using the morphology program (morphoJ). It was found that the differences between points 9 to 10 and 3 to 2 were especially higher in males. The difference between male and female in the frontal region in the neurocranium was found to be lower (Figure 5a).

Eleven principal components were obtained with 6 landmark points applied in caudal measurements. The first principal component constituted 51.89% of all variation.

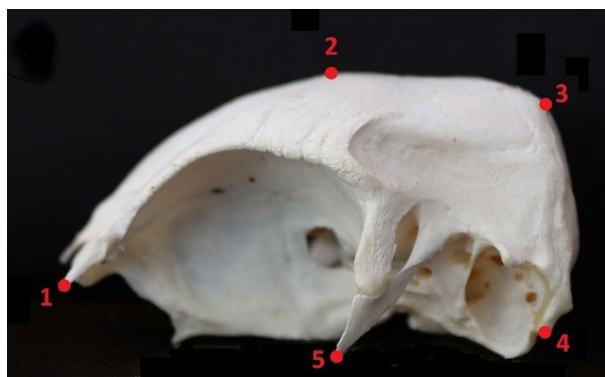


Figure 4. Lateral landmarks; (1) Craniolateral terminal point of os frontale; (2) Highest point of the skull; (3) Middle point of crista nuchalis temporalis; (4) Terminal point of processus paroccipitalis; (5) Point of processus postorbitalis.

The second principal component constituted 24.07% of the total variation, and the third principal component constituted 11.09% of the total variation. These 3 principal components accounted for 87.05% of the total variation in the male/female separation (Table 1). Caudal examination showed that male samples were wider laterally. However, in this part, as seen in points 1, 2, and 3, the occipital region of females was longer than that of males (Figure 5b). No difference was observed between sexes in the ellipse graphic of 95% confidence. It was determined that all of the individuals were in the confidence interval.

Table 1. (PC) Principal component; (E) Eigenvalue; (V) Variance.

PC	Dorsal		Caudal		Lateral		Ventral	
	E	V%	E	V%	E	V%	E	V%
1	0.000487374	39.609	0.000613603	51.897	0.00236441	59.943	0.000333948	34.324
2	0.000210754	17.128	0.000284618	24.072	0.000809095	20.512	0.000265834	27.323
3	0.000147245	11.967	0.000131133	11.091	0.00038323	9.7157	0.000107935	11.094
4	0.000137309	11.159	7.94792E-05	6.7222	0.000182352	4.623	8.35076E-05	8.5832
5	6.35283E-05	5.163	3.37783E-05	2.8569	0.000137791	3.4933	5.88203E-05	6.0458
6	5.12112E-05	4.162	2.09934E-05	1.7756	6.3394E-05	1.6072	5.60519E-05	5.7612
7	4.88053E-05	3.9664	1.61927E-05	1.3695	4.14802E-06	0.10516	2.22476E-05	2.2867
8	2.81602E-05	2.2886	2.46268E-06	0.20829	5.59121E-16	1.4175E-11	1.80718E-05	1.8575
9	2.17052E-05	1.764	7.87489E-08	0.0066604	2.56226E-16	6.4959E-12	1.28019E-05	1.3158
10	1.47982E-05	1.2027	1.36361E-16	1.1533E-11	7.1953E-17	1.8242E-12	6.7117E-06	0.68986
11	8.00558E-06	0.65062	3.9273E-17	3.3216E-12	-	-	4.11592E-06	0.42305
12	6.0222E-06	0.48943	-	-	-	-	2.83521E-06	0.29141
13	5.53726E-06	0.45002	-	-	-	-	3.37279E-08	0.0034667

Nine landmarks were used in the ventral measurements, and 13 principal components were obtained. It was observed that the highest principal component value constituted 34.32% of the total variation. The second principal component constituted 27.32% of the total variation, and the third principal component constituted 11.09% of the total variation. In the graphic of 95% confidence analysis used for sex discrimination, it was seen that 4 females and 6 males were separated from each other. It was observed that all of the females were on the positive side of the y plane and all of the males except for one were on the negative side. In this part, it was seen that points 3 and 7 in the male were more anterior and point 1 was more posterior (Figure 5c).

Five landmarks were used in lateral measurements and a total of 10 principal components were obtained. The highest principal component obtained in the study was observed in the lateral region. This principal component constituted 59.94% of the lateral variation (Table 1). It was determined that the second principal component constituted 24.07% of the total variation. The values of 6 males used in the study can be distinguished from female samples using lateral landmarks, as seen in the ellipse graphic of 95% confidence. This part was seen to be higher in females and longer in the anterior-posterior direction in males (Figure 5d). Furthermore, all of the individuals were in the confidence interval in lateral measurements.

The ellipse graphic of 95% confidence for all examinations relating to the sex discrimination of individuals is presented in Figure 6.

Table 2 shows the statistical differences in caudal, dorsal, lateral, and ventral landmarks for female and male individuals using one-way ANOVA. Sum of squares and mean square values were obtained. The statistical values that the landmarks used in each geometric analysis to reveal the differences between the sexes are given in Table 3. The greatest statistical difference obtained as a result of caudal geometric analysis is seen in landmark 4 (middle point of the foramen magnum's dorsal margin) ($P < 0.001$).

4. Discussion

In this study, sex determination was attempted using geometric morphometry in turkey skulls. For this purpose, markings were performed and examined by taking samples in 4 different examinations. The highest statistical differences between males and females were observed in lateral and ventral examinations. It was observed that the difference between sexes in the postorbital process, for which the geometric method was applied, was at significant levels in ventral, lateral, and dorsal samples. The conditions of the points determined in this study in comparison with each other were determined in the coordinate system, and the differences were revealed. In a normal morphometric study, it was reported that all of the measurements in the turkey skull were greater in males than in females [4].

It was reported in a geometric analysis study conducted with poultry that the differences between species were revealed using the landmarks determined in the skull. In this study, in which sex determination was not performed,

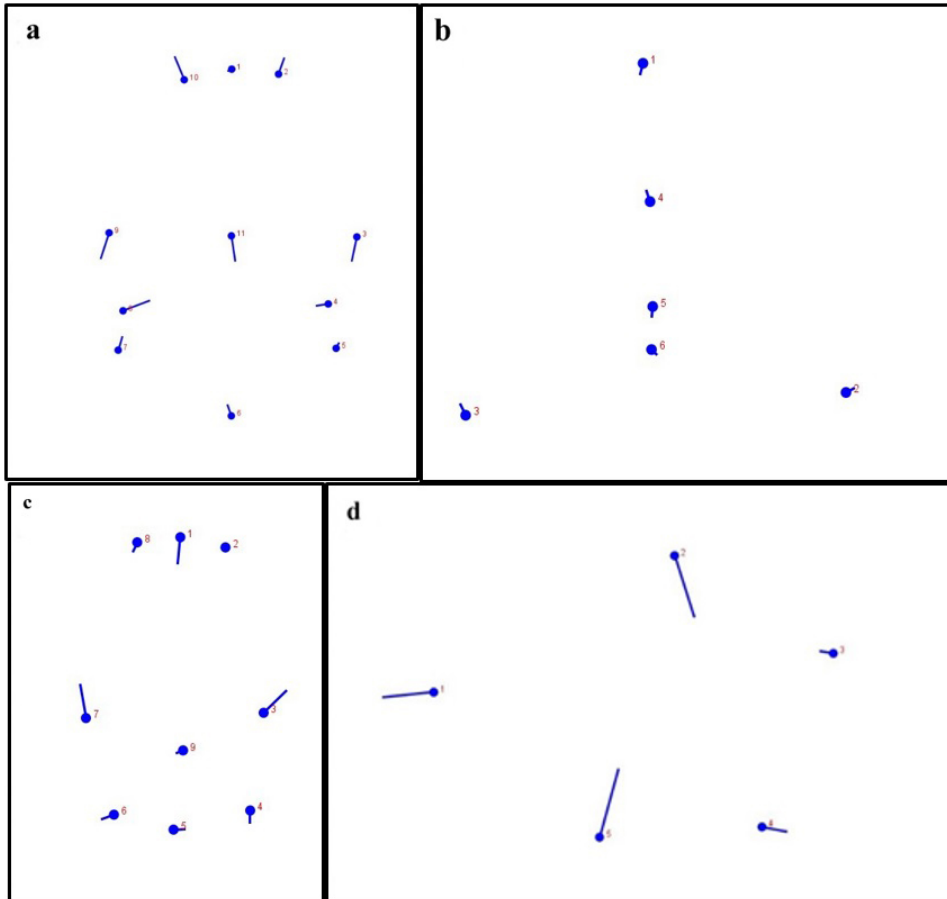


Figure 5. Linear representation of shape differences for the first principal component (morphoJ). Points represent female samples. The extension line of the points shows the size and in which direction the male samples differ from the female samples. (a) Dorsal examination; (b) Caudal examination; (c) Ventral examination; and (d) Lateral examination.

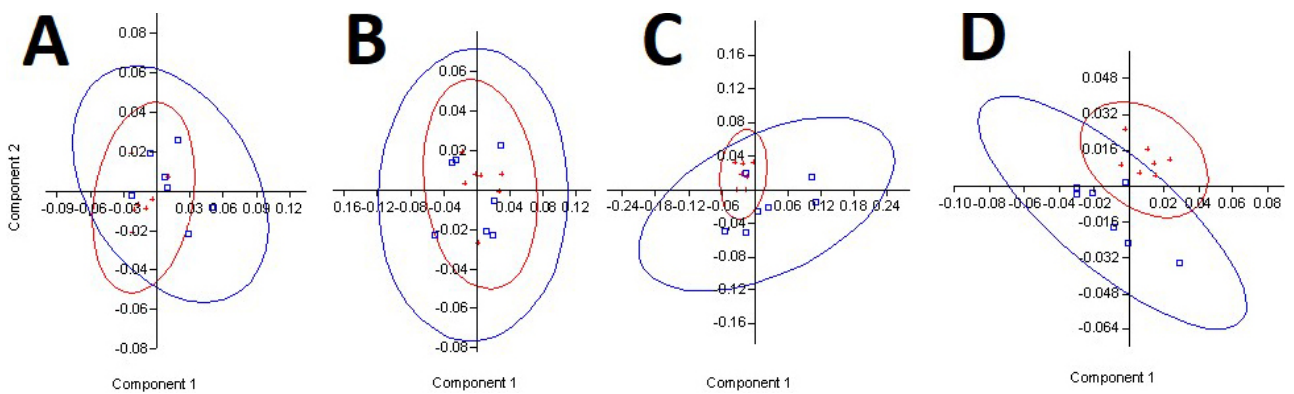


Figure 6. Graphic of 95% confidence analysis. (a) Dorsal; (b) Caudal; (c) Lateral; (d) Ventral. Red line: Female; Blue line: Male.

it was found that the principal points where the differences between the species were revealed were beak length, beak depth, and neurocranium length. In another research done in Magellanic penguin, the maximum variation was determined in the extension of the temporal fossa [16,20].

In the present study, it was observed that the postorbital process was the major principal landmark point which revealed differences between the sexes.

The neurocranial part of the skull is used for species separation as well as for sex determination [21]. In a

Table 2. Sum of squares and mean square values obtained as a result of one-way ANOVA.

Landmarks	Sum of squares	Degrees of freedom	Mean square	F	P
Caudal	6.61886	5	1.32377	1.921E04	1.154E-117
Dorsal	4.78119	10	0.478119	1.123E04	1.939E-200
Lateral	3.83012	4	0.95753	1930	6.212E-66
Ventral	3.10976	8	0.38872	8569	5.755E-157

Table 3. Statistical differences of the landmarks on the coordinate plane for female and male individuals.

Landmark number	Dorsal landmarks		Ventral landmarks		Caudal landmarks		Lateral landmarks	
	f	P value	f	P-value	f	P-value	f	P-value
1	3.3322	0.38428	4.3068	0.013078	6.3347	0.002120	2.2766	0.15113
2	1.4755	0.4928	1.1442	0.81173	1.458	0.50613	1.1447	0.81122
3	1.6705	0.36673	1.2356	0.70852	1.6597	0.37274	4.5179	0.010565
4	1.4445	0.5166	1.3602	0.58711	7.6313	0.000820	1.0789	0.89313
5	1.7468	0.32696	2.1026	0.19364	4.5836	0.009898	3.9182	0.019718
6	1.9114	0.25594	1.0498	0.93157	1.0798	0.89198	-	-
7	2.0737	0.2019	2.9823	0.058998	-	-	-	-
8	1.1936	0.75448	1.8389	0.28494	-	-	-	-
9	1.2488	0.69462	5.1485	0.0057918	-	-	-	-
10	4.4169	0.011691	-	-	-	-	-	-
11	2.3311	0.14004	-	-	-	-	-	-

previous study, the neurocrania of guinea fowl and turkey were compared, and the differences between the 2 species were reported [5]. In another previous study, the neurocranial bones of Dalmatian pelican were examined, together with the facial bones, and the results were reported [22].

As stated before, the neurocranium of poultry is used in taxonomy and sex determination. In addition, data on eating habits and causes of mortality for animals living in the past have been obtained by examining this part of the skull in particular among the bones of these animals [23]. It is considered that the output of the present study and

data for such bones found in excavation areas may be used in sex determination; furthermore, the data may help in determining taxonomy.

By using geometric morphometry, differences among species can also be demonstrated along with the sexual analysis. This method may also be used in age range determination. In addition, after preparing the reference information, it is thought that conditions which involve abnormal skeletal structure may be determined with this method, as well as clarifying morphological variations; this kind of information may be useful in terms of clinical information in the future.

References

1. Nickel R, Schummer A, Seiferle E. Anatomy of the Domestic Birds. 1st ed. Berlin, Germany: Verlag Paul Parey; 1977.
2. Çalışlar T. Evcil Hayvanların Anatomisi. At, tavuk diseksiyonu. 1st ed. İstanbul, Turkey: İstanbul Üniversitesi Veteriner Fakültesi Yayınları; 1986 (in Turkish).
3. Çakır A. Kelaynak kuşunda (*Geronticus eremita*) neurocranium kemikleri. Journal of Turkish Veterinary Medical Association 2001; 72: 35-38 (in Turkish).

4. Süzer B, Serbest A, Arıcan İ, Yonkova P, Yılmaz B. A morphometric study on the skull of the turkeys (*Meleagris gallopavo*). Uludağ University Journal of the Faculty of Veterinary Medicine 2018; 37 (2): 93-100. doi: 10.30782/uluvfd.427228
5. İlgün R, Akbulut Y, Kuru N. Comparative macro-anatomical investigations and morphometric investigations on neurocranium in guinea fowls (*Numida meleagris*) and turkeys (*Meleagris gallapova*). Firat University Veterinary Journal of Health Sciences 2016; 30 (1): 29-32 (in Turkish with an abstract in English).
6. İnce NG, Demircioğlu İ, Yılmaz B, Ağyar A, Dusak A. Three-dimensional modeling of cranium in seagulls (*Laridae spp.*). Harran University Journal of the Faculty of Veterinary Medicine 2018; 7 (1): 98-101 (in Turkish with an abstract in English).
7. O'Higgins P. The study of morphological variation in the hominid fossil record: biology, landmarks and geometry. Journal of Anatomy 2000; 197: 103-120. doi: 10.1046/j.1469-7580.2000.19710103.x
8. Slice DE. Geometric morphometrics. Annual Review of Anthropology 2007; 36: 261-281. doi: 10.1146/annurev.anthro.34.081804.120613
9. Zelditch ML, Swiderski DL, Sheets HD, Fink WL. Geometric Morphometrics for Biologists: A Primer. 1st ed. Waltham, MA, USA: Elsevier; 2004.
10. Bernal V. Size and shape analysis of human molars: comparing traditional and geometric morphometric techniques. HOMO-Journal of Comparative Human Biology 2007; 58 (4): 279-296. doi: 10.1016/j.jchb.2006.11.003
11. Önel A. Comparison of hares (*Lepus europaeus* Pallas, 1778) from Elazığ and Malatya by using geometric morphometrics techniques. PhD, Firat University, Elazığ, Turkey, 2010 (in Turkish).
12. Koyabu D, Werneburg I, Morimoto N, Zollikofer CPE, Forasiepi AM et al. Mammalian skull heterochrony reveals modular evolution and a link between cranial development and brain size. Nature Communications 2014; 3625: 1-9. doi: 10.1038/ncomms4625
13. Parés-Casanova PM, Salamanca-Carreño A, Crosby-Granados R, Carolino N, Leite JV et al. Differentiated postnatal growth of the neurocranium and splanchnocranium in domestic equines. Revista de Investigaciones Veterinarias del Peru 2018; 29 (3): 723-728 (in Spanish with an abstract in English). doi: 10.15381/rivep.v29i3.14835
14. Yalçın H, Kaya MA. Comparative geometrical morphometry on the skull bones of Anatolian wild sheep and Akkaraman sheep. Atatürk University Journal of Veterinary Sciences 2009; 4 (2): 105-116 (in Turkish with an abstract in English).
15. Yalçın H, Kaya MA, Arslan A. Comparative geometrical morphometrics on the mandibles of Anatolian wild sheep (*Ovis gmelini anatolica*) and Akkaraman sheep (*Ovis aries*). Kafkas Üniversitesi Veteriner Fakültesi Dergisi 2010; 16 (1): 55-61. doi: 10.9775/kvfd.2009.385
16. Hospitaleche CA. Variation in the cranial morphometry of the Magellanic penguin (*Spheniscus magellanicus*). Ornitologia Neotropical 2009; 20: 19-26.
17. Wold S, Esbensen K, Geladi P. Principal component analysis. Chemometrics and Intelligent Laboratory Systems 1987; 2 (1-3): 37-52. doi: 10.1016/0169-7439(87)80084-9
18. Cablk ME, Minor TB. Detecting and discriminating impervious cover with high-resolution IKONOS data using principal component analysis and morphological operators. International Journal of Remote Sensing 2003; 24 (23): 4627-4645. doi: 10.1080/01431160310000102539
19. Klingenberg CP. MorphoJ: an integrated software package for geometric morphometrics. Molecular Ecology Resources 2011; 11: 353-357. doi: 10.1111/j.1755-0998.2010.02924.x
20. Degrange FJ, Picasso MB. Geometric morphometrics of the skull of tinamidae (*Aves, Palaeognathae*). Zoology 2010; 113 (6): 334-338. doi: 10.1016/j.zool.2010.07.003
21. Şahiner Y, Yalçın H. Determine the gender from cranial bone by using geometric morphometric method in males and females and ramus flexure. Atatürk University Journal of Veterinary Sciences 2007; 2 (4): 134-142 (in Turkish with an abstract in English).
22. İlgün, R, Özkan ZE, Akbulut Y. Macro-anatomical investigations on neurocranium and splanchnocranium in dalmatian pelican (*Pelecanus crispus*). Van Veterinary Journal 2017; 28 (1): 5-10 (in Turkish with an abstract in English).
23. Tajkova SY, Klochko AV. The bird bones from the excavations of ancient Chersonesos (Crimea, Ukraine). Proceedings of the National Museum of Natural History 2013; 11: 37-42.