

Interfragmental fixation of rostral mandibular fracture with cerclage wire in a thoroughbred English horse*

Mehmet Alper ÇETİNKAYA¹, Alper DEMİRUTKU^{2,**}

¹Medical and Surgical Research Lab., Faculty of Medicine, Hacettepe University, 06100 Sıhhiye, Ankara - TURKEY

²Corresponding author: İstanbul University, Veterinary Faculty, Surgery Department, 34320, Avcılar, İstanbul - TURKEY

Received: 25.02.2011

Abstract: The patient in this study was a 20-year-old thoroughbred gelding. After clinical and radiographical assessments, a bilateral rostral mandibular body fracture was determined. Fracture stabilization was achieved via a bilateral interfragmentary cerclage wire application. The horse started to use its jaw within 24 h of surgery. Postoperative radiographs were taken until month 6, at different periods, and fracture healing was evaluated. Fixation materials were left in place. Fracture healing occurred with a rostral part malocclusion. The purpose of this study was to give clinical information about mandibular fractures and treatment of these fractures in a horse.

Key words: Horse, mandibula fracture, interfragmental fixation, cerclage wire

Safkan bir İngiliz atında rostral mandibula kırığının serklaj teli ile interfragmental fiksasyonu

Özet: Çalışma olgusunu iğdiş edilmiş 20 yaşında bir saf kan İngiliz atı oluşturdu. Klinik ve radyografik muayene sonrasında bilateral rostral corpus mandibula kırığı belirlendi. Kırık fiksasyonu bilateral interfragmental serklaj teli uygulanması ile sağlandı. Operasyondan sonra 24 saat içinde at çenesini kullanmaya başladı. Postoperatif 6. aya kadar farklı aralıklarla röntgenler alındı ve kırığın iyileşmesi değerlendirildi. Fiksasyon materyalleri yerinde bırakıldı. Rostral kısımda maloklüzyon ile birlikte kırık kaynaması şekillendi. Bu çalışmanın amacı bir atta karşılaşılan mandibula kırığı ve sağaltımı hakkında klinik bilgi vermektir.

Anahtar sözcükler: At, mandibula kırığı, interfragmental fiksasyon, serklaj teli

* This study took place at the horse clinic of the Turkish Ground Forces Equestrian Sports Education Center during November 2008.

** E-mail: ademirutku@yahoo.com

Introduction

Mandibular injuries are common in horses and the mandible is the most commonly fractured bone in the head (1-3). Rostral mandibular fractures occur frequently when a horse suddenly pulls the head or tries to escape when incisors or mandibula are affixed to a stationary or fixed object. Mandibular fractures are classified according to fracture localization, soft tissue damage, existence of open fracture, fragmentation, displacement, and instability level, as well as the adjacent tissues involved (teeth, tooth roots, canalis mandibularis, and temporomandibular joint). Fractures occurring in the diastema (area interdentalis) are common and also present as bilateral, transversal, or short oblique fractures (3).

Most mandibular fractures are open fractures and fracture ends are seen in the oral cavity and connect with the microbial flora of the oral mucosa (1,4). In spite of trauma to bones and adjacent soft tissues, mandibular fractures commonly heal well, since local vascularization is perfect if adequate stability is provided. On the other hand, tooth loss, malocclusion, osteomyelitis, sequestration, as well as chronic discharge are the possible complications with a horse suffering from a mandibular fracture (3-7).

The aim of mandibular fracture fixation is to provide the normal occlusion and rapid mandibular

function via the rigid fixation method, to avoid excessive soft tissue damage, and to protect the teeth, tooth roots, and the neurovascular structures in the mandibular canal from fixation materials (1,3,4). Fixation materials should ideally have easy applicability, should not prevent jaw functions, and should not be an injury risk, neither for the horse nor for the attendant. An ideal fixation method is determined according to fracture localization, fracture type, and the surgeon's preference (2-7). Both internal and external fixation methods are successfully used for the treatment of bilateral mandibular body fractures (2,8-10).

Case history

A 20-year-old thoroughbred gelding formed the subject of our case. According to information obtained from the stableman, the horse had bitten the steel bars of its stall's door to open it, and he found the horse with a fractured jaw. A bilateral rostral mandibular body fracture was detected following clinical and radiographical examinations (Figure 1).

In order to obtain sedation, xylazine HCl (0.8 mg/kg, IV) was administered about 5 min after an acepromazin application (0.03 mg/kg IV). Anesthesia via ketamine HCl (2.2 mg/kg, IV) was acquired and ketamine HCl (1.5 mg/kg, IV) was intermittently

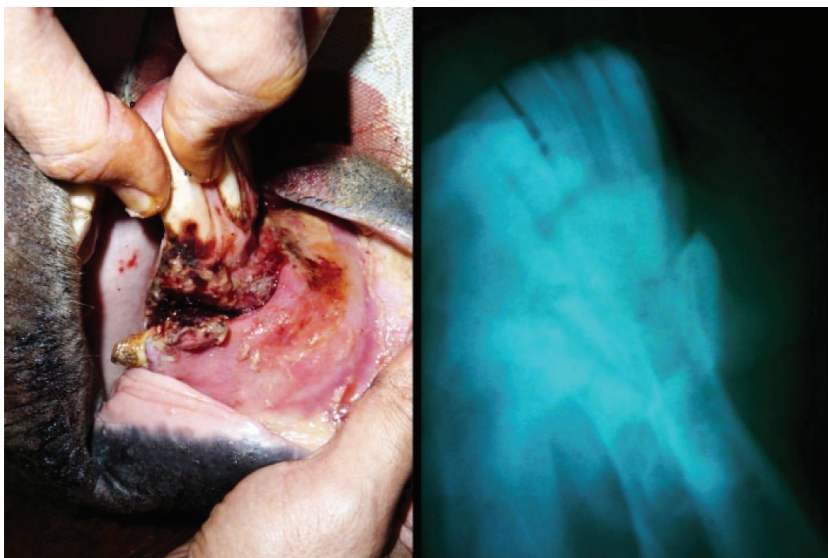


Figure 1. Preoperative clinical and radiographical views of the case.

applied according to the horse's reactions for the constancy and duration of the anesthesia. The left canine tooth (tooth 304), with only a little soft tissue connection was removed. The oral cavity and fractured bone ends were lavaged with sterile saline to remove dirt and saliva and were then prepared for operation by spraying an oral antiseptic (chlorhexidine gluconate 0.2%).

A 1.2-mm drill bit was placed on the bone between tooth 301 and 302, and directed to the rostral sublingual oral mucosa, where it was then introduced to create a first rostral tunnel. The same procedure was repeated on the right side between tooth 401 and 402, to create a second rostral tunnel. With the same size drill bit, 2 caudal tunnels were created on the left and right side of hemimandibles, just distal to the mandibular symphysis (Figure 2).

A bilateral interfragmentary wire fixation was performed to fixate the fracture. On both the left and right sides, 2 pairs of 2-mm cerclage wires were passed through rostral and caudal tunnels. The fractured mandible was held in reduction and the wire ends were twisted on the ventral side of the rostral mandibles, just below the mandibular incisive teeth. Tightening of wires was done while maintaining fracture reduction manually. Required stability on the fracture line was achieved while tooth occlusion was protected. The sharp protruding ends of wire

knots were bent to prevent any soft tissue irritation. Finally, the intraoral soft tissue lesions were sutured to cover the fracture line (Figure 2).

Postoperative radiographies were taken following the operation (Figure 2) and the oral cavity was cleaned once again with saline and an oral antiseptic (chlorhexidine gluconate 0.2%). Trimethoprim-sulfamethoxazole (Primoxal[®], ALKE, Turkey) was administered at 15 mg/kg for 10 days following surgery. In the following days, the residues of food particles found within the lesions in the oral mucosa were digitally removed and the intraoral lesion was cleaned 3 times a day with sterile saline. Oral antiseptic was applied until the soft tissue lesions in the oral mucosa were totally healed. Postoperative radiographies were taken monthly until bone healing was obtained.

Results and discussion

An obvious malocclusion on the rostral side occurred because the fracture line was exposed to mastication forces, due to the horse's unconscious jaw movement during the postoperative awakening period. However, the malocclusion did not affect the jaw closure because the occlusion of the mandible was a normal caudal to the symphysis (Figure 3). It was decided that surgery was necessary to correct the rostral part malocclusion. The horse started to use the jaw functionally within 24 h after the surgery.

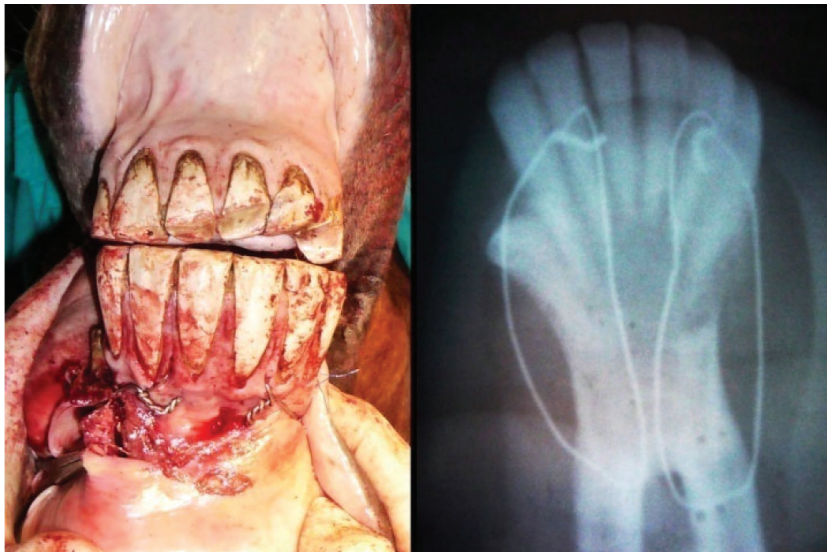


Figure 2. Postoperative clinical and radiographical views of the case following the operation.

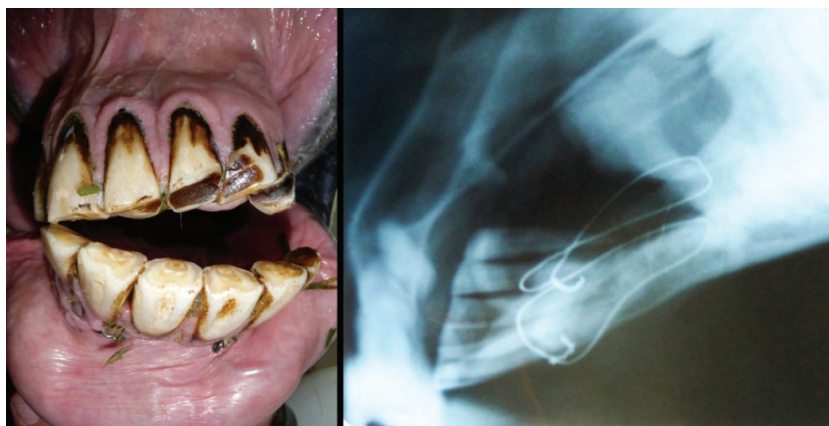

Figure 3. Clinical appearance and radiographical view of the case on the last follow up examination. Fracture healing was determined and rostral malocclusion due to unconscious mastication during the postoperative awakening.

In the postoperative first follow up day, it was observed that some sutures were open or the sutured soft tissue defect was torn and food particles were entrapped in the oral lesion. Because of this, saline lavage was performed 3 times a day within the defects and the food particles were removed. An oral antiseptic was used to prevent possible bone infection. The oral wounds become smaller and then healed within 7 weeks following this application.

No complications occurred related to fracture healing except the rostral malocclusion. Monthly routine radiographs revealed that the fracture was healing (Figure 3). Fixation materials were left in place, as they had become covered by mucosa and had caused no irritation to the adjacent tissues.

The proportion of complications occurring in unstable bilateral maxillary and mandibular fractures in horses were explained as 68% (3,4,6,10). The overall complication rate was 20% for rostral mandibular body fractures stabilized via different types of external skeletal fixator applications (2,7). The complications in this study were ring sequester and chronic drainage, malocclusion was not reported. A possible complication with an external fixator such as entanglement in the external objects, creates hazards for both horses and their handlers (7). Irritation to the base of the tongue and mastication difficulties related to the intraoral splint application were reported (7). Additionally, interdental wire loosening or failure in the same study, were also

reported in 22% of the horses (6). In our study, we did not choose the external skeletal fixator method, to prevent the horse from harming itself its and environment. The technique we used in this study had no such complications, but was not efficient enough to prevent rostral mandibular malocclusion formation due to mastication. Similar complications were reported with these techniques (2,4,6,10). On the other hand, the rostral malocclusion did not prevent jaw closure. The horse started to use his jaw within 24 h and fracture healing occurred in the following weeks.

The horse mandible is exposed to a continuous force during mastication; therefore, biomechanical characteristics of fixation methods are significant for fracture fixation since unstable fractures cause pain and inability to take food, as well as excessive callus formation and esthetic defects. In addition, fixation stability is extremely important since re-fracture is frequently seen in horses (1-4,10). The interfragmental fixation method used in this study did not have enough biomechanic efficiency; therefore, a mandibular rostral malocclusion occurred during mastication movements after surgery. However, this complication did not cause any problems such as pain or food intake reduction. Moreover, the malocclusion occurred in the postoperative awakening period and did not worsen following days, and neither an excessive callus formation nor an esthetic imperfection was observed.

In conclusion, every method of mandibular fracture fixation has its own advantages and disadvantages and the ideal fixation method can differ, generally according to the case or to surgeon

preferences. This technique was preferred because of existing circumstances; however, functional fracture healing was achieved, despite a negligible malocclusion.

References

1. Tremaine, W.H.: Management of equine mandibular injuries. *Equine Vet. Educ.*, 1998; 10: 146-154.
2. Peavey, C.L., Edwards, R.B. 3rd, Escarcega, A.J., Vanderby, R. Jr., Markel, M.D.: Fixation technique influences the monotonic properties of equine mandibular fracture constructs. *Vet. Surg.*, 2003; 32: 350-358.
3. DeBowes, R.M.: Fractures of the mandible and maxilla. In: Nixon, A.J., Ed.: *Equine fracture repair*. Philadelphia, PA, Saunders, 1996; 323-335.
4. Beard, W.: The skull, maxilla, and mandible. In: Auer, J.A., Stick, J.A., Eds: *Equine Surgery 2nd Edition*. Philadelphia, PA, Saunders, 1999; 887-899.
5. Little, C.B., Hilbert, B.J., McGill, C.A.: A retrospective study of head fractures in 21 horses. *Aust. Vet. J.*, 1985; 62: 89-91.
6. Henninger, R.W., Beard, W.L., Schneider, R.K., Bramlage, L.G., Burghardt, H.A.: Fractures of the rostral portion of the mandible and maxilla in horses: 89 cases (1979-1997). *J. Am. Vet. Med. Assoc.*, 1999; 214: 1648-1652.
7. Belsito, K.A., Fischer, A.T.: External skeletal fixation in the management of equine mandibular fractures: 16 cases (1988-1998). *Equine Vet. J.*, 2001; 33: 176-183.
8. Colahan, P.T., Pascoe, J.R.: Stabilization of equine and bovine mandibular and maxillary fractures, using an acrylic splint. *J. Am. Vet. Med. Assoc.*, 1983; 182: 1117-1119.
9. Dart, A.J., Pascoe, J.R.: Treatment of a bilateral mandibular fracture in a mare using an intraoral acrylic splint. *Aust. Vet. J.*, 1987; 64: 382-384.
10. Ragle, C.A.: Head trauma. *Vet. Clin. North Am. Equine. Pract.*, 1993; 9:171-183.