

Blood Parasites of Wild Pigeons in Ankara District

Yunus GİCİK, M. Özkan ARSLAN

Department of Parasitology, Faculty of Veterinary Medicine, Kafkas University, Kars - TURKEY

Received: 05.11.1999

Abstract : A total of 200 wild pigeons, 82 young and 118 adults, captured from 12 localities in Ankara District, were examined for blood parasites. *Haemoproteus columbae* was found in 57% (114/200) of the pigeons examined, and no other blood parasites were detected.

Key Words: Ankara, Blood parasites, Pigeon

Ankara Bölgesinde Yaban Güvercinlerde Kan Parazitleri

Özet : Ankara ve çevresinde 12 merkezden 82 genç, 118 erişkin olmak üzere toplam 200 yaban güvercini kan parazitleri yönünden incelenmiştir. Bunların 114 ü (%57) *Haemoproteus columbae* ile enfekte bulunmuş olup, başka herhangi bir kan parazitine rastlanmamıştır.

Anahtar Sözcükler: Ankara, Kan parazitleri, Güvercin

Introduction

Wild pigeons are present in every part of the world, except for the polar regions (1). Three species of wild pigeons, *Columba livia*, *C. oenas* and *C. palumbus*, are reported to inhabit various geographic regions of Turkey (2-4).

Pigeons are in close contact with domestic fowl. It is well documented that blood parasites of fowl, whether domestic or not, are not host specific. Therefore, pigeons can be reservoirs for a number of parasitic infections and may transmit blood parasites to domestic fowl (5,6).

The frequencies of *Plasmodium*, *Haemoproteus* and *Leucocytozoon* parasites are considerably high in domestic and wild birds. These parasites can cause considerably high mortality in wild poultry species (6-10). The effect of *Haemoproteus spp.* on migrating wild birds has been studied and the results show that birds infected with *Haemoproteus spp.* cannot accumulate enough fat needed for energy, and that the level of RNA, protein and glucogen in the brain, heart and liver are decreased in infected birds and glucose consumption by infected erythrocytes is 100 times higher than by non-infected

erythrocytes. Therefore, the mortality rate is reported to increase as much as 40% in infected birds (6,7,11,12).

Studies, to date, have determined that the most common blood parasite found in pigeons is *Haemoproteus columbae* and the infection rate may be as high as 75% ranging from 6 to 86% (5,7,8,10,13,14). In addition, *H. sacharovi*, *Leucocytozoon marchouxi*, *Trypanosoma avium*, *T. columbae* and *T. hanna* are occasionally isolated from pigeons (6,9,10,14,15).

Haemoproteus columbae and *H. sacharovi*, distributed world wide, are also present in chickens and doves; *Leucocytozoon marchouxi* is also seen in doves and chickens and *Trypanosoma avium* is common in various birds including geese (6,15,16).

There is a very limited number of studies on blood parasites of pigeons in Turkey. Mimioğlu et al. (15) reported that *H. columbae* is present in high proportions in pigeons in Ankara. Tolgay (6) examined 98 blood samples collected from pigeons from a local zoo and found that 74% (73/98) of the pigeons were infected with blood parasites.

The aim of this study was to determine the frequency of blood parasites in wild pigeons in Ankara District.

Materials and Methods

This study was carried out between September, 1996, and September, 1997, involving 200 pigeons, 82 young and 118 adults, from Ankara and vicinity.

The pigeons were caught from 12 localities and brought to the Helminthology Laboratory of the Veterinary Faculty, Ankara University. The places and the dates of capture were recorded and blood smears were prepared from each pigeon after sacrifice.

The ages and sexes of the pigeons were determined by necropsy. It is generally accepted that the complete development of the left ovary in females and testicles in males is achieved at the end of the fourth month of life (3,4,17,18). Therefore, the pigeons under 4 months were considered young and above 4 months were considered adult, (Table 1).

Blood smears were air dried and fixed by methyl alcohol and stained with 5% giemsa stain and examined by immersion. Gametocytes of *Haemoproteus columbae* were photographed.

Results

Of the 200 birds, 114 were found to be infected with *Haemoproteus columbae* and many were infested with *Pseudolynchia canariensis*, which are vectors for *H. columbae*. On stained blood smears only gametocytes of *H. columbae* were seen within red blood cells (Figures 1, 2).

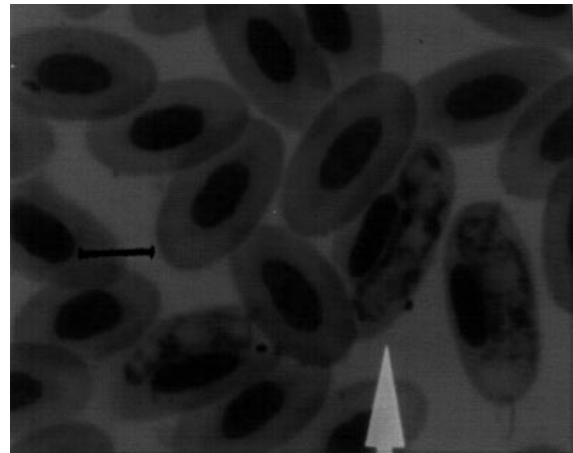


Figure 1. Gametocytes of *Haemoproteus columbae* in erythrocytes. Bar=5 µm

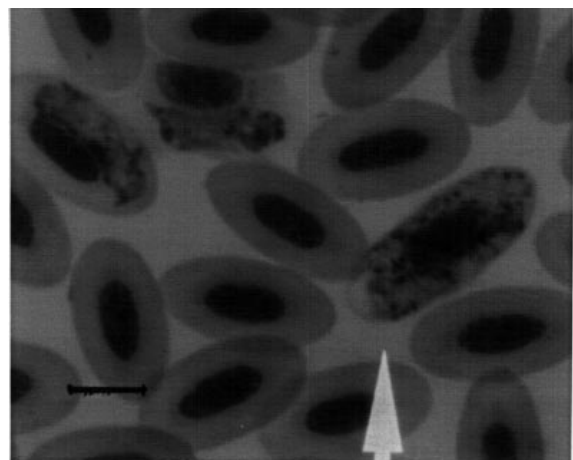


Figure 2. Two *Haemoproteus columbae* gametocytes in one erythrocyte. Bar=5 µm

Locality	Number of pigeons	Age		Sex	
		Young	Adult	Female	Male
Altındağ	58	25	33	19	39
Bağlum	9	5	4	2	7
Bakanlıklar	6	2	4	4	2
Çamlidere	11	5	6	1	10
Çankaya	3	2	1	2	1
Çubuk	10	2	8	7	3
Gölbaşı	13	4	9	8	5
Keçiören	25	12	13	13	12
Mamak	6	1	5	5	1
Polatlı	32	13	19	18	14
Sincan	13	4	9	4	9
Yenimahalle	14	7	7	5	9
Total	200	82	118	88	112

Table 1. The locality, number, age and sex of pigeons examined.

Table 2. Infection rates according to age.

Ages	Examined pigeons	Infected pigeons	
	Number	Number	%
Adult	118	75	63.5
Young	82	39	47.5
Total	200	114	57

Table 3. Infection rates according to sex.

Sex	Examined pigeons	Infected pigeons	
	Number	Number	%
Female	88	55	62.5
Male	112	59	52.6
Total	200	114	57

Table 4. Infection rates according to locality.

Localities	Examined pigeons	Infected pigeons	
	Number	Number	%
Altındağ	58	48	82.7
Bağlum	9	5	55.5
Bakanlıklar	6	4	66.6
Çamlidere	11	2	18.1
Çankaya	3	-	-
Çubuk	10	8	80
Gölbaşı	13	9	69.2
Keçiören	25	5	20
Mamak	6	2	33.3
Polatlı	32	24	75
Sincan	13	7	53.8
Yenimahalle	14	-	-
Total	200	114	57

Infected erythrocytes were counted in a microscopic area on all positive blood smears. Of the 114 positive blood smears, on 33.3% (38/114) 1-2 erythrocytes, on 46.4% (53/114) 3-5 erythrocytes and on 20.1% (23/114) more than 5 erythrocytes were observed to be infected with gametocytes of *H. columbae*. Generally one and rarely two gametocytes were seen in infected red blood cells.

References

1. Tiğın, Y.: Ehli güvercinlerde (*Columba livia*) bulunan ektoparazitler. Ankara Üniv. Vet. Fak. Derg., 1973; 20: 372-390.
2. Akçakaya, R., Barış, S., Orer, H., Bilgin, C.: Kuşları Tanıyalım. 2. Baskı. İstanbul: Ana Basım A.Ş. 1995.

When the infection rate was reassessed according to age (young-adult) and sex, it varied from 47.5% (39/82) in young pigeons to 63.5% (75/118) in adults (Table 2). It was 62.5% (55/88) in females and 52.6% (59/112) in males (Table 3).

In addition, infection rates were also calculated according to the localities where the pigeons were obtained. The highest infection rate were observed in pigeons from Altındağ (82.7%, 48/58) and Çubuk (80%, 8/10), but no infection was encountered in Çankaya and Yenimahalle (Table 4).

Discussion

In world wide studies including Turkey, *Haemoproteus columbae* was the most common blood parasite in pigeons. *H. sacharovi*, *Leucocytozoon marchouxi*, *Trypanosoma avium* and *T. hanna* were less commonly observed (5-7,10,14,15,19).

Infection rates with blood parasites varied between 6 and 8%, and were more common in adult than young birds. The highest infection rates were observed in autumn and winter months (10,19,20).

In infected erythrocytes, generally one and rarely two gametocytes were seen and the infections were mild. No important clinical signs were reported in infected animals (6,10,21).

In this study, of the 200 wild pigeons which were obtained from Ankara and vicinity, 114 (57%) were positive for *H. columbae*. While the infection rate was 47.5% in young pigeons, it was 63.5% in adult pigeons. Generally one and rarely two gametocytes were seen in infected red blood cells. The infected erythrocyte count within a microscopic area was determined to be 1-2 in 38 (33.3%), 3-5 in 53 (46%) and more than five in 23 (20.2%) of the 114 infected slides.

The pigeons examined in this study were found to be free of other parasites and no clinical disorders were determined before sacrificing.

3. Demirsoy, A.: Genel ve Türkiye Zoocoğrafyası (Hayvan Coğrafyası). Ankara: Meteksan yayını. 1996.
4. Kızıroğlu, İ.: Türkiye Kuşları. Ankara: Orman Gnl. Müd. Yayını. 1989.
5. Qureshi, M.I., Sheikh, A.H.: Studies on blood protozoan parasites of poultry in Lahore District. Pakistan J. Sci., 1978; 30: 165-167. (Ref: Proto. Abst., 2411,1980).
6. Tolgay, N.: Çeşitli kanatlıların Plasmodium, Haemoproteus ve Leucocytozoon enfeksiyonları üzerinde araştırmalar. Ankara Üniv. Vet. Fak. Derg., 1972; 19: 271-286.
7. Aguirre, A., Mena, A., Barnett, L.: Epizootiological considerations of Haemoproteus infections of pigeons. Rev. Aviculture, 1986; 30: 275-281. (Ref: Proto. Abst., 950,1987).
8. Mandour, A.M., Abdel Rhamn, A.M., Abdel Salem, F.A.: Atoxoplasma (Lankesterella) columbae sp. nov. in the domestic pigeon Columba livia in Assiut Province (with one figure). Assiut Vet. Med. J., 1986; 17: 95-97. (Ref: Poultry Abst., 1004, 1987).
9. Mimioğlu, M., Göksu, K., Sayın, F.: Veteriner ve Tibbi Protozooloji I. Ankara: Ankara Üniv. Basımevi. 1968.
10. Stabler, R.M., Kitzmiller, N.J., Braun, C.E.: Blood parasites from band-tailed pigeons. J. Wildlife Manag., 1977; 41: 128-130. (Ref: Proto. Abst., 4053,1977).
11. Reddy, C., Damayanthi., Rao, S., Rao, B.: Host response to Haemoproteus columbae. Rev. Parassitol., 1980; 41: 191-193. (Ref: Proto. Abst., 4342,1981).
12. Valkiūnas, G.: Pathogenic influence of haemosporidans and trypanosomes on wild birds in the field conditions: facts and hypotheses. Ekologija (Lithuania), 1993; 1: 47-60.
13. Kaminjolo, J.S., Tikasingh, E.S., Ferdinand, G.A.A.: Parasites of the common pigeon (Columba livia) from the environs of port of Spain, Trinidad. Bull. Anim. Hlth. Prod. Afri., 1988; 36: 194-195.
14. Subbiah, T.V., Joseph, S.A.: A note on the occurrence of Trypanosoma hance in the blood of the domestic pigeon, Columba livia. Cheiron, 1988; 17: 136. (Ref: Vet. Bull., 2756,1987).
15. Mimioğlu, M., Göksu, K., Sayın, F.: Veteriner ve Tibbi Protozooloji II. Ankara: Ankara Üniv. Basımevi. 1969.
16. Soulsby, E.J.L.: Helminths, Arthropods and Protozoa of Domesticated Animals. 7th Edition. London: Bailliere Tindall. 1986.
17. Nickel, R., Schummer, A., Seiferle, E.: Anatomy of the Domestic Birds. Berlin: Verlag Paul Parey. 1977.
18. Wages, D.P.: Diseases of pigeons. Small Anim. Pract., 1987; 17:1089-1107.
19. Klei, T.R., Degiusti, D.L.: Seasonal occurrence of Haemoproteus columbae Kruse and its vector Pseudolynchia canariensis Bequaert. J. Wildlife Dis., 1975; 11: 130-135. (Ref: Rev. Appl. Entomo., 588,1976).
20. El Magd, M.M.A., El Badri, A.A., Salim, M.K.: Observation on pigeon blood parasites at Qena province. Assiut Vet. Med. J., 1988; 20: 199-202. (Ref: Proto. Abst., 1291,1989).
21. Ahmed, F.E., Mohammed, A.H.H.: Studies of growth and development of gametocytes in Haemoproteus columbae Kruse. J. Proto., 1978; 25: 174-177. (Ref: Proto. Abst., 940,1979).