

Enver ALTAŞ¹
Erhan VAROĞLU²
Necdet ÜNÜVAR³
Pınar POLAT⁴
İbrahim İYİĞÜN⁵
Zekai ERMAN⁶
Mustafa YILDIRIM²

Endocrine hypofunction in the McCune-Albright syndrome

Departments of ¹Otorhinolaryngology, ²Nuclear Medicine, ³Endocrinology, ⁴Radiology, ⁵Neurology, ⁶Pathology, School of Medicine, Atatürk University, Erzurum-Turkey

Received: May 1, 1998

Key Words: Endocrine hypofunction, polyostotic fibrous dysplasia, McCune-Albright syndrome

Recognition of fibrous dysplasia as a specific disease entity began with a report of osteodystrophia fibrosa in a young female exhibiting cafe-au-lait pigmentation and precocious puberty. This syndrome, identified by Albright et al. (1), it is now referred to as MAS.

Fibrous dysplasia may be monostotic (affecting a single bone) or polyostotic (affecting many bones) and is usually asymmetrical and often unilateral. The rib, femur, tibia, and maxilla are most commonly involved. Craniofacial involvement occurs in all of the severe polyostotic forms, but only in about 30 per cent of the monostotic forms (2). The aetiology of fibrous dysplasia is not clear, and several theories exist, including those of hormonal imbalance (1) and a mutant gene (G protein alfa subunit) whose protein product affects bone (3). In this case report, we discuss an interesting case with endocrine hypofunction and polyostotic fibrous dysplasia in light of the literature.

This study involves a 31-year-old female with a 4-year history of painless swelling on the left side of the face, causing slight disfigurement, and spontaneous luxations of her teeth on the upper left side of the jaw and with a 27-year history of cafe-au-lait spots on the back and precocious puberty. The swelling present over the left anterolateral wall of the maxilla caused obliteration of the gingivo-buccal sulcus and left side of the hard palate. No neurological deficit was determined. She was 134 cm in height and weighed 45 kg.

Basal hormone tests indicate decreased serum concentration of TSH, FT3, FT4, ACTH, and cortisol

(TSH: 0.3 µU/mL; FT3: 1.4 pg/mL; FT4: 0.4 µg/mL; ACTH: 3.2 pg/mL; cortisol: <1.0 µg/dL). In addition, there was no response of TSH to stimulation with TRH (400 µg iv), the responses of FSH and LH to stimulation with LHRH (100 µg iv) were normal, and the response of ACTH to stimulation with CRF (100 µg iv) was inadequate. The stimulation with exercise test performed on our case showed that basal hormone concentrations were in the normal range and GH responded normally. Although serum concentrations of calcium, phosphate, and PTH were within normal limits, serum concentration of alkaline phosphatase was high.

Radiological examinations, especially plain radiograms, revealed a thick and foreshortened femoral neck, known Shepherd's crook deformity, was detected. Furthermore, the diaphyses ground glass appearance and dense medullary sclerosis. Spin-echo T1 weighted MR images revealed expanding lesions filling all of the left maxillary sinus, and a hypointense expanding lesion in the parietal bone and computed tomography smoky appearance at some localization on computed tomography was also detected. Anterior and posterior whole-body bone scintigraphy was performed with Tc-99m MDP (technetium-99m methylene diphosphonate). The whole-body scan was a helpful technique for identifying polyostotic involvement in this patient. Anterior and posterior body images showed increased Tc-99m MDP accumulation on the bilateral maxillar bones and left orbital roof, and inhomogenous uptake on the humeri, femurs, tibias and on tarsal bones symmetrically, and the right ribs (Figure 1).

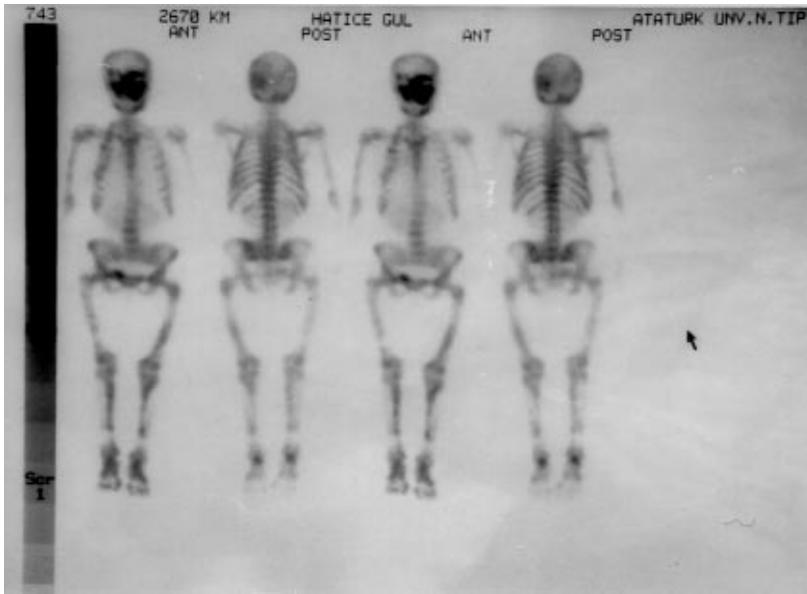


Figure 1. Anterior and posterior body images show increased Tc-99m MDP accumulation on the bilateral maxillar bones and left orbital roof, and inhomogenous uptake symmetrically on the humeri, femurs, tibiae and tarsal bones and unilaterally on the right ribs, and left mandible.

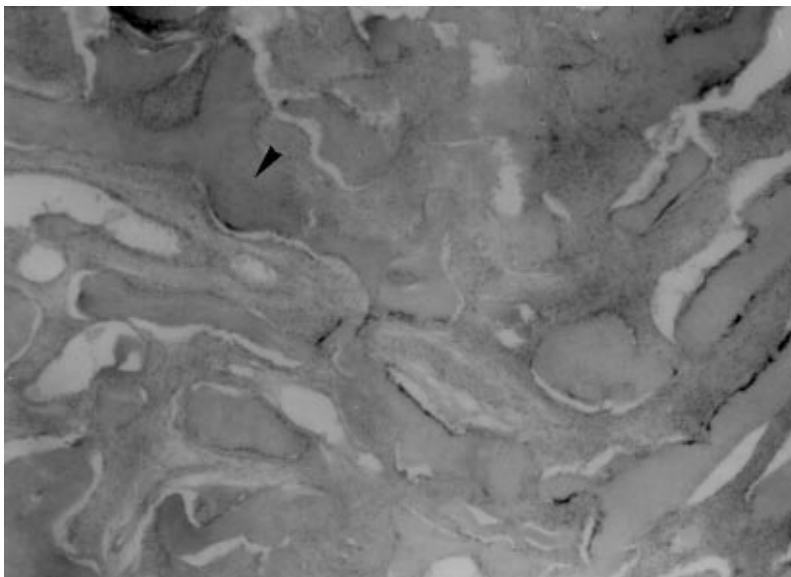


Figure 2. Histological appearance: The connective tissue becomes from less cellular and fibres tend to arrange themselves in whorls. The bony trabeculae become thicker and lamination (Arrow head) (H & E; X 40).

The incisional biopsy of the bone mass in the left maxillary sinus was carried out through a gingivo-buccal sulcus incision. In gross view, the biopsy material was hard and reddish. The histology of biopsy material revealed as fibrous dysplasia and light microscopic examination showed loosely textured, highly cellular and vascular connective tissue in which there were spicules of woven (coarse-fibred) bone, characteristically curved or sickle-shaped (Figure 2). Thus, it was determined that our case was in an active phase.

No treatment for bone lesions was offered to this patient, because she had no orbital complications, was not worried about her facial deformity, and had excessive

bleeding during biopsy and active phase. Also, for the endocrine hypofunction, our case was given hydrocortisone (30 mg/day, per orally) and L-thyroxin therapy (100 µg/day, orally). Outpatient visits were scheduled every 3 months.

Endocrine hyperfunctions accompanying MAS have been reported as pituitary adenomas secreting GH and/ or PRL (4), autonomous adrenal hyperplasia (5), hypophosphatemic osteomalacia (6), goiter leading to thyroid hormone excess (primary hyperthyroidism) (7) and precocious puberty and endocrine hypofunctions accompanying MAS were not found in the literature review.

However, secondary adrenocortical deficiency and secondary hypothyroidism in our case were confirmed with basal hormone concentrations and dynamic tests. We performed a number of tests to establish aetiologies of these diagnosis, but no pathologic condition causing the secondary deficiency was found, nor did she have a history of any such condition.

Three types of fibrous dysplasia can be distinguished. Early (acute stage) lesions have richly cellular connective tissue, often with mitotic figures and woven immature bone. Giant cells are seen. Normal osseous trabeculae are rare. The connective tissue in the subacute stage becomes less cellular, and fibres tend to be arranged in whorls. The bony trabeculae become thicker and lamination occurs. In the chronic stage, bony trabeculae occur in abundance. The osseous trabeculae show lamination, with a rim of osteoblasts (8). The gross appearance of the lesion varies in consistency and vascularity: early lesions are soft and reddish, because of rich vascularization; old lesions are hard, sclerotic, and white in colour (9). The microscopical

and gross views of our case were in accordance with the subacute stage of fibrous dysplasia. Therefore, the case was frequently evaluated for an understanding of its progress.

Fibrous dysplasia should be differentiated from osteoclastoma, non-Hodgkin's lymphoma, dentigerous cyst, dental cyst, adamantinoma, mucocele, malignant tumors of the maxillary sinus, osteitis fibrosa cystica, and meningioma (10).

The treatment is essentially surgical in symptomatic cases and depends upon the extent of the lesion, varying from simple shaving of the bone to more extensive surgery. Occasionally, the bleeding during surgery can be excessive. If surgery is necessary during the active phase, bleeding can be profuse and regrowth can occur quite quickly (10). However, profuse bleeding was also seen in our case during incisional biopsy. Therefore, our data show that she is in active phase and surgical treatment may not be necessary. We performed hormonal

References

1. Albright F, Butler A, Hampton AO. Syndrome characterized by osteitis fibrosa disseminata, areas of pigmentation, endocrine dysfunction with precocious puberty in females. *New England J of Medicine* 216:727-46, 1937.
2. Fries JW. The roentgen features of fibrous dysplasia of the skull and facial bones: a critical analysis of 39 pathologically proved cases. *Am J of Roentgenol* 77:71-88, 1957.
3. Riminucci M, Fisher LW, Shenker A, Spiegel AM, Bianco P, Gehron Robey P. Fibrous dysplasia of bone in the McCune-Albright syndrome: abnormalities in bone formation. *Am J Pathol* 151(6):1587-600, 1997.
4. Cuttler L, Jackson JA, Saeed uz-Zafar M, Levitsky LL, Mellinger RC, Frohmann LA. Hypersecretion of growth hormone and prolactin in McCune-Albright syndrome. *J Clin Endocrinol Metab* 68:1148-54, 1989.
5. Danon M, Robboy SJ, Kim S, Scully R, Crawford JD. Cushing syndrome, sexual precocity, and polyostotic fibrous dysplasia (Albright syndrome) in infancy. *J Pediatr* 87:917-21, 1975.
6. Lee PA, Van Dop C, Migeon CJ. McCune-Albright syndrome: longterm follow up. *JAMA* 256: 2980-84, 1986.
7. Feuillan PP, Shawker T, Rose SR, Jones J, Jeevanram RK, Nisula BC. Thyroid abnormalities in the McCune-Albright syndrome: ultrasonography and hormonal studies. *J Clin Endocrinol Metab* 71:1596-1601, 1990.
8. Dahlgren SE, Lind PO, Lindbom A, Martensson G. Fibrous dysplasia-A clinical and histopathological study. *Acta Otolaryngol* 68:257-61, 1969.
9. Gross CW, Montgomery WW. Fibrous dysplasia and malignant degeneration. *Arch of Otolaryngol* 85:653-657, 1967.
10. Bahadur S, Shoney AM, Singh MK. Fibro-osseous lesions of the maxilla. *The J of Laryngol and Otol* 100:653-657.