

İlginç YORULMAZ¹
Recep SAVAŞ²
Kutsi KÖSEOĞLU²
Işıl GÜNHAN²
R.Nuri ŞENER²

Contralateral Claustral Hemorrhage Due to a Glial Tumor

¹Department of Radiology, Medical Faculty,
Celal Bayar University, Manisa-Turkey
²Department of Radiology, Medical Faculty,
Ege University, Bornova, Izmir-Turkey

Received: August 7, 1995

The present patient is a 47-year-old man who presented with signs and symptoms of increased intracranial pressure. A cranial CT study performed revealed a glial tumor in the left hemisphere. A cranial MR study was requested by the Surgical Neurology department to further evaluate the extension of the tumor. This showed a large supratentorial mass in left hemisphere with marked enhancement following administration of Gadopentetate dimeglumine, consistent with a glial tumor (Fig. 1A). Apparent shift of the midline structures was noted in this examination. Of particular interest was the pathologic signal intensity pattern of the contralateral caudate. The caudate gave low signal on all sequences (more on T2-weighting), suggesting the presence of hemosiderin, a chronic blood degradation product (Figs. 1 B,C). This signal intensity pattern of chronic hemorrhage suggested a hemorrhagic infarct located exclusively in the caudate, probably due to compression of the small end-arteries supplying this region, secondary to the shift of the midline structures.

The caudate is a thin sheet of gray matter between the insula and putamen. It is separated from the putamen by the external capsule and from the insula by the extreme capsule. It is regarded by some as belonging to the corpus striatum. Animal studies suggest that the caudate has corticocaudate and caudatecortical connections with many regions of the neocortex. In the human brain, however, the connections and the functional significance of the caudate are unknown (1,2). The caudate is supplied by the carotid system by medullary arteries, which are branches of the insular pial arteries of the middle cerebral artery. These are usually end-arteries (3).

A recent report by Şener on the appearance of the normal caudate on MRI as well as its brightness on T2-weighted MRI images in Wilson's disease has drawn attention to this parenchymal structure which can be sufficiently demonstrated only by MRI (4). This was followed by an article on seven patients with caudate pathologies by the same author (5) which further dealt with abnormalities seen in metabolic disorders such as Wilson's disease and cytoplasmically inherited striatal degeneration. Two patients in that series had bilateral caudate infarctions; one being due to meningitis and the

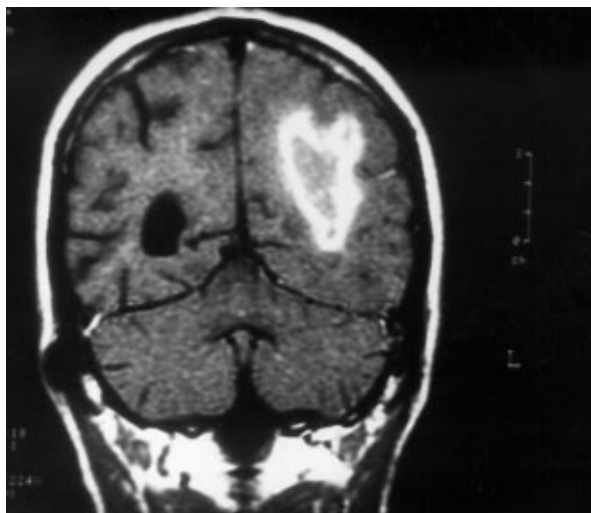


Figure 1. A. Coronal T1-weighted image obtained after paramagnetic contrast medium injection shows a large, intraaxial tumor in the left hemisphere.

other due to hypoxia during general anesthesia. The mechanism for the infarctions was thought to be due to arteriopathic changes of the small end-arteries supplying the claustrum. In all the patients, accompanying lesions were evident in the brain and no definitive clinical signs and symptoms were noted that were attributable exclusively to the claustrum. The reason for this was discussed to be the fact that the accompanying major lesions dominated the clinical presentation.

In the light of the presented data, this case is a further example of a chronic claustral hemorrhagic infarction

in a patient with a contralateral brain tumor. The infarction is of hemorrhagic type exclusively in the claustrum, probably due to compression of the small end-arteries supplying this region. This can be secondary to the shift of the midline structures, or an isolated condition may be considered. There was not any clinical manifestation of the claustral pathology in this patient, possibly due to the fact that major symptoms caused by the accompanying glial tumor in the contralateral hemisphere dominated the clinical picture.

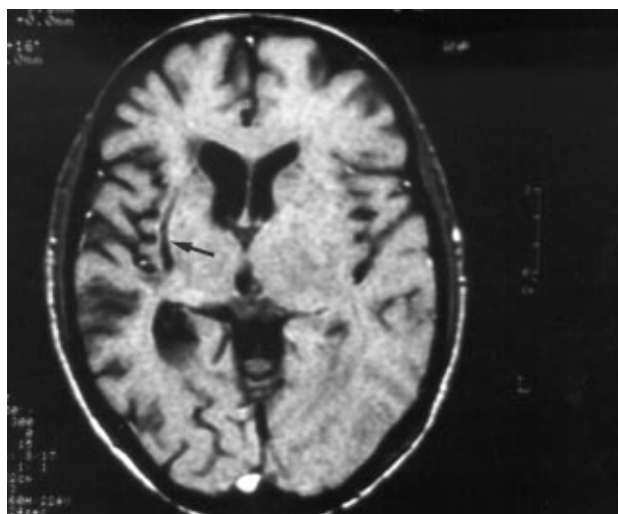


Figure 2. B. Axial T1-weighted image shows that the right claustrum is hypointense (arrow)

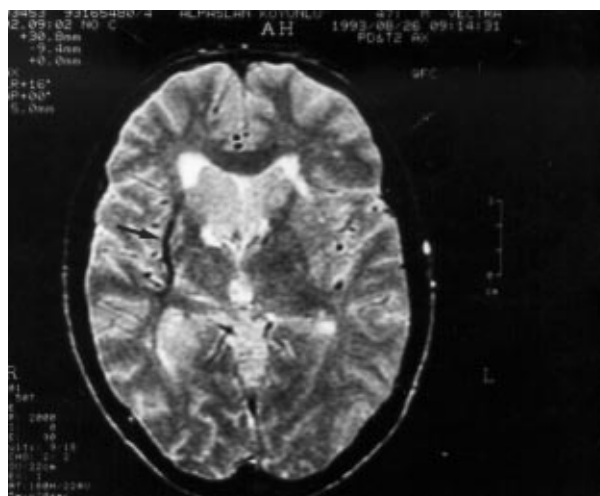


Figure 3. C. Axial T2-weighted image shows the right claustrum to give low signal (arrow), suggesting chronic hemorrhage. Note that the lesion is confined to the region of claustrum. It does not extend anteriorly or posteriorly, excluding the possibility of involvement of the nearby structures (i.e. external and extreme capsules.)

References

1. Williams PL, Warwick R, Dyson M, Bannister LH: Gray's Anatomy, 37th edn. Churchill Livingstone. Edinburgh 1989, pp.748, 1034,1080.
2. Barkovich AJ. Pediatric Neuroimaging. Raven Press. New York 1990, p.48.
3. Takahashi S, Goto K, Fukasawa H, Kawata Y, Uemura K, Suzuki K, Computed tomography of cerebral infarction along the distribution of the basal perforating arteries. Part I: Striate arterial group. Radiology 155: 107-18, 1985.
4. Şener RN. The claustrum on MRI: normal anatomy, and the bright claustrum as a new sign in Wilson's disease. Pediatr Radiol 23: 594-6, 1993.
5. Şener RN. Abnormalities of the claustrum. Neuroradiology (suppl) 37: 284-6, 1995.