

Ahmet ERSAY¹
Şükrü BOYLU²
Hayrettin ŞAHİN¹
Nedim ABAN²
Yılmaz AKGÜN²
İbrahim TAÇYILDIZ²

Comparison of two Catheterizable Continence Mechanisms for Urinary Diversion

Received: January 27, 1997

Departments of ¹Urology, ²General Surgery,
Faculty of Medicine, Dicle University,
Diyarbakır-Turkey

Abstract: Benckekroun hydraulic ileal valve and hipple valve techniques are widely used continent valve systems in reconstructive urology. We compared continence, catheterizability and complications of the nipple and Benckekroun hydraulic ileal valve ruling out the inherent error of comparing different reservoirs under different conditions. A pouch was constructed with two methods present side by side. Comparable data from each valve were statistically evaluated through Mann-Whitney U test. Although the rate of complications such as dessusception and difficult catheterization for each valve are close, leakage of the Benckekroun hydraulic ileal valve was observed at significantly high-

er pouch volumes than in the nipple valve (337.1±105.4 cc vs. 213.558.9 cc). Maximal leak point pressures were not different statistically for both valves, when the pouch filled to the capacity and its half (75.9±35.0 vs 48.4±20.5 and 64.8±28.0 vs 47.3±20.2 respectively). In the light of this result Benckekroun hydraulic ileal valve seems to be superior to the nipple valve at higher pouch volumes.

Key Words: Benckekroun hydraulic ileal valve, nipple valve, continence.

Introduction

Urinary diversion has become a common procedure in urology. Benckekroun hydraulic ileal valve [2,3] and nipple valve techniques of Kock and Skinner [11,23] are the widely used continent valve systems in reconstructive urology.

Our intention in this study was to create an experimental canine model in order to compare continence, complications and catheterizability of a simple nipple valve with hydraulic valve described by Benckekroun.

Material and Method

This study was approved by Laboratory of Animal Science Committee of Dicle University, Medical Science Research Center. Ten male mongrel dogs each weighing 16-19 kg were used for experimental series. A colonic pouch with two different valve mechanisms was created under general anesthesia. A midline incision was performed and bowel was exposed. The entire ascending colon and approximately 1/3 transverse colon together 24 cm (10+12 cm) terminal ileum were isolated. Bowel continuity was restored by end-to-end

ileocolic anastomosis. The detached colon was debulbarized along its antimesenteric surface. Ten and twelve cm of ileum segments were separated from the detached bowel, one of which was prepared for a nipple valve and the other for a Benckekroun hydraulic valve (Fig. 1a). Intussuscepted nipple valve technique; a 2.5-3 cm mesenteric window was opened beneath the portion of the bowel to be intussuscepted in order to create 5 cm of the nipple valve. Valve was secured by placing quadrant sutures (3/0 vicryl) at the base of the valve and two longitudinal continuous sutures. Benckekroun hydraulic valve techniques; Two babcock clamps were passed through the lumen of the 10 cm isolated ileal segment, in an antiperistaltic direction. The cut edge of the oral end of the ileum is grasped by clamp and pulled through the ileal lumen in a peristaltic direction, invaginating the ileum. This invagination is fixed by semicircumferential row of absorbable sutures (3/0 vicryl) incorporating full thickness oral and aboral ends of the ileal segment, and on the opposed side of the fixation one horizontal mattress suture is placed. Both valve mechanisms (two efferent limbs) were anastomosed on both side of the

	Benchekroun hyd.	Nipple valve
Successful catheterization(n)	694/664	615/587
Mean leak point pressure (cm water)	75.9±35.0	48.4±20.5
Mean leak point volume (cc)	337.1±105.0	213.5±58.9
Mean leak point pressure (cm water)*	64.8±28.0	47.3±20.2
Valve dessusception (n)	-	1
Stomal complication (n)	1	2

Table 1. Comparison of operative and urodynamic results between the two techniques

*The measurement was carried out at 1/2 max. pouch vol. by manual compression.

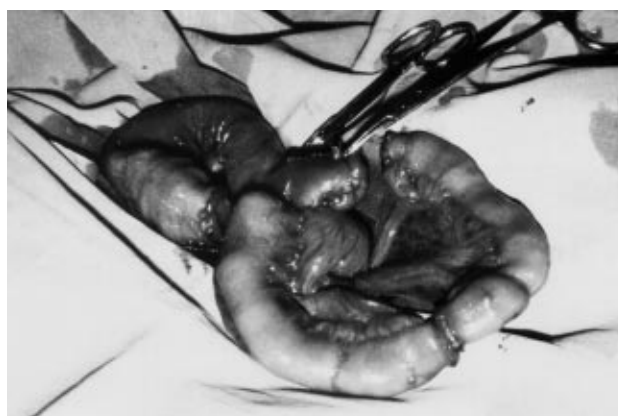

Figure 1. (a) Segments of colon and ileum used for creation of pouch and its two outlets.

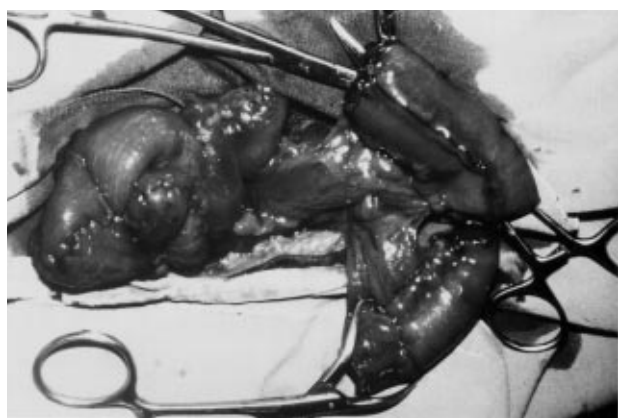


Figure 1. (b) Before anastomosis two valve systems and following appendectomy ascending colon.

detubularized colon (Fig. 1b). After catheterization of both efferent limbs was tested and found satisfactory in both ileal segments, the pouch was formed by folding the colon transversely. Two flush stoma were then created equidistant from the midline—the left one for the nipple valve and the right for the Benchekroun hydraulic valve(Fig. 2). Before closure, the filling capacity

of the pouch and the continence of the valves were tested. For Benchekroun valve stoma, a peristomal skin flap was advanced into the stomal orifice. Beginning on postoperative day 1, the pouch was catheterized and flushed daily with saline. Ten weeks after surgery, all dogs underwent urodynamic and radiologic studies under general anaesthesia then were sacrificed for post-mortem examination. Twelve F double channelled catheter connected to a pressure transducer was inserted into the pouch through one of the afferent limbs. The pouch was filled with saline in order to evaluate contralateral efferent limb. The maximal leakage point volume was defined as the volume at which either catheter by pass or stomal leakage occurred. The maximum leak point pressures were measured when the pouche was fully filled and half-filled with manuel compression. Via both stomas daily catheterization was attended in all dogs. Catheterization attempts were recorded as successssful or failed. Before urodynamic studies pouchograms were performed. Comparable data from each valve were statistically evaluated through Mann-Whitney U test

Results

No major surgical problems were encountered in any of the dogs except for the dog with number 3, which had partial dessusception of its nipple valve. One in the nipple valve series and two in Benchekroun series totally 3 stomal stenosis were observed and underwent dilation, the stomal complication rates is not statistically significant (p>0.05). For the nipple and the Benchekroun valves, totally 694 and 615 catheterization were attempted, respectively. There was no apparent difference in terms of ease of catheterization between the two techniques (p>0.05)(Table 1). Radiological examination revealed no fistula in ten dogs. The average volume at which leakage occurred during urodynamic studies was 337.1±105.0 cc for the Ben-

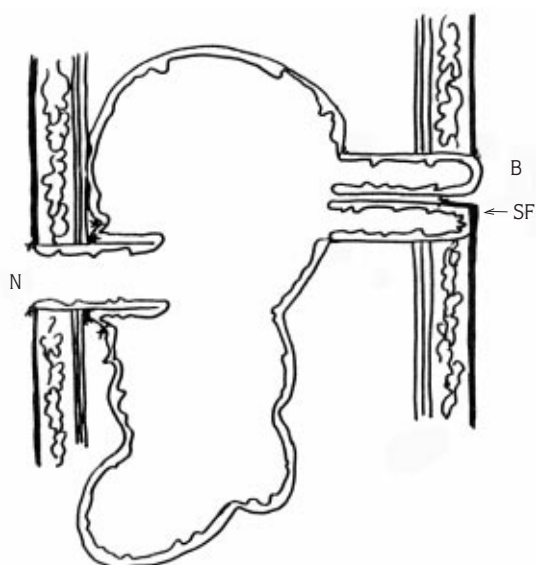


Figure 2. Frontal section of the pouch and its two outlets illustrated. B: Benchekroun, N: Nipple valve, SF: Peristomal skin flap.

chekroun valve and 213.5 ± 58.9 cc for the nipple valve. This difference was significant with p -value < 0.01 (Table 1). With the pouch filled to the capacity, maximal leak point pressure in the Benchekroun valve was 75.9 ± 35.0 cc water. The maximum leak point pressures within the nipple valve were measured 48.4 ± 20.5 ($p > 0.05$). In the Benchekroun hydraulic ileal valve, the maximal leak point pressure of the pouch at half capacity was 64.8 ± 28.0 cm water. The same parameter was measured for the nipple valve as 47.3 ± 20.2 cm water ($p > 0.05$).

Discussion

In many urologic and neurologic conditions, the basic functions of bladder may be altered (neuropathic bladder) or non-existent. The ileal conduit is still most popular and frequently utilized method of urinary diversion subsequent to cystectomy for cancer [7]. Such patients must tolerate the wearing of an ostomy appliance, and they usually resume most of normal activities. For this reason, the continent urinary reservoirs are becoming an integral part of modern reconstructive surgery. Many surgical procedures have been employed to construct effective continent valve (or channel). Appendix vermiformis, ureter, fallopian

tube, tapered or non-tapered ileum, encircling loop valve, ileal nipple valve and Benchekroun hydraulic ileal valve are alternatives for catheterizable continent channel [3,5,9,10,13-16,19]. Burger reported that appendiceal valve might be frequently associated with stomal complications [4]. Furthermore, appendix may have been removed or is unsuitable, and the fallopian tube is not available for male patient for a Mitrafanoff procedure. The distal ureter could be used as catheterizable stoma [19]. However, this procedure may require an additional procedure as a transureteroureterostomy [5]. Intussusception of an ileal segment has been used for several small bowels as well as colonic reservoirs as a continent channel. The nipple valve was first described by Perl in 1949 [20]. Kock and associates demonstrated in the laboratory the efficiency of continent ileal pouch as a urinary reservoir by intussusception an ileal segment [12]. Since then, the procedures have been revised numerous times by several authors [6,8,22,23]. However, an efferent limb revision rate of 9% to 58.3% leads the urologic surgeons to search for alternative method [7]. Complication of nipple valve system basically consists of incomplete adhesion of the invaginated serosal surfaces of the valve [18]. Although further modifications to prevent nipple slippage have been advocated as the use of surgical stapler and non-absorbable collar, this modified procedure may cause stone formation [1,9,17]. Benchekroun described the hydraulic ileal valve in 1978 [2]. Urine can circulate between the double wall of this valve and the reservoir that allows compression of the internal segment thereby obstructing the central lumen. The principal complications of Benchekroun valve are intussusception, valve fistula and stomal stenosis [17,21]. Main objective in performing this study is to compare Benchekroun hydraulic valve and nipple valve simultaneously and directly to be drawn without the inherent error of comparing different reservoirs under different conditions. The data show that the mean leak volume of Benchekroun valve is higher than that causing leakage in the nipple. The maximum leak point pressure and, in half-filled pouches, mean leak point pressures were similar for both valve systems which is a result from the continence of the Benchekroun valve is more volume dependent than that of the nipple. Although the complications and catheterizability of each valve are close to each other, we currently favor Benchekroun hydraulic ileal valve at the pouch with higher volume in the light of these parameters. Research fellow, Mr. Arif Şahin provided expert statistical assistance.

References

1. Benckroun A: Continent caecal bladder. *Eur Urol.* 3:248-50,1978.
2. Benckroun A, Essakali N, Faik N: Continent urostomy with hydraulic ileal valve in 136 patients: 13 years of experience. *J Urol.* 142:46-51,1984.
3. Kock NG, Berglund B, Ghaneim MA: Urinary diversion to the augmented and valved rectum. An experimental study in dogs. *Scand J Urol Nephrol.* 22:227-31, 1988.
4. Weinberg AC, Xie NW, Hardy BE, Skinner DG: Juvenile animal model to study the potential of bowel segments in the urinary tract. *J Urol.* 143:377-80, 1990.
5. deKernion JB, Mohammed E: Urinary diversion and continert reservoir. In: Gillenwater WY, Grayhack JT, Howards SS, Duckett JW(ed). *Adult and pediatric urology.* Year book medical publishers INC., Chicago, 1987;Ch 32,pp. 1044-62.
6. Cendron M, Gearhart JP: The Mitrofanoff principle Technique and application in continent urinary diversion. *Urol Clin North Am.* 18:615-21,1991.
7. Hensle TW, Dean GE: Complications of urinary tract reconstruction. *Urol Clin North Am.* 18: 755-64, 1991.
8. Kock NG, Nilson AE, Norlen LJ: Urinary diversion via a continent ileum reservoir: Clinical experience. *Scand J Urol Nephrol.* 149-50,1978.
9. Kock NG, Norten L, Philipson BL: The continent ileal reservoir for urinary diversion. *World J Urol.* 3:146-48,1985.
10. Koff SA, Cirulli C, Lucero P, Hamoudi A: An operation to create a continent catheterizable urinary sphincter from a short intestinal segment: Experimental observation. *J Urol.* 138:996-1001, 1987.
11. Koff SA, Cirulli C and Wise HA: Clinical and urodynamic feature of a new intestinal urinary sphincter for continent urinary diversion. *J Urol* 142: 293-97, 1989.
12. Mitrofanoff P: Cystostomie continente transappendiculaire dans le traitement des vessies neurologiques. *Chir Pediatr.* 21:297-301,1980.
13. Kato H, Khaleque MA, Taguchi I: A continent urinary valve by a subfascial ileal segment in dogs. *J Urol.* 153: 218-21, 1995.
14. Burger R, Wanmack R, Fisch M: The appendix as a continence mechanism. *Eur Urol.* 22:255-57, 1992.
15. Perl JI: Intussuscepted conical valve formation in jejunostomies. *Surg.* 25:297-99,1949.
16. Kock NG, Nilson AE, Norlen L:Changes in renal parenchyma and the upper urinary tracts following urinary diversion via a continent ileum reservoir: An experimental study in dogs. *Scand J Urol Nephrol.* 49-51, 1978.
17. deKernion JB, DenBesten L, Kaufman JJ: The kock as a urinary reservoir: Pitfalls and perspectives. *Am J. Surg.* 150:83-7, 1985.
18. Gerber A: The Kock continent ileal reservoir for supravescical urinary diversion. *Am J Surg.* 146: 15-9, 1983.
19. Skinner DG, Boyd SD, Lieskovsky G: Clinical experience with the Kock continent ileal reservoir for urinary diversion. *J Urol.* 132: 1101-04, 1984.
20. meijer DW, Klopper PJ: Construction of a stable nipple valve with processed dermal sheep collagen for continent ileostomy and urostomy. *Urol Res.* 18: 353-55, 1990.
21. Arai Y, Kawakita M, Terachi T: Long-term follow up of the Kock and Indiana pouch procedures. *J Urol.* 150: 51-5, 1993.
22. Leonard MP, Quinlan DM: The Benckroun ileal valve. *Urol Clin North Am.* 18: 717-24, 1991.
23. Schiff SF, lytton B: Incontinence after augmentation cystoplasty and internal diversion. *Urol Clin North Am.* 18: 383-92, 1991.