

Effects of Acute Fenthion Toxicity on Liver and Kidney Function and Histology in Rats

Mustafa KEREM¹

Nurdan BEDİRLİ²

Neslihan GÜRBÜZ³

Özgür EKİNCİ⁴

Abdulkadir BEDİRLİ¹

Taylan AKKAYA²

Ömer ŞAKRAK¹

Hatice PAŞAOĞLU⁵

¹ Department of General Surgery,
Faculty of Medicine,
Gazi University,
Ankara - TURKEY

² Department of Anesthesiology,
Dışkapı Training and
Research Hospital,
Ankara - TURKEY

³ Department of Toxicology,
Faculty of Medicine,
Gazi University,
Ankara - TURKEY

⁴ Department of Pathology,
Faculty of Medicine,
Gazi University,
Ankara - TURKEY

⁵ Department of Biochemistry,
Faculty of Medicine,
Gazi University,
Ankara - TURKEY

Aim: The aim of this study was to investigate the dose-related effects of fenthion on the liver and kidney and the correlation between severity of organ damage and serum butyrylcholinesterase (BChE) enzyme levels.

Materials and Methods: Ninety rats were randomly subdivided into control group and 4 study groups. Control group was administered 1 ml of saline intraperitoneally. Study groups received 25, 50, 75 and 100 mg/kg of fenthion, intraperitoneally. Blood samples and renal and hepatic tissues were collected 24 h after dosing and survival was monitored for 7 days.

Results: Mortality was observed in 2 rats receiving 75 mg/kg fenthion and in 3 rats receiving 100 mg/kg fenthion within 2 days of the experiment. There was a correlation between the fenthion dosage and increase in the blood levels of liver enzyme, creatinine and blood urea nitrogen (BUN). Plasma BChE enzyme levels in rats receiving 75 and 100 mg/kg fenthion were statistically lower compared to rats receiving 25-50 mg/kg fenthion at 24 h. Histopathologic examination of the liver and kidney indicated a significant injury only in rats receiving 100 mg/kg fenthion.

Conclusion: The organophosphate fenthion, particularly at high dosage, has a toxic effect on the liver and kidney and its toxicity is correlated with BChE enzyme levels.

Key Words: Fenthion, butyrylcholinesterase, hepatotoxicity, nephrotoxicity

Ratlarda Akut Fentoin Zehirlenmesinin Karaciğer, Böbrek Fonksiyonları ve Histolojisine Etkisi

Amaç: Bu çalışmanın amacı fenthion'un karaciğer ve böbrek üzerine doza bağımlı olan etkilerini araştırmak ve serum bütirikolinesteraz (BChE) enzim seviyeleri ile organ hasarının şiddeti arasındaki korrelasyonu araştırmaktır.

Yöntem ve Gereç: Rastgele seçilen 90 rat kontrol ve çalışma gruplarına dahil edildi. Kontrol grubuna 1 mL serum fizyolojik, çalışma gruplarına ise sırasıyla 25, 50, 75 ve 100 mg/kg fentoin intraperitoneal olarak verildi. Kan örnekleri ile karaciğer ve böbrek doku örnekleri ilaç verilmesinden 24 saat sonra toplandı. Aynı bir deneysel grupta, serum fizyolojik ve fenthion verildikten sonraki 7 gün süreyle sağ kalım gözlemlendi.

Bulgular: Çalışmanın ilk iki gününde 75 mg/kg fentoin alan 2 ratta ve 100 mg/kg fentoin alan 3 ratda mortalite gözlemlendi. Fentoin dozu ile kandaki karaciğer enzim seviyeleri, kreatinin ve BUN değerleri arasında anlamlı bir korrelasyon gözlemlendi. 25-50 mg/kg fentoin alan ratlara kıyasla, 75-100 mg/kg fentoin alan ratlarda 24. saatteki plazma BChE enzim seviyeleri daha yüksekti. Histopatolojik incelemede sadece 100 mg/kg fentoin alan gruptaki karaciğer ve böbrek hasarı anlamlı olarak yüksek bulundu.

Sonuç: Sonuç olarak çalışmamızda, 75-100 mg/kg fentoin karaciğer ve böbrek üzerine toksik etkili olarak bulunmuştur ve bu toksik etki BChE enzim seviyeleri ile korrelasyon göstermiştir.

Anahtar Sözcükler: Fentoin, bütirikolinesteraz, karaciğer toksisitesi, böbrek toksisitesi.

Introduction

Organic insecticide poisoning remains one of the major health issues in both developing and developed communities (1). A great proportion of acute poisoning cases are caused by exposure to pesticides, especially organophosphate (OP) compounds. The primary mechanism of action of OP pesticides is based on inhibition of the acetylcholinesterase (AChE) enzyme (2). Once AChE has been inactivated, acetylcholine (ACh) accumulates throughout the nervous system, resulting in overstimulation of muscarinic and nicotinic receptors. Signs and symptoms of OP poisoning can be divided into three broad categories, as muscarinic, nicotinic, and central nervous system effects. Management of severe poisoning is difficult, requiring intensive care and use of atropine and oxime cholinesterase reactivators (3).

Received: May 03, 2007
Accepted: September 28, 2007

Correspondence

Mustafa KEREM
Gazi University, Medical Faculty,
Department of General Surgery
Ankara - TURKEY

mkerem@gazi.edu.tr

Fenthion (*O,O*-dimethyl *O*-[3-methyl-4-(methylthio)phenyl]phosphorothioate) is a systemic OP insecticide widely used in both agricultural and urban areas (4). Due to its extensive application to crops and cattle, fenthion residue occurrence in food and the environment has been widely reported (5,6). Fenthion is moderately toxic via the oral route, with reported oral LD50 values of 180 to 298 mg/kg in rats, 150 mg/kg in rabbits, and 88 to 145 mg/kg in mice (7). It is slightly toxic via inhalation with a reported 1-hour airborne LC50 for fenthion in rats of 2.4 to 3.0 mg/L (8). Acute effects of fenthion are similar to those caused by other OPs, but may take somewhat longer to develop. In animals, fenthion is quickly absorbed into the bloodstream through the digestive tract, lungs, and skin, and is systemically distributed (9). It is eliminated through the urine and feces later. A single dose of fenthion has prolonged action, suggesting that much of it is stored in body fat and later released for metabolism (7). The liver and kidney are important sites for the oxidative metabolism of fenthion (10). Although the neurotoxicity induced by fenthion has been extensively studied, the effects of fenthion on the liver and kidney have not been fully investigated. Therefore, the primary aim of this study was to investigate a possible role of metabolic activation in fenthion-induced hepatotoxicity and nephrotoxicity.

Materials and Methods

The experimental protocols were conducted with the approval of the Animal Research Committee at Gazi University, Ankara. All animals were maintained in accordance with the recommendations of the National Institutes of Health Guidelines for the Care and Use of Laboratory Animals.

Chemical

Fenthion [*O,O*-dimethyl *O*-[3-methyl-4-(methylthio)phenyl]phosphorothioate] (Labeycid EC 50/500 ml, Bayer crop science, East Hawthorn, Australia) was used to induce hepatotoxicity and nephrotoxicity.

Animals and Experimental Design

Male Wistar rats weighing 230-280 g were housed individually in cages, and were allowed free access to standard rat chow and water before and after the experiments. The animal rooms were windowless with

temperature (22 ± 2 °C) and lighting controls. The animals were fasted overnight before the experiments but were given free access to water. They were anesthetized by ketamine 100 mg/kg and xylazine 20 mg/kg body weight, intraperitoneally. The animals were allocated to five groups:

Control group, (n = 18): after the procedures described above, 1 ml of saline was given intraperitoneally.

Fenthion group I (n = 18): after the procedures described above, fenthion was given intraperitoneally at a single dose of 25 mg/kg.

Fenthion group II (n = 18): after the procedures described above, fenthion was given intraperitoneally at a single dose of 50 mg/kg.

Fenthion group III (n = 18): after the procedures described above, fenthion was given intraperitoneally at a single dose of 75 mg/kg.

Fenthion group IV (n = 18): after the procedures described above, fenthion was given intraperitoneally at a single dose of 100 mg/kg.

All animals were reanesthetized 24 h after the fenthion or saline administration using intraperitoneal injection of sodium pentobarbital. A midline abdominal incision was made and the animals were sacrificed by exsanguination. All procedures were performed using aseptic techniques. Ten animals in each group were used for the analysis of survival. Their survival was assessed every 24 hours up to seven days after the fenthion or saline administration.

Sample Collection

Blood samples from the inferior vena cava were collected in heparinized tubes (Becton-Dickinson Franklin Lakes, NJ). Blood was centrifuged at 5000 rpm for 10 mins. The serum was separated and stored at -70° C until use. Liver and kidney biopsies were taken for the histopathological scoring.

Measurement of Serum Liver Enzymes

Serum aspartate aminotransferase (AST), alanine aminotransferase (ALT) and gamma-glutamyltranspeptidase (GGT) activities were measured to assess the damage to the hepatic parenchyma at 24 h after fenthion or saline administration using an Aeroset autoanalyzer (Abbott Laboratories, Illinois, USA).

Measurement of Renal Function Test

Blood urea nitrogen (BUN), creatinine and uric acid levels in serum were measured to assess the nephrotoxicity at 24 h after fenthion or saline administration using an Aeroset autoanalyzer.

Measurement of Serum Butyrylcholinesterase (BChE)

Serum BChE levels were measured by a quantitative enzymatic assay (Sentinal Diagnostics, Lot No: 40385)] using the Konelab 60i (Thermo Clinical Labsystem, Vantaa, Finland).

Histologic Analysis

Tissue samples from kidney and liver were fixed in 10% formalin. All tissues were blocked with paraffin and paraffin slices of 5-8 μ m were prepared. Hematoxylin-eosin stain was used and the preparations were evaluated under light microscope. The liver fields were scored as follows: 0 = normal, 1 = mild cellular disruption in less than 25% of field area, 2 = moderate cellular disruption and appearance of balloon cells and vacuolation in greater than 50% of field area, 3 = extensive cell disruption and vacuolation in greater than 50% of field area, 4 = extensive cell disruption with occasional centrilobular necrosis, and 5 = extensive cell disruption with multiple centrilobular necrosis in more than 50% of field area.

Tubular injury was defined as tubular dilatation, tubular atrophy, tubular cast formation, vacuolization, degeneration and sloughing of tubular epithelial cells, or thickening of the tubular basement membrane. Only cortical tubules were included in the following scoring system: 0 = no tubular injury, 1 = <10% of tubules injured, 2 = 10-25% of tubules injured, 3 = 26-50% of tubules injured, 4 = 51-75% of tubules injured, and 5 = >75% of tubules injured.

Statistical Methods

All values were expressed as the mean \pm SD. Data were compared by analysis of variance with post hoc analysis using Newman-Keuls test. When a difference was found, specific differences were identified by using Kruskal-Wallis test. Statistical evaluation was carried out by using SPSS 10.0 software (SPSS, Chicago, IL, USA). Values of $P < 0.05$ were accepted as significant.

Results

All animals receiving serum saline survived the seven-day observation period. Kaplan-Meier survival curves (Figure 1) showed 30% mortality after the 100 mg/kg fenthion administration ($P < 0.05$ versus control). The vast majority of lethality occurred within two days of experiment in toxic animals.

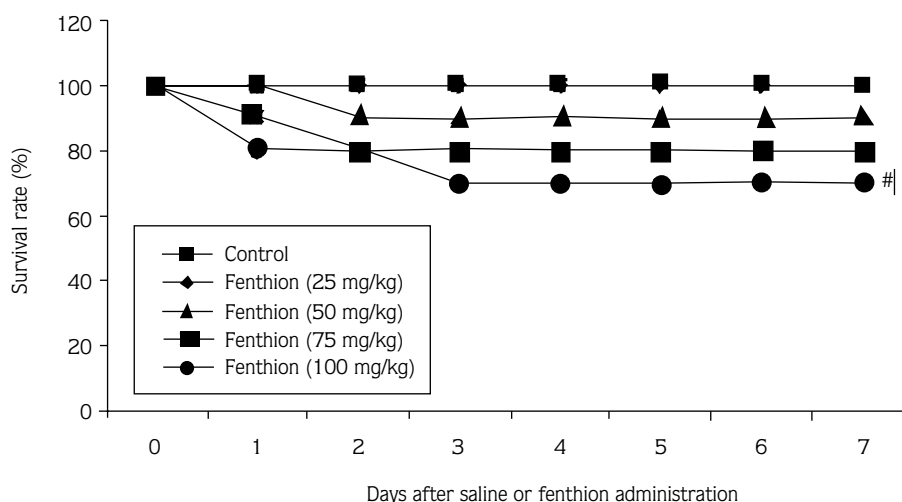


Figure 1. Effect of fenthion on survival. The survival rate was estimated by the Kaplan-Meier method and compared by using log-rank test: # $P < 0.05$, versus control group.

Changes in serum AST, ALT and GGT levels in each group are shown in Table 1. In the low-dose fenthion groups (25 mg or 50 mg/kg), AST, ALT and GGT levels were slightly increased at 24 h. Only with high-dose fenthion (75 mg or 100 mg/kg) did the rats show statistically significantly ($P < 0.05$) elevated AST, ALT and GGT levels after 24 h.

Table 2 summarizes the renal function assays after the saline or fenthion administration. There was a rise in BUN and creatinine levels at the end of 24 h in the serum of rats exposed to low-dose fenthion, but no significant difference when compared with the control group. However, BUN and serum creatinine levels at 24 h were markedly elevated ($P < 0.05$) in fenthion groups III and IV compared to controls with normal renal function. Serum uric acid was not significantly different compared with controls.

To study the effect of fenthion on enzyme activity, we evaluated plasma BChE activity at 24 h following treatment with single intraperitoneal injection doses of fenthion (Figure 2). There was no significant change in the enzyme activity in the animals treated with either 25

mg/kg or 50 mg/kg fenthion. However, animals treated with either 75 mg/kg or 100 mg/kg fenthion exhibited a significant decrease ($P < 0.05$) in plasma BChE activity at 24 h (16% and 22% of control, respectively).

Sections from the control group showed normal liver histology (Figure 3A). There were minimal cellular changes such as only congestion and Kupffer cell activation and sometimes moderate central lobular injury following the fenthion administration in liver biopsies in mid-dose fenthion groups (25 mg or 50 mg/kg). In high-dose fenthion groups (75 mg or 100 mg/kg), grade 2-3 changes occurred following fenthion administration (Figure 3B). Kidney sections from the mid-dose fenthion groups (25 mg or 50 mg/kg) were comparable with controls, although some tubular dilatation and atrophy were present in the cortex (Figure 4A). Parenchymatous degeneration of cells of renal tubules and infiltration between the proximal tubules were observed in high-dose fenthion groups (75 mg or 100 mg/kg) (Figure 4B). Histopathologic examination of the liver and kidney indicated a significant injury only in rats receiving 100 mg/kg fenthion (Table 3).

Table 1. Serum chemistry and liver function tests after treatment with fenthion.

	Control	Fenthion (25 mg/kg)	Fenthion (50 mg/kg)	Fenthion (75 mg/kg)	Fenthion (100 mg/kg)	P
AST (U/L)						
24 h	98 ± 12	124 ± 27	128 ± 53	217 ± 46	225 ± 75	0.01
ALT (U/L)						
24 h	76 ± 12	102 ± 15	114 ± 23	243 ± 35	318 ± 72	0.004
GGT (U/L)						
24 h	5.7 ± 1.9	7.4 ± 1.0	10.2 ± 1.8	17.2 ± 1.9	18.4 ± 2.3	0.002

Table 2. Serum chemistry and renal function assay after treatment with fenthion.

	Control	Fenthion (25 mg/kg)	Fenthion (50 mg/kg)	Fenthion (75 mg/kg)	Fenthion (100 mg/kg)	P
BUN (mg/dl)						
24 h	43 ± 7	52 ± 12	65 ± 9	129 ± 14	141 ± 15	0.01
Creatinine (mg/dl)						
24 h	0.4 ± 0.12	0.6 ± 0.10	0.6 ± 0.12	1.1 ± 0.16	1.7 ± 0.24	0.04
Uric acid (mg/dl)						
24 h	97 ± 17	104 ± 46	118 ± 71	135 ± 92	147 ± 89	N.S.

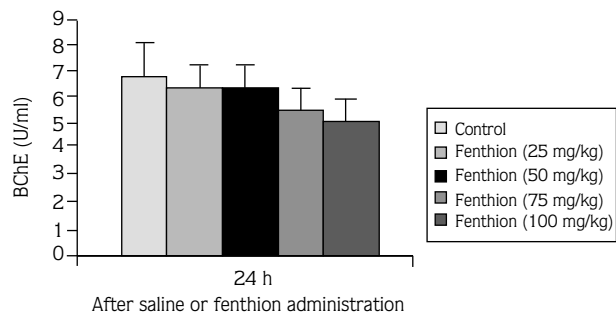


Figure 2. Effect of treatment with fenthion on plasma BChE activity. Data are presented as mean ± SE. **P* < 0.05, versus control and fenthion (25 mg and 50 mg/kg) groups.

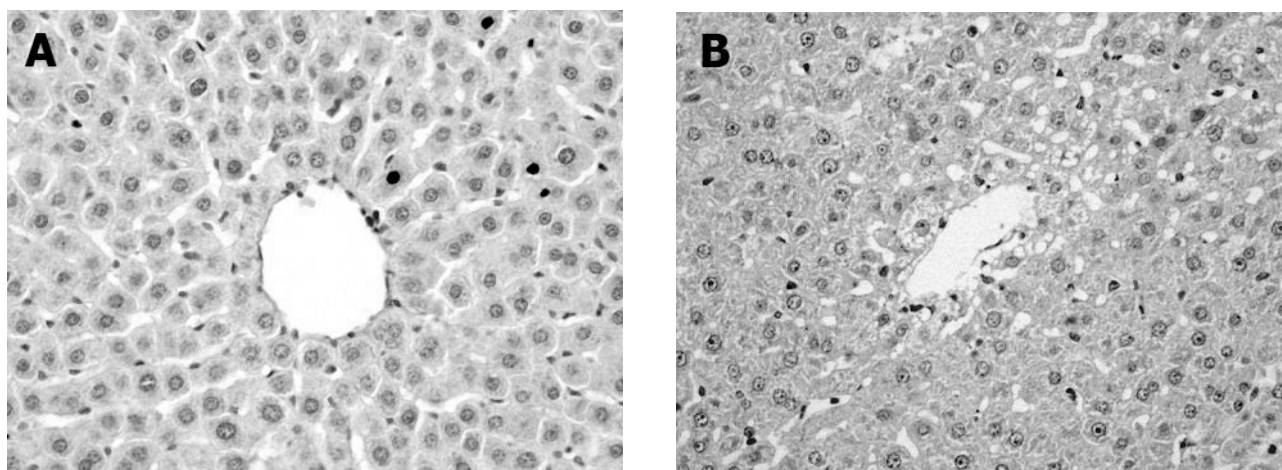


Figure 3. Microscopic findings of livers after fenthion administration at 24 h (HE×200). A: No features of cell injury after mid-dose (25 mg or 50 mg/kg) fenthion administration; B: In high-dose fenthion groups (75 mg or 100 mg/kg), there was mild injury, such as hepatocytes swelling and vacuolization and sometimes moderate central lobular injury.

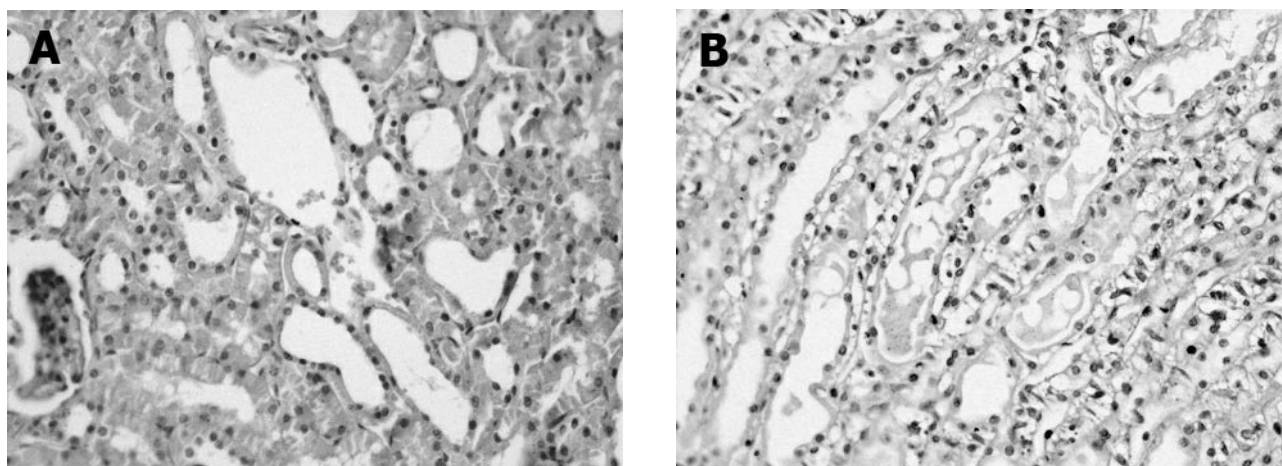


Figure 4. Microscopic findings of kidneys after fenthion administration at 24 h (HE×200). A: There were minimal changes such as tubular dilatation and atrophy present in the cortex in mid-dose fenthion groups (25 mg or 50 mg/kg); B: Parenchymatous degeneration of cells of renal tubules and infiltration between the proximal tubules in high-dose fenthion groups (75 mg or 100 mg/kg).

Table 3. Histopathologic changes in rats.

	Control	Fenthion (25 mg/kg)	Fenthion (50 mg/kg)	Fenthion (75 mg/kg)	Fenthion (100 mg/kg)	P
Severity of hepatic injury 24 h	0.0 ± 0.00	0.2 ± 0.02	0.4 ± 0.09	0.9 ± 0.44	1.4 ± 1.25	0.04
Severity of renal injury 24 h	0.0 ± 0.00	0.4 ± 0.10	0.6 ± 0.12	1.2 ± 0.38	2.7 ± 0.84	0.022

Discussion

OP-induced acute effects, mediated by the AChE inhibition in synapses and neuromuscular junctions, are responsible for most of the thousands of deaths reported annually worldwide in association with accidental or intentional pesticide intoxications. Since the second World War, more than 100 such compounds have been developed as insecticides. Poisoning from OP insecticides has occurred by accidental exposure through the skin and airways (11), self-ingestion from attempted suicides (3,12), and rarely, from deliberate homicide (13). The mortality rate from OP poisoning is high, and important factors contributing to this high mortality are delay in diagnosis and improper management. In contrast, early diagnosis and appropriate treatment are often lifesaving, although the clinical course of OP poisoning might be quite severe and necessitate intensive care management (14). Thus, in such poisoning cases, rapid toxicological screening is necessary for correct diagnosis.

Fenthion was first evaluated in 1971 and has been reviewed several times since, most recently in 1989. Patterns of absorption, distribution, metabolism and elimination of administered fenthion are broadly comparable between rats, pigs, cows and goats (7). Absorption is rapid after any route of exposure, distribution is extensive particularly into lipid stores, metabolism is extensive and can generate active anti-ChE intermediates, and elimination is almost complete (9). In general, signs of acute fenthion intoxication in animals were consistent with ChE inhibition, and included inactivity, salivation, muscle fasciculations, dyspnea, flaccid paralysis, vomiting, piloerection, exophthalmia, and diarrhea (2). Many of the OPs are potent inhibitors of AChE, and oxidative metabolism may further bioactivate these compounds to inhibitors that are many times more potent than the parent compound (15). The classical laboratory tests for exposure to OP toxicants are

inhibition of AChE and BChE activity in blood. We also observed that fenthion challenge significantly decreased the levels of BChE in plasma.

Fenthion was easily converted to fenthion oxon derivatives by mixed function oxidase in fish and rats (16). The metabolites showed much higher anticholinesterase activity than the parent pesticides (2); paraoxon has two hundred-fold higher activity than parathion. Thus, the conversion of fenthion to the oxon in rats is of considerable toxicological significance. Although OPs are quickly absorbed through the skin and mucous membranes, signs and symptoms of acute toxicity after dermal exposure appear much later compared to those after ingestion (17). Moreover, fenthion is known to have a highly cumulative effect, probably due to its high solubility in fat tissue (18). The acute oral and intraperitoneal toxicity of the oxygen analogue of fenthion and its sulfoxide and sulfone derivatives, thought to be the principal active metabolites, were 5-10-fold that of fenthion (7,9). The acute toxicity of fenthion formulations was closely correlated with the concentration of the active constituent in the end-use products. The signs associated with intoxication were similar to those seen with the active constituent. In our study, rats received saline or 25, 50, 75 and 100 mg/kg of fenthion, intraperitoneally. No deaths were observed in the saline and 25 mg/kg fenthion groups. Two of 10 animals died in the 75 mg/kg and three died in the 100 mg/kg groups. Moreover, high-dose fenthion induced a severe hepatic damage as represented by markedly elevated levels of AST, ALT and GGT coupled with a marked hepatic tissue injury. Recently, Tos-Luty et al. (19) showed that malathion intoxication can lead to a damaging effect on the intracellular structure of the liver. Another finding of this study was that fenthion exposure in rats led to an acute renal failure. Both BUN and serum creatinine levels increased after high-dose fenthion

administration. The kidney, the major detoxification organ for many xenobiotics, is frequently susceptible to their nephrotoxic effects. Acute renal failure was reported following exposure to OPs. The transient renal injury was attributed in these studies to both a direct action of the OP, causing tubular cell necrosis, and to a secondary mechanism that followed the cholinergic crisis, causing hypovolemic shock and rhabdomyolysis (20,21).

Many steps along the metabolic/detoxification pathways of these OPs can be different in the rat. The pesticides in this mixture are metabolized via liver hydrolysis to active (and more potent) metabolites (22). The cytochrome P450 and flavin-containing monooxygenase (FMO) enzymes are the major oxidative enzymes in phase I metabolism. Many OP and carbamate thioether compounds are excellent substrates for these enzymes. P450 enzymes are involved in both oxidative desulfuration of the phosphorothioate to form the oxon

and oxidation of the thioether group to the corresponding sulfoxide and sulfone of various OPs (10). The FMOs are generally limited to the formation of sulfoxides (23). A recent comprehensive study on oxidative OP metabolism by P450 and FMO isoforms found sulfoxidation of several thioether pesticides in human liver microsomes to be mainly P450-driven (85–90%), with the remainder accounted for by FMO (24).

In conclusion, results of serum biochemical analysis revealed that treatment with an intraperitoneally single dose of fenthion (75 or 100 mg/kg) significantly increased blood levels of AST, ALT and GGT, indicating liver toxicity, and increased BUN and serum creatinine levels, showing that kidney function was affected. The majority of the changes observed in our study, especially on the ultrastructural level, confirm that higher doses of fenthion applied intraperitoneally exert both liver and renal injury.

References

- Peter JV, Cherian AM. Organic insecticides. *Anaesth Intensive Care* 2000; 28: 11-21.
- Eto M. Organophosphorus pesticides. Organic and biological chemistry. Boca Raton (FL): CRC Press; 1979.
- Eddleston M, Eyer P, Worek F, Mohamed F, Senarathna L, von Meyer L et al. Differences between organophosphorus insecticides in human self-poisoning: a prospective cohort study. *Lancet* 2005; 366: 1452-9.
- Krieger RI. Handbook of pesticide toxicology. New York (NY): Academic Press; 2001.
- Berrada H, Fernandez M, Ruiz MJ, Molto JC, Manes J. Exposure assessment of fruits contaminated with pesticide residues from Valencia, 2001-03. *Food Addit Contam* 2006; 23: 674-82.
- Tsatsakis AM, Tsakiris IN, Tzatzarakis MN, Agourakis ZB, Tutudaki M, Alegakis AK. Three-year study of fenthion and dimethoate pesticides in olive oil from organic and conventional cultivation. *Food Addit Contam* 2003; 20: 553-9.
- U.S. Public Health Service, Hazardous Substance Data Bank. Washington (DC); 1995.
- Kidd H, James DR. The agrochemicals handbook. 3rd ed. Cambridge, United Kingdom: Royal Society of Chemistry Information Services; 1991.
- Gallo MA, Lawryk NJ. Organic phosphorus pesticides. In: Hayes WJ, Laws ER, editors. Handbook of Pesticide Toxicology. 2nd ed. San Diego: Academic Press; 1995. pp. 938-41.
- Furnes B, Schlenk D. Extrahepatic metabolism of carbamate and organophosphate thioether compounds by the flavin-containing monooxygenase and cytochrome P450 systems. *Drug Metab Dispos* 2005; 33: 214-8.
- Taira K, Aoyama Y, Kawamata M. Long QT and ST-T change associated with organophosphate exposure by aerial spray. *Environ Toxicol Pharmacol* 2006; 22: 40-5.
- Casey P, Vale JA. Deaths from pesticide poisoning in England and Wales. *Hum Exp Toxicol* 1994; 13: 95-101.
- Suzuki T, Morita H, Ono K, Maekawa K, Nagai R, Yazaki Y. Sarin poisoning in Tokyo subway. *Lancet* 1995; 345: 980-1.
- Sungur M, Guven M. Intensive care management of organophosphate insecticide poisoning. *Crit Care* 2001; 5: 211-5.
- Fukuto TR. Mechanism of action of organophosphorus and carbamate insecticides. *Environ Health Perspect* 1990; 87: 245-54.
- Kitamura S, Suzuki T, Kadota T, Yoshida M, Ohashi K, Ohta S. In vitro metabolism of fenthion and fenthion sulfoxide by liver preparations of sea bream, goldfish, and rats. *Drug Metab Dispos* 2003; 31: 179-86.
- Kipling RM, Cruickshank AN. Organophosphate insecticide poisoning. *Anaesthesia* 1985; 40: 281-4.
- Bai CL, Qiao CB, Zhang WD, Chen YL, Qu SX. A study of the pesticide fenthion: toxicity, mutagenicity and influence on tissue enzymes. *Biomed Environ Sci* 1990; 3: 262-75.

19. Tos-Luty S, Obuchowska-Przebirowska D, Latuszynska J, Tokarska-Rodak M, Haratym-Maj A. Dermal and oral toxicity of malathion in rats. *Ann Agric Environ Med* 2003; 10: 101-6.
20. Bardin PG, Van Eden SF, Joubert JR. Intensive care management of acute organophosphate poisoning. A 7-year experience in the Western Cape. *S Afr Med J* 1987; 72: 593-7.
21. Betrosian A, Balla M, Kafiri G, Kofinas G, Makri R, Kakouri A. Multiple system organ failure from organophosphate poisoning. *Clin Toxicol* 1995; 33: 257-60.
22. Pond AL, Chambers HW, Chambers JE. Organophosphate detoxication potential of various rat tissues via A-esterase and aliesterase activities. *Toxicol Lett* 1995; 78: 245-52.
23. Hajjar NP, Hodgson E. Flavin adenine dinucleotide-dependent monooxygenase: its role in the sulfoxidation of pesticides in mammals. *Science* 1980; 209: 1134-6.
24. Usmani KA, Karoly ED, Hodgson E, Rose RL. In vitro sulfoxidation of thioether compounds by human cytochrome P450 and flavin-containing monooxygenase isoforms with particular reference to the CYP2C subfamily. *Drug Metab Dispos* 2004; 32: 333-9.