

SHORT REPORT

Malignant Meningioma of Scalp

Mehmet Dumlu AYDIN¹, Canan ATALAY², Umran YILDIRIM³, Mustafa ATASOY⁴

¹Department of Neurosurgery, Faculty of Medicine, Atatürk University, Erzurum - Turkey

²Department of Anesthesiology and Reanimation, Faculty of Medicine, Atatürk University, Erzurum - Turkey

³Department of Pathology, Faculty of Medicine, Atatürk University, Erzurum - Turkey

⁴Department of Dermatology, Faculty of Medicine, Atatürk University, Erzurum - Turkey

Received: June 23, 2005

Key Words: Malignant meningioma, scalp

Malignant ectopic meningioma outside the central nervous system is extremely rare (9,12). Scalp meningiomas are benign, slow-growing tumours. They are histologically identical to their meningeal counterparts. Their diagnosis is based on histological examination (3). Curative treatment is possible, but the tumor may recur and metastasize (7). In this article, a case of malignant scalp meningioma is presented.

Case Report

We presented a 70-year-old woman with a 7x7x8 cm painfull and hemorrhagic mass on her scalp in the left parietal region associated with partially defective scalp. The mass has been presented for five years and had increased in size with time, and the lesion has started bleeding in the previous month. Neurological examination was normal. Cranial MRI showed a hyperintense, contrast enhanced mass on the left post-parietal region not extending into the cranium and with no evidence of intracranial meningioma (Figure 1).

2 mg i.m. midazolom (Dormicum amp) was given, with the aim of sedation, to the patient for whom an operation was planned under local anesthesia.

Mean arterial pressure, heart beat rate, SpO₂ were monitorized and two to three litres oxygen in flow rate was given to the patient by means of a nose cannule. After local anesthesia (6mg /kg % 1 Lidokain HCL) was applied, a nearly 12 cm- curvilinear incision was made directly over the mass including the defective area of the scalp. The richly vascularized and multilobulated tumor was easily removed totally and the defective area was comapeletely closed. Histopathologic diagnosis was malignant meningioma (Figure 2).Throughout the six months following the procedure, she remains well with no evidence of recurrence.

Ectopic meningioma outside the skull and spinal column is uncommon , but, it should be considered in the differential diagnosis of scalp lesions (12). Pathogenesis of primary cutaneous meningioma is quite obscure. Two possible sources for ectopic meningiomas have been proposed. It is believed that the origin of scalp meningiomas is from embryonal arachnoid cell rests in bones and nerve sheaths or differential maturation of pluripotent mesenchymal cells in these compartments (8). The patients with cutaneous meningeal tumors have a family history of neuro-cutaneal disease (1). Low-dose irradiation of the scalp may also cause development of meningioma (1,6).Clinically, the lesions appeared as

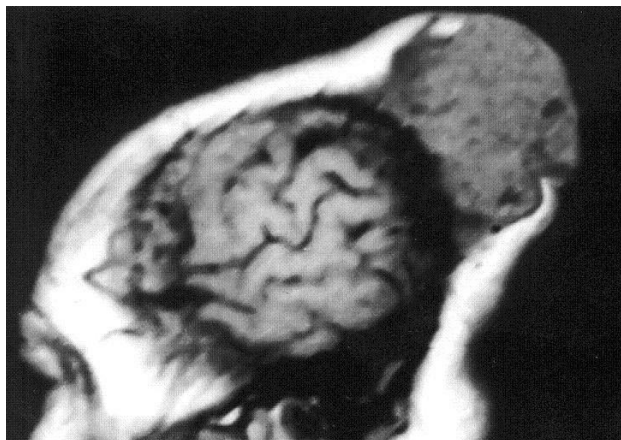


Figure 1. Preoperative post contrast sagittal T1-weighted MRI showing a 7x8x8 cm mass lesion in the left post parietal region expanding and eroding the scalp.

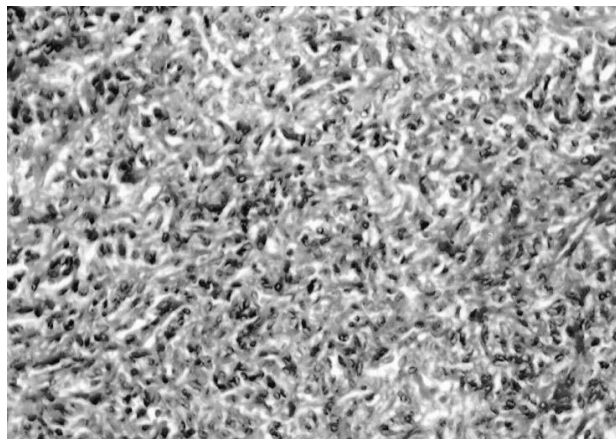


Figure 2. Histopathologic examination of the surgical specimen shows malignant meningioma (H&E, x100).

solitary, subcutaneous nodules suggesting a cystic vascular malformation or other benign condition (1). Scalp meningiomas are identical to those seen in the central nervous system (4). Most of the scalp meningiomas are fibroblastic or psammomatous type (10). Histologically, the lesions are characterized by a monotonous, pseudoinfiltrative proliferation of cuboidal epithelioid cells arranged in clusters within the dermis and subcutaneous tissue in intimate association with vessels, adipose tissue, and other connective tissue elements (13). There is no evidence of connection between the tumor and the underlying brain tissues on MRI examination (5). The tumor may indicate infiltrative growth and is located from the subcutaneous tissue to the meninges through the skull (9). Curative therapy of cutaneous meningiomas is possible (11). However, the tumor may recur and metastasize to other regions in the next periods (7). The mass may be removed totally and neuroradiological

studies prove the absence of an intracranial meningioma (2). Although extracranial meningioma is rare, it should be considered in the differential diagnosis of scalp lesions. The diagnosis is based on histological examination. Cutaneous meningiomas are benign, slow-growing tumors and in the absence of intracranial component, they have an excellent prognosis (3). The mass was removed totally, and all of the following neuroradiological studies proved the absence of an intracranial meningioma in the presented case.

Corresponding author:

Canan ATALAY

Gez Mah. No: 3/6

Kartopu Apt. A Blok

Erzurum - TURKEY

E-mail: cananatalay@hotmail.com

References

1. Argenyi ZB, Thieberg MD, Hayes CM et al. Primary cutaneous meningioma associated with von Recklinghausen's disease. *J Cutan Pathol* 21: 549-556, 1994.
2. Chappuis JP, Beaune B, Bouvier R et al. Meningioma of the scalp. Apropos of a case *Pediatr* 41: 227-230, 1986.
3. Hayhurst C, Mcmurtrie A, and Brydon H.L. Cutaneous meningioma of the scalp. *Acta Neurochir* 146,1383-4, 2004.
4. Kernohan JW, Sayre GP. Tumors of the central nervous system (atlas of tumor pathology). US Armed Forces Institute of Pathology, Washington 97-117, 1953
5. Le Pelletier F, Dunet E, Estephan H et al. Primary meningioma of the scalp. Report of a case. *Ann Pathol* 17: 75-76, 1997
6. Levin A, Aizenberg A, Shvartzman P. Benign meningioma following scalp irradiation in north African immigrants. *Harefuah* 128: 676-677, 1995
7. Mackay B, Bruner JM, Luna MA et al. Malignant meningioma of the scalp. *A Ultrastruct Pathol* 18: 235-240, 1994.
8. Majoros M. Meningioma of the paranasal sinuses. *Laryngoscope* 80: 640-645, 1970.

9. Masuda Y, Ito H, Nishigaki S et al. A case of malignant meningioma with subcutaneous infiltration of the scalp. *Gan No Rinsho* 32: 1849-1854, 1986.
10. Miyamoto T, Mihara M, Hagari Y et al. Primary cutaneous meningioma on the scalp: report of two siblings. *J Dermatol* 22: 611-619, 1995.
11. Nochomovitz LE, Jannotta F, Orenstein JM. Meningioma of the scalp. Light and electron microscopic observations. *Arch Pathol Lab Med* 109: 92-95, 1985.
12. Ragoowansi R, Thomas V, Powell BW. Cutaneous meningioma of the scalp: a case report and review of literature. *Br J Plast Surg* 51: 402-406, 1998.
13. Theaker JM, Fleming KA. Meningioma of the scalp: a case report with immunohistological features. *J Cutan Pathol* 14: 49-53, 1987.