

Use of Spongy Bone Chips and Fascia Temporalis in Alveolar Bone Defects

Hakan H. TÜZ¹, Ümit K. AKAL², Mine CAMBAZOĞLU², Reha Ş. KİŞNİŞCİ²

¹Department of Oral and Maxillofacial Surgery, Faculty of Dentistry, Kırıkkale University, Kırıkkale, Turkey

²Department of Oral and Maxillofacial Surgery, Faculty of Dentistry, Ankara University, Ankara, Turkey

Received: December 24, 2003

Abstract: Graft materials are used for inducement of regeneration in bone defects. Organic and synthetic bone graft materials facilitate remodeling or healing of the bone and induce new bone formation in the area of bone resorption caused by pathological, traumatic, and physiological reasons.

The aim of this study was to evaluate the effects of spongy allogenic bone graft and fascia temporalis membranous collagen tissue on the healing of bone defects clinically and radiologically. The study was carried out on 90 bone defects of 81 patients who underwent apicoectomy, cystectomy, and curettage of chronic infections in the maxilla and mandible. Defects were divided into 3 groups with respect to the way they were treated before soft tissue flap closure: with bone chips alone (D1), with bone chips and fascia temporalis (D2), and with no treatment (D3). Clinical and radiological examinations were carried out 1, 3, 6, and 12 months after surgery. Complications were observed in 5 defects in D1, 4 defects in D2, and 5 defects in D3. All defects ameliorated after treatment of the complications.

All 3 groups showed similar complication rates after surgery. Spongy bone chips either alone or covered with fascia temporalis reduced the overall osteogenesis period and prevented collapse of the mucosal soft tissue into the defect when compared with the controls.

Key Words: Spongy bone chips, fascia temporalis, allograft, mandible, maxilla

Introduction

Both soft and hard tissue grafts are frequently used in many oral and maxillofacial surgical procedures such as preprosthetic, temporomandibular, implant and sinus lifting surgery, and reconstruction of congenital, degenerative, inflammatory, cystic and neoplastic deformities (1-4).

Since it has a high regeneration capacity, bone is the material most often used in these restorative operations. Bone is the only tissue in which remodeling and apposition play a role in repair rather than scar formation in cases of pathologic, traumatic and physiologic bone resorption. Success in grafting is related to the vascularity, and osteogenic quality and quantity of the transplanted bone (1,5,6).

Rapid connective tissue formation in a spontaneously healing defect may influence the healing process and

prevent formation of new bone. In order to maintain regeneration of bone rather than soft tissue healing within the defect, various bone graft materials have been developed to date and successfully used in oral and maxillofacial surgery (2,7-11). The main purpose in skeletal reconstruction is to repair the defect with natural bone or any graft that may be replaced by natural bone. Bone substitutes can either be placed in the defect alone or in combination with a covering membrane underneath the soft tissue flap (12-15).

Optimal compatible grafts can be obtained from the patient's own body. Autogenic grafts have osteogenic and osteoinductive potential. Xenogenic grafts can be bovine and coral originated. Frozen, lyophilized, demineralized, decalcified, deproteinized and solvent dehydrated grafts are banked allogenic bones. Hydroxylapatite, ceramics of tricalcium phosphate, hard tissue replacement (HTR), and porous polymethylmethacrylate are the most widely used

synthetic (alloplastic) materials. Banked bones provide healing by osteoinduction, osteoconduction and resorption, whereas synthetic bones by osteoconduction alone (1,4,16-18).

Autogenic soft tissue grafts may be dermal, mucosal, fascial or myocutaneous. Dura, fascia, pericard, other collagenous membranes, laminar bone, and flexible demineralized bone are used as allogenic grafts. Polylactic acid (PLA), polyglycolic acid (PGA), polyurethane, polytetrafluoroethylene (PTFE, teflon) and titanium membranes are alternatives for synthetic membranes. Other combinations of these materials such as collastrips are also available (7,9,13,14,19).

In this study the effects of solvent dehydrated bone chips and fascia temporalis on bone healing were investigated by clinical and radiological means.

Materials and Methods

The study involved 81 patients with 90 defects who underwent cystectomy, curettage and apicoectomy in maxillary and mandibular alveolar processes. Patients with no systemic problems and good oral hygiene and female patients who were not menopausal were included in the study. Forty-two (51.8%) of the patients were female and 39 (48.1%) were male. The ages ranged between 15 and 46 years with a mean of 27.1. The distribution of the bone defects according to the patients was as follows: 3 defects in 1 patient, 2 defects in 7 and 1 defect in 73. Fifty-four (60%) of the bone defects were localized in the maxillary and 36 (40%) in the mandibular anterior region (Table 1).

Table 1 Clinical data of patients.

Total number of patients	81
Age distribution	15-46 (mean = 27.1)
Female patients	42 (51.8%)
Male patients 39	(48.1%)
Number of defects	90
Number of patients with 3 defects	1
Number of patients with 2 defects	7
Number of patients with 1 defect	73

All operations were carried out under local anesthesia with aseptic conditions. Three dimensional measurements (length, width, and depth) of all defects were obtained before placement of the bone substitutes. The defects were divided into 3 groups with regard to the way they were treated before wound closure: filled with bone alone (D1), with bone with fascia temporalis (D2), and with no treatment (D3). All specimens were sent for histopathologic evaluation.

Thirty bone defects in group D1 were filled with solvent dehydrated spongy bone chips (SDSBC) (Tutoplast-Spongioza, Pfrimmer-Viggo, Biodynamics Inc., Germany). Allografts in dehydrated form were subjected to rehydration in 0.9% physiological saline buffered with 1000 mg of ampicilin/sulbactam for 30 min before implantation (Figure 1). The mucoperiosteal flap was closed primarily with a non-absorbable suture material.

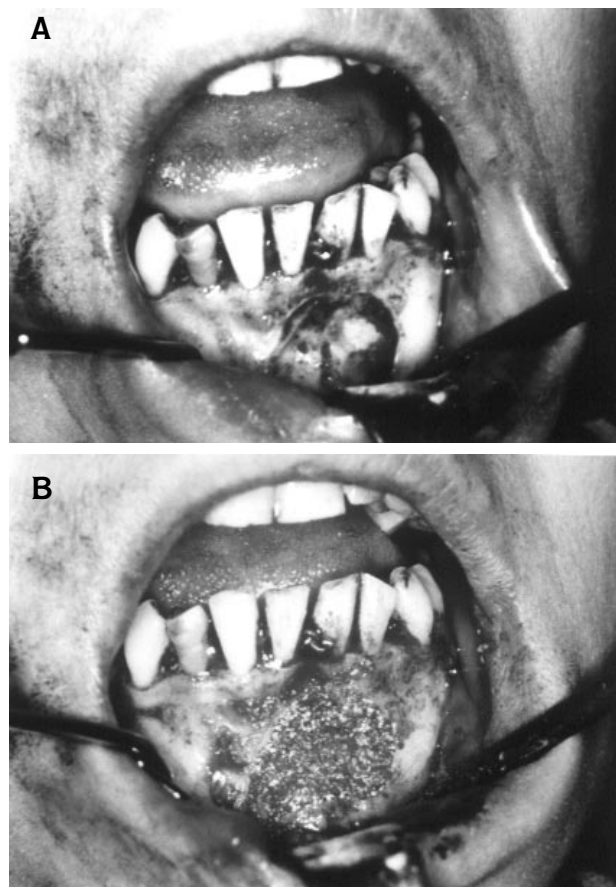


Figure 1. Filling the defect with spongy bone chips in the mandibular anterior region. A- View of the defect before grafting B-View of the defect filled with bone chips.

Thirty bone defects in group D2 were both filled with SDSBC and covered with fascia temporalis membranous collagen tissue allograft (SDFT) (Tutoplast-Fascia Temporalis, Pfrimmer-Viggo, Biodynamics Inc., Germany). SDFT was prepared in the same manner as mentioned above and placed on the bone chips so that it covered the defect 2-3 mm beyond the walls (Figure 2). The surgery ended with the primary closure of the mucoperiosteal flap.

In the control group, no grafts were used to fill or cover the bony defects and the wounds were left to heal spontaneously with only primary closure of the mucoperiosteal flap.

The patients were evaluated clinically and radiologically 1, 3, 6, and 12 months postoperatively. Individual bite blocks prepared before surgery with silicon based impression material were used in all patients in the

postoperative period so as to standardize the radiological assessment. Clinical examination included evaluation of infection, inflammation, and anomalies of the mucosa in the surgical site as well as healing of the flap, particle migration, postoperative pain, mobility of the apically resected teeth and gingival pus formation.

Density of the bone in the defect, compatibility of the graft with root surfaces of the operated teeth, existence of radiolucency at the defect margins and trabecular structure of the new bone were evaluated radiologically at 1 year follow up.

Results

Histologic evaluation revealed 43 (47.8%) of the lesions to be chronic purulent granulation tissue, 38 (42.2%) to be radicular cysts and 9 (10%) to be residual cysts. Average defect size for group D1 was 11.3 x 9.7 x

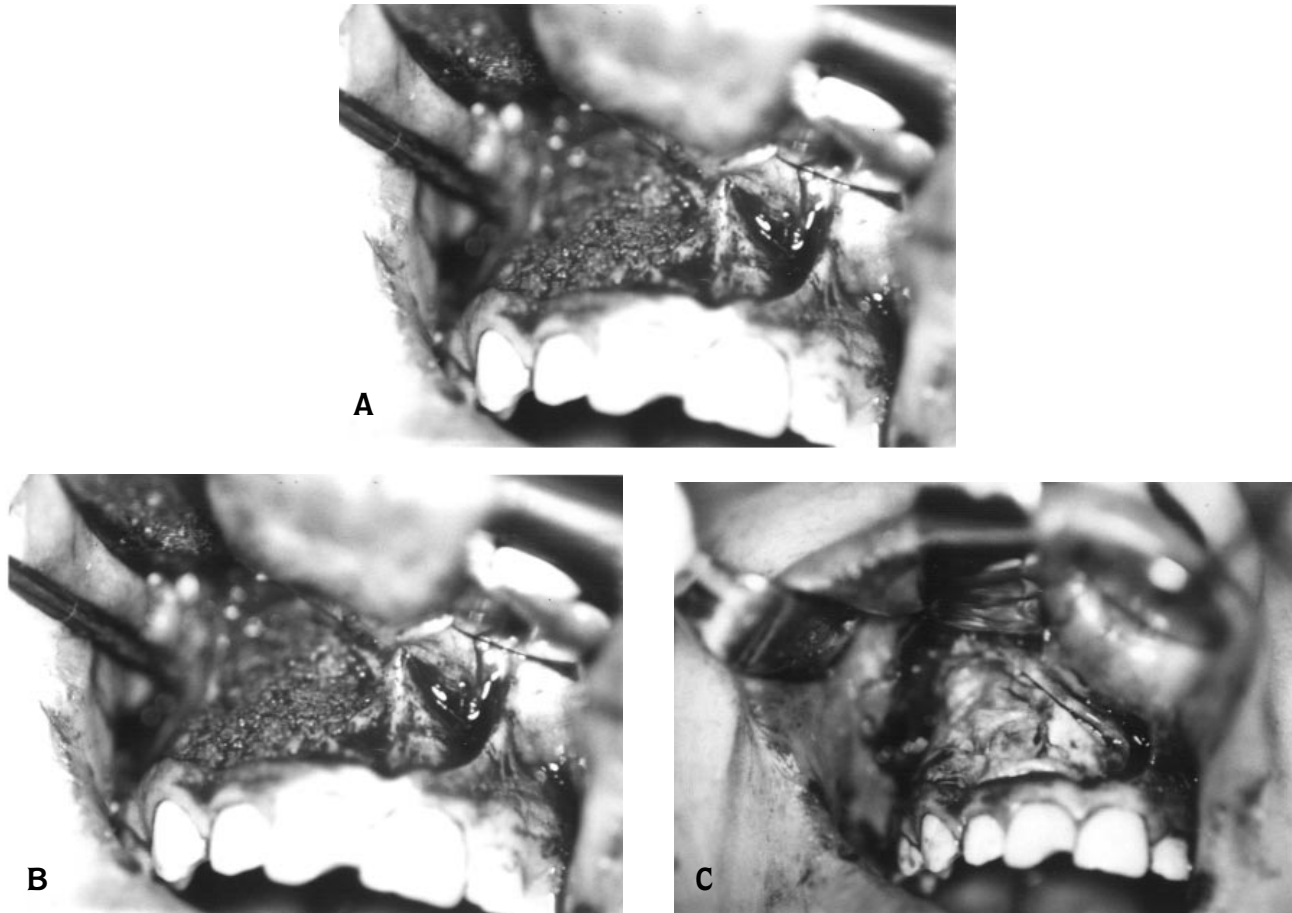


Figure 2. Use of bone chips and fascia temporalis together in the maxillary anterior region. A- View of the defect B- View after filling with bone chips C- Covering the defect with fascia temporalis.

9.2 mm, for group D2 was 14.2 x 11.8 x 9.6 mm, and for control defects was 9.4 x 9.3 x 9.2 mm.

In group D1, secondary infection was observed in 2 of the defects and particle migration with secondary infection in another 2. These were treated with antibiotics and topical mouth washes.

Postoperative 1 year radiological examinations revealed some loss of the chips due to migration; however, overall healing took place without event. Wound dehiscence occurred in one patient resutured on the fifth postoperative day. No complications were observed in 25 defects. The complication rate in group D1 was 16.6% whereas 83.3% of the defects healed without complication.

Two defects in group D2 revealed secondary infection, which was treated with antibiotics and topical mouth wash. Follow up radiographs after 1 year showed no symptoms of infection and healing occurred without any problem. Dehiscence of the flap was observed in 2 defects. Wound healing was maintained with resuturing. No clinical and radiological complications were observed in 26 of the defects. The complication rate was 13.3% and uncomplicated healing took place in 86.6%.

In the control group, secondary infection, which occurred in 2 defects, was treated with antibiotics and topical mouth washes. Radiological evaluation after 1 year revealed no infection and healing occurred without infection.

Slight collapse of the mucosa observed in one defect was compensated for at the end of bone healing. Flap

dehiscences in 2 defects were treated by resuturing on the fifth and sixth postoperative days. Particle migration was seen in 1 defect 6 months after surgery. No complications were observed in the rest of the defects. Full recovery took place according to clinical and radiological aspects. The rate of complication is 20.0% and success is 80.0% (Table 2).

Radiological assessment 6 and 12 months after surgery revealed that it took 1 year for the control defects to regain their normal trabecular structure (Figure 3). However, in groups D1 and D2 bone chips were replaced by new bone formation and the trabecular structure of the bone became visible without any formation of radiolucency within 6 months (Figures 4 and 5).

Table 2 Distribution of postoperative complications.

	SDSBC (D1)	SDSBC+SDFT (D2)	None (D3)
Number of defects	30	30	30
Infection	2	2	2
Particle migration	2	-	1
Flap dehiscence	1	2	2
Mobility	-	-	-
Gingival pus	-	1	-
Collapse of mucosa	-	-	-
TOTAL	5	4	6
RATE	-16.6%	-13.3%	-20%

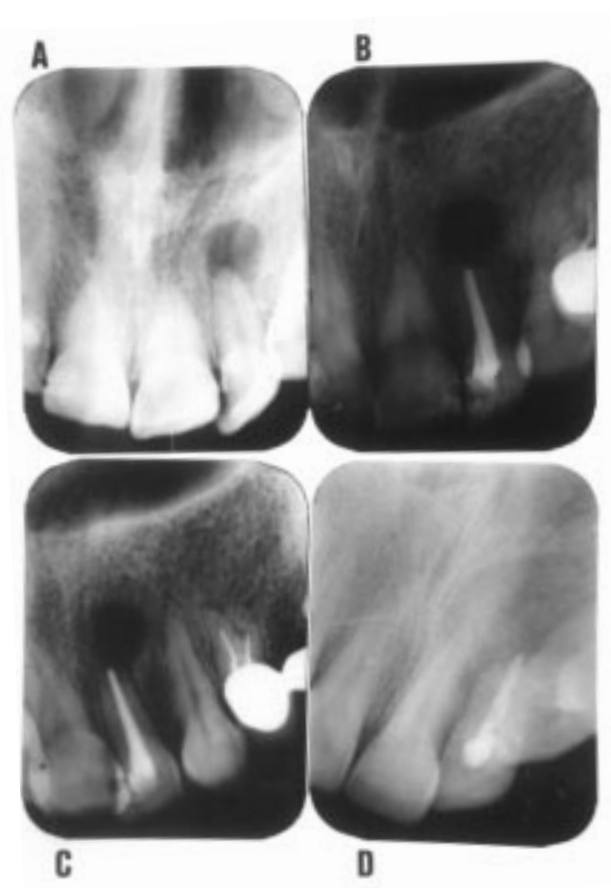


Figure 3. Radiological follow up of apically resected tooth in the control group. A-Preoperative view B-Postoperative 1st month C- Postoperative 3rd month D- Postoperative 1st year.

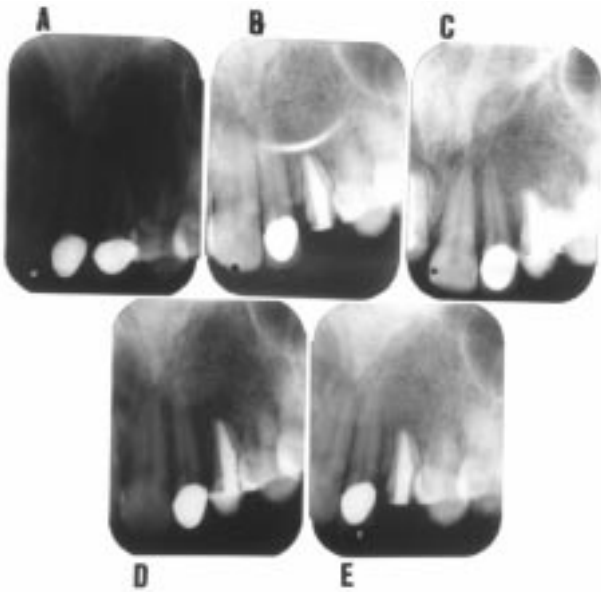


Figure 4. Radiological follow up of resected tooth in group D1. A- Preoperative view B-Postoperative 1st month C-Postoperative 3rd month D- Postoperative 6th month E- Postoperative 1st year.

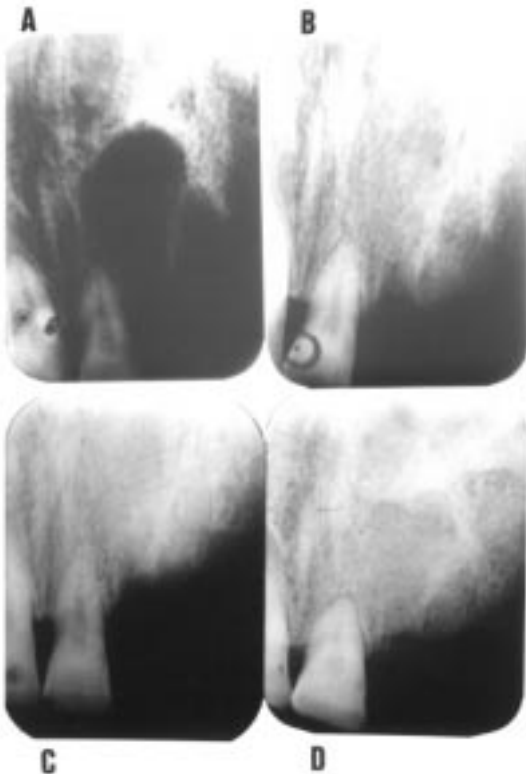


Figure 5. Radiological follow up of residual cyst enucleation in group D2. A- Preoperative view B-Postoperative 1st month C- Postoperative 3rd month D-postoperative 1st year.

Discussion

When soft and hard tissue grafts have to be used in oral and maxillofacial surgery, autogenic grafts are always preferred because of their high incidence of biocompatibility (1,4,20). Autogenic bone grafts ensure fast and good healing. They are osteogenic and osteoinductive and constitute a rigid structure for supporting the teeth and implants. However, a second operative site must be created for graft harvesting with a longer surgical procedure. Furthermore, adequate bone may not be obtained, resorption may occur and postoperative complaints such as pain as well as inability of function can be seen (4,17). Soft tissue grafts generally do not arouse any immunological reaction, and are well vascularized. However, these grafts also create a second surgical site. Moreover, morbidity at the donor site and the limited size of the graft that can be harvested are disadvantages. In cases of preprosthetic procedures, contraction of the dermal graft may result in the loss of vestibular depth (1).

Allogenic and alloplastic materials are often preferable in both soft and hard tissue graftings when the points stated above are considered. Banked allogenic grafts have gained more popularity due to their organic content and reduced immunologic potential. When revascularization is good at both the recipient bone and surrounding tissues, this type of grafting material yields such results as good as expected with autogenic grafts (1,8,12).

In this study, the rates of complication and success were very close in all 3 groups. No infection or foreign body reaction was observed in groups D1 or D2. Particle migration, which was seen in group D1 in 2 defects, was not detected in group D2 where membrane was used to cover the chips.

There are various sterilization and storage methods for allografts. The most frequently used for both bone and soft tissue allografts are lyophilization or dehydration with solvents. Lyophilization has not been performed recently since it cannot eliminate all viruses and it maltreats the collagen structure and yields weaker collagen fibers (8,12).

Nowadays the most popular technique is solvent dehydration. Tutoplast-Spongioza is a human originated allograft. In the selection of donors and preservation processes, tissue banking standards (21) are considered. It is important that the cadavers selected as donors do

not have any viral diseases. The upper age limit is approximately 50 for men and 40 for women. Spongy bone tissues obtained from the trochanter undergo cleaning and preservation processes. While they are dehydrated with solvents such as 0.1 NaOH (sodium hydroxide), H₂O₂ (hydrogen peroxide), acetone and additional strong alkalis, possible viruses are eliminated (1,12).

Sterilization of these materials is achieved by gamma radiation. These solvents eliminate especially Creutzfeld-Jacob Disease, HIV and hepatitis viruses. During these processes minimal loss occurs in osteoconductive proteins and, while they are almost preserved, recovery of the graft takes place by means of osteoinduction and osteoconduction. Depending on the size of the defect, the graft is totally resorbed within a maximum of 1.5 years and replaced by mature bone tissue. Since dehydration with solvents suppresses many infective agents, such graft materials are advantageous (8,12).

Soft tissue grafts are dehydrated with solvents too. Duramater was the first to be introduced, in 1973. This was followed by fascia lata in 1980, which is convenient for cases in which a thinner material is needed. Fascia temporalis is the thinnest one and pericard grafts, which are highly collagenous, are preferred in regions in which stability is needed. These grafts are resorbed within a maximum of 3 months depending on their sizes. The

defects are filled with normal connective tissue. This resorption takes place by enzyme activation. It is also known that these materials stimulate the formation of supportive connective tissue and increase the healing potential of the defect. It takes 3-4 weeks for the regenerative cells to accumulate in surgically created wound areas. Since resorption of fascia temporalis takes 3-4 weeks, it maintains an adequate period for these cells to complete their migration (2,8,12).

In the radiological examinations 6 and 12 months after surgery it was found that new bone formation and the trabecular structure in groups D1 and D2 occurred earlier than in D3.

This study indicates that solvent-dehydrated bone and soft tissue grafts are effective in bone healing. SDSBC alone and with SDFT maintained earlier bone generation in the defects than in the defects left to heal spontaneously. Migration of the particles can be prevented with a membrane overlying the chips.

Corresponding author:

Hakan H. TÜZ

Department of Oral and Maxillofacial Surgery

Faculty of Dentistry, Kırıkkale University,

71100 Kırıkkale - Turkey

e-mail: tuzhakan@hotmail.com

References

1. Akal ÜK, Cambazoğlu M. Use of spongy bone chips dehydrated with solvents on those bone defects occurred as a result of cystectomy, curettage of chronic infection zones and apical resection operations. *Journal of AÜ Faculty of Dentistry*, 22: 103-108, 1995.
2. Akal ÜK, Cehiz T, Şahin M. İki farklı kemik greft materyali ve kollajen membranın kıyaslanması: klinik ve densitometrik çalışma. *Türk Oral ve Maksillofasiyal Cerrahi Dergisi* 6: 35-45, 2002.
3. Aydoğan S, Keskin A, Alkan A, et al. Augmentation of alveolar crests with hydroxylapatite in a vicryl tube. (Preliminary Declaration) *Scientific Journal of Turkish Clinical Dentistry* 4: 61-64, 1998.
4. Kişniççi RŞ, Yaman Z, Akal ÜK, et al. Secondary bone grafting of residual alveoli gaps. *Journal of AÜ Faculty of Dentistry* 21: 213-218, 1994.
5. Pikos MA. Maxillary sinus membrane repair: report of a technique for large perforations. *Implant Dent* 8: 29-34, 1999.
6. Perrott DH, Smith RA, Kaban LB. The use of fresh frozen allogenic bone for maxillary and mandibular reconstruction. *Int J Oral Maxillofac Surg* 21: 260-5, 1992.
7. Becker J, Neukam FW, Schliephake H. Restoration of the lateral sinus wall using a collagen type I membrane for guided tissue regeneration. *Int J Oral Maxillofac Surg* 21: 243-6, 1992.
8. Behbehani AA, Eichner E. Experiences with solvent-dried fascia lata in surgical interventions in otorhinolaryngology. *Laryngol Rhinol Otol (Stuttgart)* 62: 548-51, 1983.
9. Cheung LK, Samman N, Chow TW, et al. A bone graft condensing syringe system maxillofacial reconstructive surgery. *Br J Oral Maxillofac Surg* 35: 267-70, 1997.
10. Dupoirieux L, Pourquier D, Picot MC, et al. Comparative study of three different membranes for guided bone regeneration of rat cranial defects. *Int J Oral Maxillofac Surg* 30: 58-62, 2001.

11. Elshall EE, Inokuchi T, Yoshida S, et al. A comparative study of epithelialization of subcutaneous fascial flaps and muscle-only flaps in the oral cavity. A rabbit model. *Int J Oral Maxillofac Surg* 27: 141-8, 1988.
12. Hinton R, Jinnah RH, Johnson C, et al. A biomechanical analysis of solvent-dehydrated and freeze-dried human fascia lata allografts. A preliminary report. *Am J Sports Med* 20: 607-12, 1992.
13. Hurzeler MB, Kohal RJ, Nagshbandi J, et al. Evaluation of a new bioresorbable barrier to facilitate guided bone regeneration around exposed implant threads. An experimental study in the monkey. *Int J Oral Maxillofac Surg* 27: 315-20, 1998.
14. Mundell RD, Mooney MP, Siegel MI, et al. Osseous guided tissue regeneration using a collagen barrier membrane. *J Oral Maxillofac Surg* 51: 1004-1012, 1993.
15. Sheldon LN. Guided tissue regeneration. *Dent Today* 11: 72-3, 1992.
16. Cohen ES. Guided tissue regeneration in combination with demineralized freeze-dried bone allograft using a nonresorbable membrane. *Compend Contin Edu Dent* 16: 846-842, 1995.
17. Schmelzeisen R, Schon R. Microvascular reanastomosed allogeneous iliac crest transplants for the reconstruction of bony defects of the mandible in miniature pigs. *Int J Oral Maxillofac Surg* 27:377-85, 1998.
18. Solheim E, Pinholt EM, Bang G, et al. Regeneration of calvarial defects by a composite of bioerodible polyorthoester and demineralized bone in rats. *J Neurosurg* 76: 275-279, 1992.
19. Hsu M, Umeda H, Nishijima K. An experimental study of the osteogenicity of free periosteal allografts with cyclosporine. A administration. *Int J Oral Maxillofac Surg* 21: 178-82, 1992.
20. Viljanen VV, Lindholm TC, Gao TJ, et al. Low dosage of native allogenic bone morphogenetic protein in repair of sheep calvarial defects. *Int J Oral Maxillofac Surg* 26: 389-93, 1997.
21. American Association of Tissue Banks: Standards for Tissue Banking, September, 1995.