

## Evaluation of Pulsed Electromagnetic Fields on Bone Healing After Implant Placement in the Rabbit Mandibular Model

Jülide ÖZEN<sup>1</sup>, Arzu ATAY<sup>1</sup>, Selçuk ORUÇ<sup>2</sup>, Mehmet DALKIZ<sup>1</sup>, Bedri BEYDEMİR<sup>1</sup>, Salih DEVELİ<sup>3</sup>

<sup>1</sup>Department of Prosthetic Dentistry, Dental Sciences Center, Gülhane Military Medical Academy, Ankara - Turkey

<sup>2</sup>Department of Prosthetic Dentistry, Dental Sciences Center, Gülhane Military Medical Academy, Haydarpaşa, İstanbul - Turkey

<sup>3</sup>Department of Pathology, Gülhane Military Medical Academy, Ankara - Turkey

Received: November 03, 2003

**Abstract:** Although bone healing around titanium implants has already been evaluated, the effect of pulsed electromagnetic fields (PEMF) during the period of bone maturation around titanium dental implants has not yet been investigated. The aim of this study was to evaluate the effects of PEMFs on bone formation following the insertion of titanium-dental implants in the rabbit mandibular model.

Ti-6Al-4V (Sulzer Calcitek, California, USA) dental implants were inserted into the mandibulae of 28 New Zealand rabbits (6 weeks old). Fourteen were stimulated with PEMFs for 2 consecutive weeks, 4 h/day, at a magnetic intensity of 0.2 milli Tesla (mT), while the other 4 animals were not treated (control group). The rabbits were sacrificed at 2 and 8 weeks (after 6 weeks of non-stimulation) for histopathologic analysis around the implants.

No significant difference in bone osteoblastic activity, new trabecular bone and fibrous tissue formation were observed between the control and the PEMF treated groups. However, significant differences in bone osteoblastic activity and new trabecular bone formation were observed between the control group and the PEMF treated group at week 8 ( $p < 0,001$ ). These results indicate that PEMF had an effect on the bone inductive properties in the area surrounding the implant.

**Key Words:** Electromagnetic field, implant, bone healing

### Introduction

In the past decade dental implants have become a reliable method of tooth replacement in dentistry. One of the goals of dental implantology is to achieve good and fast osseointegration between implants and bone (1). The success of osseointegration depends on the state of the host bone and its healing capacity (2,3). However, the healing process after bone-implant integration takes a long time and may cause dissatisfaction in some patients.

Pulsed electromagnetic fields (PEMFs) are widely used to promote bone healing of orthopaedic treatment (4-8). The clinical use of electric and electromagnetic fields for bone healing applications began in the early 1970s. Since then, several technologies have been developed and shown to promote wound and fracture healing (8,9). However, few studies have investigated the effect of PEMFs on bone healing in oral implantology (10,11).

The purpose of this study was to investigate the use of PEMFs in the rabbit model and to evaluate their efficiency after placing implants into the mandibula.

### Materials and Methods

Twenty-eight New Zealand adult male rabbits of the same age and non-coated titanium alloy (Ti-6Al-4V) (Sulzer Calcitek, California, USA) were used for the experiment. This study was carried out according to the Gülhane Military Medicine Academy (GATA) guidelines for the use of experimental animals. The experimental design is summarized in Figure 1.

Ti-6Al-4V alloys were manufactured 3.0 mm long, 1.0 mm wide and 0.5 mm high. Prior to implantation, the implant materials were sterilized according to the proposals of Standford et al. (12). General anesthesia

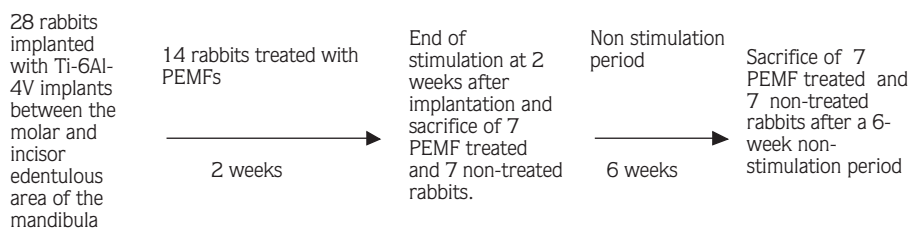


Figure 1. Experimental design: see the text for a detailed description.

was induced by i.m. injection of 35 mg/kg of Ketamine (Ege-Vet, İstanbul, Turkey) and 5 mg/kg of Xylazine (Drogsan, İstanbul, Turkey). Surgery was performed in aseptic conditions. A hole was prepared in accordance with the implant size between the molar and incisor edentulous area of the mandibula. The implants were placed into that area in the same position and direction wherever possible. On the first postoperative day, the animals were randomly divided into 2 groups. Fourteen animals were exposed to PEMFs (4 h day for 2 consecutive weeks) and 14 animals were non-treated (control group): 2 and 8 weeks after implantation, the animals were pharmacologically euthanized under general anesthesia. Mandibula including the implant material, were removed for histological evaluation.

#### PEMF Generator

Electromagnetic stimulators generating a PEMF were produced by the GATA biomedical department. A PEMF generator system includes a timing-control circuit for controlling the frequency and duration of the pulse, coil interface circuits for triggering the coil and a coil component. Ten coils and coil interface circuits were produced for testing on rabbits. In this system, it is possible to adjust the frequency and duration of pulses for various applications. The frequency, magnetic field intensity and the duration of pulses used in the tests were 100 Hz, 0.2 mT ( $10^4$  Gauss = 1 Tesla) and 25 microseconds ( $\mu$ s), respectively (7). Each rabbit was held in a fixed position during stimulation (Figure 2).

#### Histological Procedures

The sections excised from the mandibulae were fixed in 10% formaldehyde for 24 and decalcified in formic acid solution for 5-7 days. After decalcification, the area which the implant was located was longitudinally divided into 2 halves: the labial and lingual. The sections were

processed using routine histological techniques and then embedded in paraffin. The paraffin blocks were sectioned serially at 4-6  $\mu$ m and stained with hematoxylin and eosin. Osteoblast cell numbers were determined twice by 2 pathologists, at different times, on the stained sections using a light microscope (Shinagawa-ku, Tokyo, Japan). At the same experimental period, trabecular bone and fibrous tissue formation were observed in the same area.

Statistical analysis was performed by using SPSS 10.0 software (SPSS FW, Chicago, USA). The Mann-Whitney U test was used to compare the treated and control groups. The results reported here are means and standard errors for each group.

#### Results

No operative or postoperative complications were encountered. The statistical results for each experimental group are summarized in the Table. There was no significant difference in osteoblast cell numbers and layers of trabecular bone between the control group and the treated group at week 2. However, labial and lingual

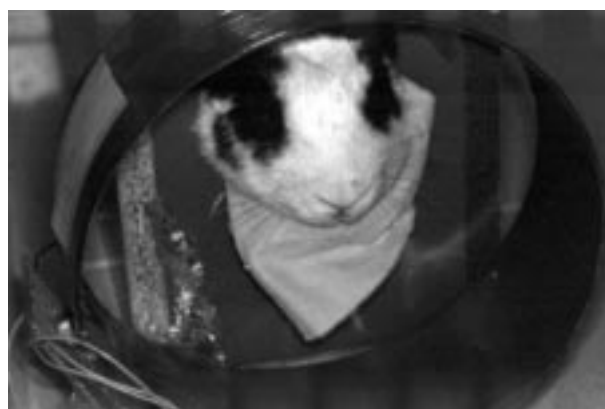

Figure 2. Diagram of the PEMF generator used for treating the rabbit mandibula.

Table. Results of the statistical analysis of the histologic scores.

Histological sections (Labial and lingual)	Control Group	Treated Group	P
	Mean $\pm$ SD N = 7	Mean $\pm$ SD N = 7	
Osteoblast Labial (2 week)	9.85 $\pm$ 1.46	11.42 $\pm$ 1.39	0.097
Osteoblast Lingual (2 week)	9.57 $\pm$ 4,15	11.00 $\pm$ 1.52	0.209
Osteoblast Labial (8 week)	12.57 $\pm$ 1.27	30.85 $\pm$ 7.26	<0.001
Osteoblast Lingual (8 week)	9.14 $\pm$ 3.76	30.28 $\pm$ 6.75	<0.001
Trabecular bone Labial (2 week)	6.42 $\pm$ 2.43	9.85 $\pm$ 3.02	0.053
Trabecular bone Lingual (2 week)	5.85 $\pm$ 1.57	7.71 $\pm$ 1.97	0.073
Trabecular bone Labial (8week)	6.42 $\pm$ 0.97	32.28 $\pm$ 5.52	<0.001
Trabecular bone Lingual (8 week)	5.85 $\pm$ 1.34	31.28 $\pm$ 5.43	<0.001
Fibrous tissue Labial (2 week)	3.28 $\pm$ 1.79	3.28 $\pm$ 1.97	0.0902
Fibrous tissue Lingual (2 week)	2.71 $\pm$ 1.38	3.14 $\pm$ 1.67	0.710
Fibrous tissue Labial (8 week)	1.20 $\pm$ 3.18	2.71 $\pm$ 2.05	0.383
Fibrous tissue Lingual (8 week)	2.71 $\pm$ 2.28	2.00 $\pm$ 1.82	0.535

osteoblast cell numbers increased significantly from week 2 onwards in the PEMF treated group (Figures 3a, b). The greatest osteoblast cell numbers and a thick layer of trabecular bone were observed in the week 8 after the PEMF treatment. No significant difference in fibrous tissue formation was observed between the control and the treated group at 2 and 8 weeks after implantation (Figure 3c).

The histological appearances of PEMF treated animals at 8 weeks are reported in Figure 4. The area surrounding the implant, the newly formed osteoblastic cell and the layer of trabecular bone were in close contact with the implant surface in PEMF treated animals. Moreover, the layer of trabecular bone was denser in this group. At the same experimental time, no bone ingrowth was observed in any regions in the control animals.

## Discussion

Electromagnetic stimulation is known to promote osteogenesis activity and several studies have demonstrated its clinical effects (6,13). However, the effects vary according to the stimulation conditions. There is still a controversy about PEMF treatment. Inconsistencies in the protocols used by different investigators make it difficult to choose one PEMF regimen over another (11). Ijiri et al. (14) showed that

stimulation for 10 h/day promoted a greater degree of bone formation than stimulation for 5 h/day. The results of Matsumoto et al. (11) did not show a significant difference between femurs treated with PEMF for 4 h/day and those treated for 8 h/day. However, Ijiri et al. (13) reported that the amount of bone ingrowth to the implant was dependent a duration of stimulation. In our study, we selected an optimal electromagnetic power of 0.2 mT and 4 h/day, which were employed in the PEMF procedure (13).

Animal studies an PEMFs demonstrate the beneficial effect of PEMFs on various aspects of bone healing. Yonemori et al. (15) reported that intramedullary new bone formation and the proliferative activity of osteoblasts were significantly higher in the direct current stimulation group than in the other groups. Similarly, Landry et al. (6) demonstrated that PEMFs can stimulate proliferation of osteoblasts in vitro. Our results are consistent with those of Landry et al. (6) and Yonemori et al. (15).

The effects of PEMF in oral implantology following implant placement have recently been reported (10,11,13). However, there are no certain data about bone healing after the placement of titanium implants. Buzza et al. (10) observed that PEMF stimulation does not improve the bone healing process around commercially pure dental implants in tibiae. The other

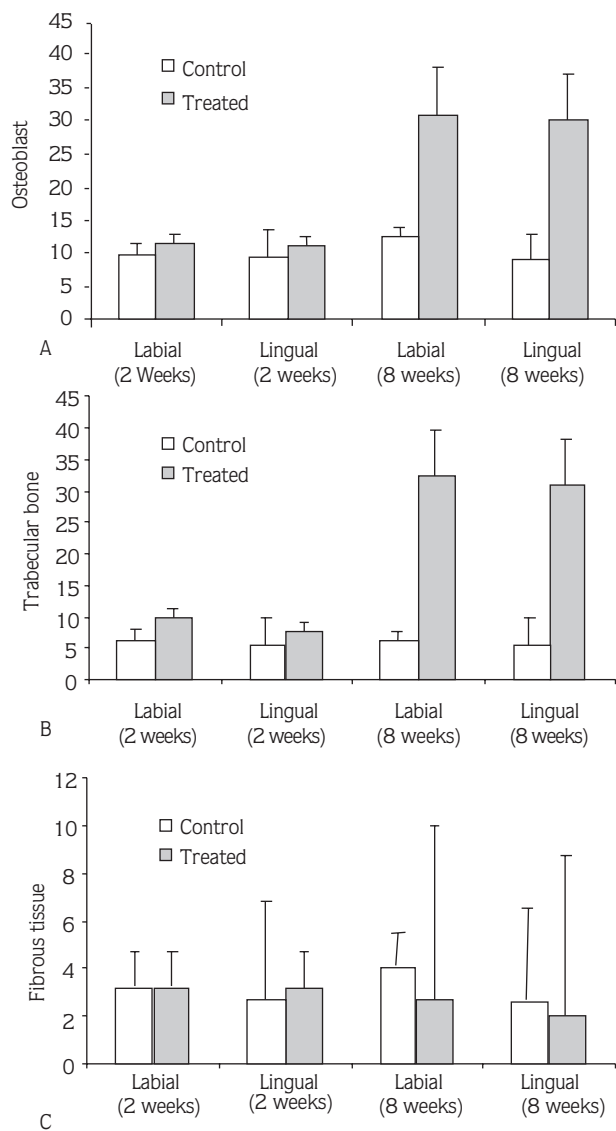


Figure 3. Histological scores comparison between the control and treatment groups for labial and lingual surfaces at 2 and 8 weeks. A; osteoblast, B; trabecular bone C; fibrous tissue

hand Matsumoto et al. (11) showed that PEMF stimulation promotes bone formation around rough-surfaced implants in the rabbit femur. Our results demonstrated that the highest amount of new bone formation was observed 8 weeks after stimulation in the PEMF treated group. This is in agreement with Matsumoto et al. (11). Our results, however, did not show any fibrous tissue formation differences between the treated and control groups.

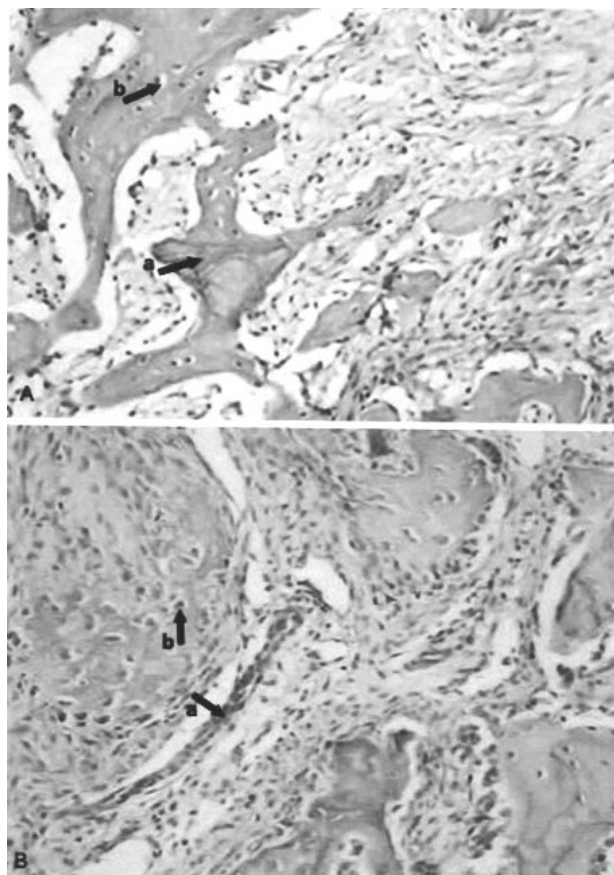


Figure 4. A, Histologically trabecular bone formation and osteoblasts were obtained at 8 weeks in the control group. B, Histologically, a high rate of osteoblastic cells and new trabecular bone formation was obtained at 8 weeks in the PEMF treated group (Hematoxylin and eosin stained x 200). a: Trabecular bone b: Osteoblast.

These results suggest that PEMF stimulation may positively affect the bone healing process after implant placement. Therefore, its clinical effects should be investigated in the future.

*Corresponding author:*  
 Jülide ÖZEN  
 Mebus Evleri İller sok.  
 06580 Tandoğan, Ankara - Turkey  
 e-mail: julideozen@yahoo.com

## References

1. LeGeros RZ, Craig RG. Strategies to affect bone remodelling: osteointegration. *J Bone Miner Res* 8 Suppl 2: 583-96, 1993.
2. Fujimoto T, Niimi A, Nakai H, et al. Osseointegrated implants in a patient with osteoporosis: a case report. *Int J Oral Maxillofac Implants* 11: 539-42, 1996.
3. Motohashi M, Shirota T, Tokugawa Y, et al. Bone reactions around hydroxyapatite-coated implants in ovariectomized rats. *Oral Surg Oral Med Oral Pathol Oral Radiol Endod* 87: 145-52, 1999.
4. Fontanesi G, Dal MA, Rinaldi E, et al. The effect of low frequency pulsing of an electromagnetic field for the treatment of congenital and acquired pseudoarthroses. *J Bioelectricity* 3: 155-75, 1984.
5. McDonald F. Electrical effects at the bone surface. *Eur J Orthod* 15: 175-83, 1993.
6. Landry PS, Sadasivan KK, Marino AA, et al. Electromagnetic fields can affect osteogenesis by increasing the rate of differentiation. *Clin Orthop* 338: 262-70, 1997.
7. Pezzetti F, DeMattei M, Caruso A, Cadossi R, et al. Effects of pulsed electromagnetic fields on human chondrocytes: an in vitro study. *Calcif Tissue Int* 65: 396-401, 1999.
8. Ryaby JT. Clinical effects of electromagnetic and electric fields on fracture healing. *Clin Orthop* (355 Suppl): 205-15, 1998.
9. Qjingwa JC, Isseroff RR. Electrical stimulation of wound healing. *J Invest Dermatol* 121: 1-12, 2003.
10. Buzza EP, Shibli JA, Barbeiro RH, et al. Effects of electromagnetic field on bone healing around commercially pure titanium surface: histologic and mechanical study in rabbits. *Implant Dent* 12: 182-87, 2003.
11. Matsumoto H, Ochi M, Abiko Y, et al. Pulsed electromagnetic fields promote bone formation around dental implants inserted into the femur of rabbits. *Clin Oral Implants Res* 11: 354-60, 2000.
12. Stanford CM, Keller, JC, Solursh M. Bone cell expression on titanium surfaces is altered by sterilization treatments. *J Dent Res* 73:1061-71, 1994.
13. Matsunaga S, Ijiri K, Sakou T, et al. Immunohistochemical study of activating osteoblasts from undifferentiated mesenchymal cells by electrical stimulation. *Bone* 14: 327-32, 1993.
14. Ijiri K, Matsunaga S, Fukuyama K, et al. The effect of pulsing electromagnetic field on bone ingrowth into a porous coated implant. *Anticancer Res* 16: 2853-59, 1996.
15. Yonemori K, Matsunaga S, Ishidou Y, et al. Early effects of electrical stimulation on osteogenesis. *Bone* 19: 173-80, 1996.