

SHORT REPORT

Atypical Microtia Correction with Multiple Z-Plasties

Safvet ÖRS¹, Galip K. GÜNAY²

¹Department of Plastic Surgery, Güneş Hospital, Kayseri - Turkey

²Department of Plastic Surgery, Faculty of Medicine, Erciyes University, Kayseri - Turkey

Received: June 30, 2003

Key Words: Microtia, Z-plasties, Auricular anomalies

Microtia is a congenital malformation characterized by total or partial absence of the whole auricle or any of its components, varying from a small auricle to total absence (anotia). There may be associated atresia of the external auditory meatus. The most common microtia, 60% of total cases, is the lobule type. The others are the small concha with lobule type (10%), scapha type without concha (9%), and the lobule type and concha type of the first and second branchial arch syndrome (4% and 5%, respectively). Facial palsy of the eyelid or lip is observed in 10.4%, especially in particular types such as the concha type of the first and second branchial syndrome or the concha only type (1). The frequency varies in different parts of the world between 0.4 and 5.5/10,000 newborns (2). The unilateral form is present in 81.5% of cases, most frequently on the right side. Sixty-three percent of those affected are males: 47.4% of cases are isolated malformation and 52.6% are associated with other malformations (2). There are several methods suggested by different authors for the lobule type (3-5). However, there is still no commonly accepted standard method for the other types. Here we present a case of atypical microtia with normally shaped concha and lobule that cannot be classified by Fukuda's classification, and describe an alternative method for the treatment of congenital atypical microtia using multiple Z-plasties.

Case report

A 6-year-old boy was admitted for right prominent ear and left microtia (Figure 1). The lobule and helix of the left ear were intact. Vertically the length of the left ear was approximately the same as that of the right ear, whereas the transverse length was 20% shorter. Periphery and upper part of the conchal cavity were covered by cartilage and skin web. There was a fissure straight to the conchal cavity over the web. An operation was carried out to correct this atypical case with small scapha and the atresia of the ear canal and the undeveloped antihelix and tragus. The right prominent ear was also repaired at the same time. On the left ear, 2 Z-plasties were performed above and below the anterior side. A double opposing Z-plasty was performed on the posterior side. Two Z-plasties were performed on the apex and the base of the web (Figure 2). All Z-plasties were limited to the skin. After the Z-plasty flaps were lifted, the remaining conchal cartilage was sliced full thickness from the center of the concha to the periphery. Maintaining a distance of 5 mm from the distal side, each cartilage segment was fixed to the base of the concha with permanent sutures. Cartilage grafts were placed in front of the sutures. These grafts formed an antihelix. Tragus was formed with a piece of cartilage at the center of the 2 Z-plasties at the anterior side. After suturing the flaps, the operation was completed. The tragus, concha

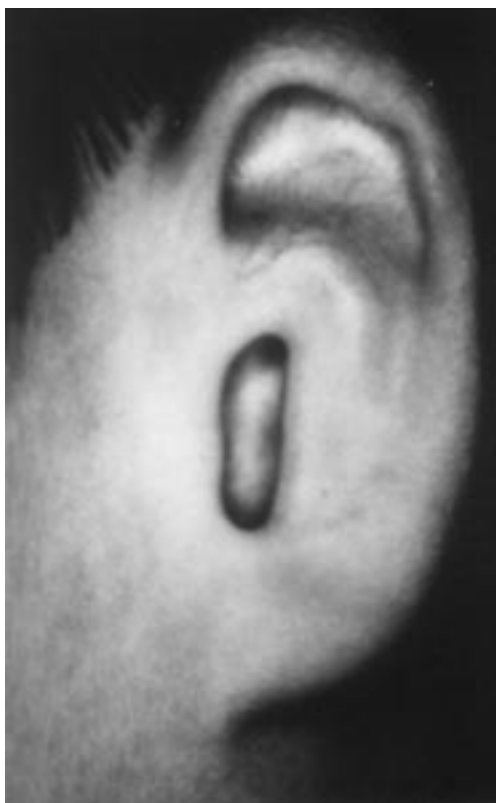

Figure 1. Patient with left atypical microtia.

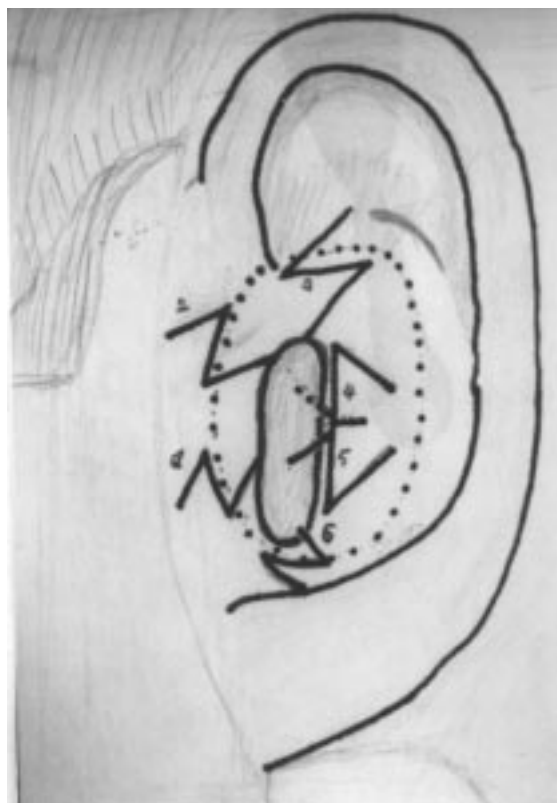


Figure 2. Appearance of multiple Z-plasties

scapha, antihelix, and triangular fossa were well defined after this operation. This was followed up for 3 years in the postoperative period. After this long period all components continued to be well defined in the left ear (Figure 3).

The standard method with acceptable results for the correction of classic lobule type microtia (3-5) is well described in the literature. With regard to concha-type microtia, scapha-type microtia, severely constricted ear, or even total earlobe defect, numerous corrective methods for each defect have been introduced (2,6-9). Atypical auricular deformities are more difficult to correct than classic ones. The amount and shape of the skin and cartilage within the auricular remnant are different in each case. A patient with a sizable auricular remnant expects better results than one with a smaller remnant of lobule-type microtia. Concha-type and scapha-type microtia are representative of deformity requiring construction of the upper and middle auricles. If the difference is similar to the size of the concha of the normal auricle, the framework is constructed with a combination of contralateral conchal cartilage and costa

cartilage or with a combination of contralateral conchal cartilage and septal cartilage (10). In middle and upper auricular deformities, such as concha-type or scapha-type microtia, a cranially based postauricular skin flap and lower mastoid fascial flap are covered over the framework (10). For upper auricular deformities, such as microtia representing lop-ear deformity (10), a narrow cranially based postauricular skin flap (Grotting) (11) and upper mastoid fascial flap are used (11). For lower auricular deformities, such as total absence of the ear lobe, a cranially based skin flap and lower mastoid fascial are utilized. Two kinds of cranially based postauricular skin flaps have been reported in the literature. Grotting (11) used a narrow cranially based postauricular skin flap for the correction of small upper auricular defects. Crikelair (12) used a broader cranially based postauricular skin flap for moderate size upper auricular defects. For the correction of concha-type or scapha type microtia, most surgeons use methods of framework fabrication similar to the methods they use for lobule-type microtia. Fukuda and Yamada (1), Brent (3,4) and Nagata (5,8,9) presented their methods of manipulating

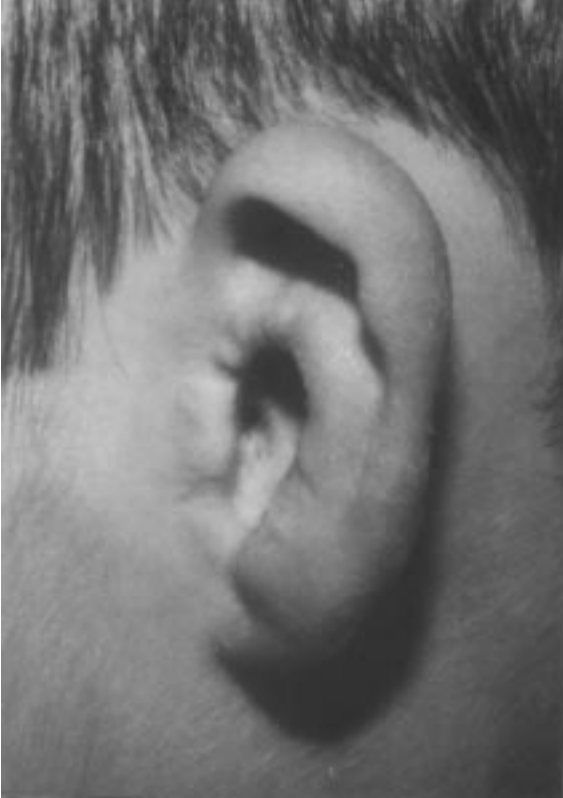

Figure 3. Overall lateral view of the constructed ear 3 years postoperation.

the remnant cartilage in their framework fabrication. All techniques may result in conspicuous long scars in the infraauricular, retroauricular and donor regions. There are many complications attendant upon auricle reconstruction, such as flap necrosis, infections, and

deformation of the cartilage framework. Methods of atypical microtia reconstruction are different in each case. The Z-plasty principle can be used to increase the length of the skin in the desired direction. For example, it is useful for releasing scar contractures, especially in cosmetically sensitive areas, for breaking up the appearance of a straight line, or for releasing a contracture. Congenital skin webs (without auricle) can also be corrected with Z-plasties (13). Circumferential scars are amenable to lengthening using Z-plasties, especially in constricting bands at the extremities. The lobule and external auditory atresia can be corrected with Z-plasties in microtia (13,14). Except for these 2 anomalies, Z-plasty has not been used in microtia before. In our case, the results from the Z-plasties seem excellent. Deformation of the cartilage framework and auricle can develop in reconstructed microtia over long periods. However, no deformation developed in our case at the end of the third postoperative year. In conclusion, this microtia reconstruction method is simple and safe and does not contain any donor side morbidity. To the best of our knowledge, no similar case has been reported previously.

Corresponding author:

Safvet ÖRS

Yıldırım Beyazıt Mah.

M. Şimşek Cad. Manolya Apt. No: 119/9

38030 Kayseri - TURKEY

E-mail: safvet@erciyes.edu.tr

References

1. Fukuda O, Yamada A. Reconstruction of the microtic ear with autogenous cartilage. *Clin Plast Surg* 5: 351, 1978.
2. Sanchez O, Mendez JR, Gomez E et al. Clinico-epidemiologic study of microtia. *Invest Clin* 38: 203, 1997.
3. Brent B. The correction of the microtia with autogenous cartilage grafts: I. The classic deformity. *Plast Reconstr Surg* 66: 1, 1980.
4. Brent B. Auricular repair with autogenous rib cartilage grafts: two decades of experience with 600 cases. *Plast Reconstr Surg* 90: 355, 1992.
5. Nagata S. Modification of the stage in total reconstruction of auricle: I. Grafting the three-dimensional costal cartilage framework for lobule-type microtia. *Plast Reconstr Surg* 93: 221, 1994.
6. Tanzer R.C. The constricted (cup and lop) ear. *Plast Reconstr Surg* 55: 406, 1975.
7. Brent B. The correction of microtia with autogenous rib cartilage grafts: II. Atypical and complex deformities. *Plast Reconstr Surg* 66: 13, 1980.
8. Nagata S. Modification of the stages in total reconstruction of the auricle: II. Grafting the three-dimensional costal cartilage framework for concha type microtia. *Plast Reconstr Surg* 93: 231, 1994.
9. Nagata S. Modification of the stages in total reconstruction of the auricle: III. Grafting the three-dimensional costal cartilage framework for small concha type microtia. *Plast Reconstr Surg* 93: 243, 1994.

10. Park C. Modification of two-flap method and framework construction for reconstruction of atypical congenital auricular deformities. *Plast Reconstr Surg* 99: 1846, 1997.
11. Grotting JK. Otoplasty for congenital cupped protruding ears using a postauricular flap. *Plast Reconstr Surg* 22: 164, 1958.
12. Crikelair G.F. A method of partial ear reconstruction for avulsion of the upper portion of the ear. *Plast Reconstr Surg* 17: 438, 1956.
13. Place MJ, Herber SC, Hardesty RA. Basic techniques and principles in plastic surgery. *Grabb and Smith's Plastic Surgery* (Eds. Aston SJ, Beasley RW, Thorne CHM). Lippincott-Raven, Philadelphia, New York, 1997, pp: 13-25.
14. Fagan P, Ajan M. Z-Meatoplasty of the external auditory canal. *Laryngoscope* 108: 1421, 1998.