

Nihal KILINÇ
Ahmet YALINKAYA
Mehmet ÖZAYDIN

Nondecidualized and Decidualized Endometriosis of the Abdominal Wall (A Report of Two Cases Secondary to Cesarean Section)

Department of Pathology, Faculty of Medicine,
Dicle University, Diyarbakır - TURKEY

Received: May 28, 2002

Key Words: Scar endometriosis, cesarian
section, cutaneous, episiotomy.

Endometriosis is a common phenomenon (1). It involves functioning endometrial tissue outside the uterine cavity (2). Spontaneous cutaneous endometriosis is limited to the umbilicus and inguinal area (3). In other locations, such as the lower abdominal wall, it practically always arises in surgical scars (particularly those from caesarean sections) (3). Most reported cases of cutaneous endometriosis have occurred within scars or, rarely, within needle tracts; the remainder are spontaneous (4). It occurs in a variety of locations both within and outside of the peritoneal cavity. The most common locations are within the pelvis, including the ovaries, uterine ligaments, the rectovaginal septum, and peritoneum. Unusual sites of endometriosis outside the pelvis have been reported, including the intestine, appendix, bladder and skin (scar, umbilicus, perineum, inguinal region) (4). When symptomatic, endometriosis of the abdominal wall, inguinal region, or surgical scar is difficult to diagnose; it is often confused with other pathologic conditions such as suture granuloma, abscess, hernia, lipoma, and primary or metastatic cancer (5).

We describe two cases secondary to cesarean section of nondecidualized and decidualized endometriosis of the abdominal wall and a review of the literature.

Case 1

A 34-year-old G2P2 woman complained of a polypoid, brown-blue nodule, pruritus and erythema at the surgical scar level following cesarean section present for about 1 year. The patient revealed pain, tenderness in a mass with a typical history

of monthly bleeding from the surgical scar. Her menstruation periods were regular. The preoperative diagnosis was skin tumor.

On physical examination, there was a 4 cm severe hard mass in the surgical scar. It was immobile, firm on palpation and did not bleed on manipulation. The rest of the abdominal wall and systemic examination were normal. She only underwent preoperative ultrasound, which did not specifically aid in diagnosis. The gross appearance of the specimen was 5 x 3 x 2 cm covered by normal skin and with a brownish-gray irregular cut surface. Microscopy showed decidualized endometrium, consisting of decidual cell nodules and glandular spaces beneath the normal epidermis within the dermis (Figure 1). The histologic diagnosis was decidualized cutaneous cesarean scar endometriosis. The previous symptoms disappeared after surgical excision. There were no complications or recurrence.

Case 2

A 24-year-old woman presented with a steadily growing, firm, tender, painful, subcutaneous mass that had appeared shortly after cesarean section 2 years previously. The patient had not had preoperative radiologic studies or ultrasound. The subcutaneous nodule caused cyclic pain and swelling. Histologic examination and gross appearance of the mass, which measured 6 x 4 x 3 cm, showed nondecidualized endometrial tissue between fibrocollagen tissue. It was immobile, slightly tender on palpation and did not bleed on manipulation. The mass was located in the surgical

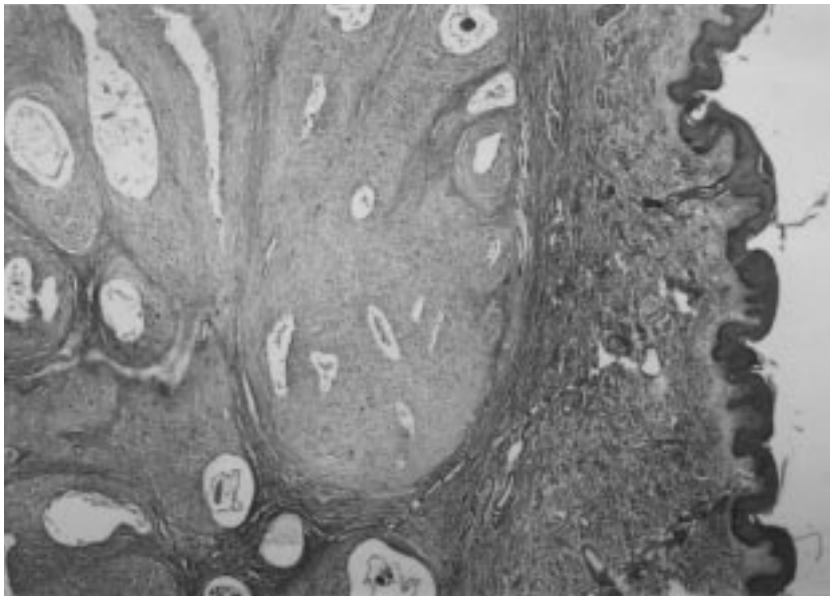


Figure 1. Decidualized endometrium, consisting of decidual cell nodules and glandular spaces are seen beneath normal epidermis within dermis (HE, x25).

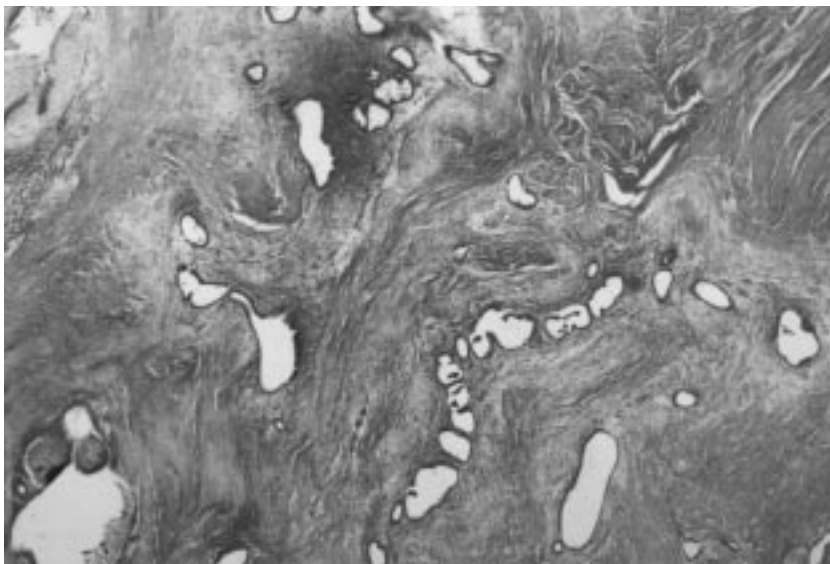


Figure 2. Irregular endometrial glands with associated stromal cells among fibrocollagen (HE, x25).

scar on the abdominal wall after cesarean section. The preoperative diagnosis was endometriosis. Gynecological examination was normal. Microscopy showed irregular endometrial glands embedded within the fibrocollagen stroma, with fibrosis and pseudoinfiltration of the fascia. This case demonstrates nondecidualized cutaneous scar endometriosis. There was no evidence of recurrence of the lump or pain 12 months after surgical excision.

Endometriosis is defined as the presence of endometrial glands and stroma outside the endometrium and myometrium. Usually both epithelium and stroma are seen, but occasionally the diagnosis of endometriosis can be made when only one component is present (4).

Endometriosis has been described in most parts of the body. The disease can be present in women of reproductive age in the umbilicus or groin without antecedent surgery. When present in other cutaneous sites, there is nearly always an associated surgical scar (6,7). It is thought to occur in 1% to 7% of women in the United States (8). The origin of endometriosis is unknown, but there are several theories to explain the pathogenesis of endometriosis: vascular or lymphatic dissemination, tubal regurgitation, an abnormal differentiation of certain areas of celomic epithelium, and direct extension along the round ligament from a neighboring process in the pelvis (9).

Cutaneous endometriosis is an infrequent pathology whose etiopathogenesis is still uncertain, usually appearing in surgical scars or following surgical treatment of the uterus or fallopian tubes (10). Cutaneous endometriosis is characterized by the presence of extrauterine endometrial tissue in or under the skin (11). The most common symptoms are those relating to a cutaneous mass or nodule that, in scar-related cases, appears weeks to years after surgery; the average postoperative interval in one study was 30 months (4). Multiparous women in the third decade of life were most frequently affected (12).

The mechanism of endometriosis occurring in the cesarean scar is felt to be secondary to iatrogenic transplantation of endometrium or extrauterine decidual tissue into the incision during the cesarean section. Although endometriosis does occur in laparotomy scars, scar endometriosis is most frequently seen after operations in which the uterus is opened.

Bottino et al. (13) described two cases of cutaneous endometriosis in correspondence with the surgical scar following cesarean section. The cases formed part of a series of 500 abdominal operations performed during the period 1988-89, of which about 200 were cesarean sections, with a 1% frequency. The results were in line with the hypothesis regarding the spread of endometrial tissue during surgery and with that concerning peritoneal metaplasia.

On occasions, the process is composed almost exclusively of endometrial stroma and may be confused with a neoplasm (5). A case of cesarean scar endometriosis with massive decidualization was presented (6). The 25-year-old patient had an extensive, ulcerated lesion that mimicked malignancy microscopically due to myxoid change with alveolar patterns reminiscent of some soft tissue sarcomas, and pseudoinfiltration of the fascia. This histologic pseudomalignancy is not common and can be misinterpreted as metastatic malignancy by dermatopathologists not familiar with gynecological pathology. In some instances the pathologist is simply not familiar with the lesion (7).

Marked hemorrhage or decidual changes in endometrial tissue outside may render recognition difficult and lead to an overdiagnosis of malignancy (6,7).

Our first case had a decidualized endometriosis microscopic appearance.

Chatterjee (12) reported that out of 17 cases of scar endometriosis studied over a 5-year period 71% of the cases followed abdominal hysterotomy, for a 1.08% incidence of scar endometriosis in the patients who underwent hysterotomy during this period. The most common symptom was painful swelling of the scar, which waxed and waned with menses. The majority of patients presented 1 to 2 years after the precipitating operation. Associated pelvic endometriosis was present in 24% of patients. Neither of our patients with nondecidualized and decidualized endometriosis of the abdominal wall following cesarean section had symptoms of pelvic endometriosis; therefore, laparoscopy was not performed.

Surgical scar endometriosis is more common than we realize. A review of the literature revealed 52 reported individual cases of cesarean section scar endometriosis. First reported in 1956, only anecdotal case reports of this entity have been published in the literature (14). Koger et al. (15) reported 24 patients with surgical scar endometriosis. In this series, endometriosis occurred in a cesarean section scar in 19 patients. Daye et al. (16) recorded seven cases of scar endometriosis in Pfannenstiel incision after cesarean section over a 3-year period.

The treatment of endometriosis may be hormonal or surgical depending on the circumstances (17). Surgical excision is sufficient for the treatment of nondecidualized and decidualized endometriosis of the abdominal wall after cesarean section.

In conclusion, our cases with cutaneous endometriosis had surgical trauma. Cutaneous endometriosis is most likely caused by vascular spread induced during the manual revision of the uterine cavity after cesarean section. This may explain the our cases with nondecidualized and decidualized endometriosis of the abdominal wall after cesarean section.

Correspondence author:

Nihal KILINÇ

Department of Pathology

Faculty of Medicine, Dicle University

21280 Diyarbakır - TURKEY

References

1. Michowitz M, Baratz M, Stavorovsky M. Endometriosis of the umbilicus. *Dermatologica* 167 (6): 326-30, 1983.
2. Adamson GD. Diagnosis and clinical presentation of endometriosis. *Am J Obstet Gynecol*. 162: 568-69, 1990.
3. Rosai J. *Acherman's Surgical Pathology* 8th ed. St Louis. The C.V. Mosby Company, New York, p: 196, 1402 1996.
4. Kurman RJ, ed. *Blaustein's pathology of the female genital tract*, 4th ed. Springer-Verlag, New York, p: 660-676, 1994.
5. Brenner C, Wohlgemuth S. Scar endometriosis. *Surg Gynecol Obstet* 170: 538-540, 1990.
6. Pellegrini AE. Cutaneous decidualized endometriosis. A pseudomalignancy. *Am J Dermatopathol* 4: 171-174, 1982.
7. Nogales FF, Martin F, Linares J, Naranjo R, Concha A. Myxoid change in decidualized scar endometriosis mimicking malignancy. *J Cutan Pathol* 20(1): 87-91, 1993.
8. Barbieri RL. Etiology and epidemiology of endometriosis. *Am J Obstet Gynecol* 162: 565-67, 1990.
9. Uzunlar AK, Yilmaz F, Yaldiz M et al. Inguinal endometriosis: a report of two cases and a review of the literature. *Turk J Med Sci* 30:389-92, 2000.
10. Fruscella L, Villani M, Valenzano F, Castagnola D. Endometriosis of the abdominal wall after cesarean section. *Minerva Ginecol* 53(4): 283-7, 2001.
11. Choi SW, Lee HN, Kang SJ, Kim HO. A case of cutaneous endometriosis developed in postmenopausal woman receiving hormonal replacement. *J Am Acad Dermatol* 41: 327-9, 1999.
12. Chatterjee SK. Scar endometriosis: a clinicopathologic study of 17 cases. *Obstet Gynecol* 56(1): 81-4, 1980.
13. Bottino G, Marinello M, Menna C, Torchio B, Vergano R. Endometriosis of the lower abdominal wall. Report of two cases secondary to cesarean section. *Minerva Ginecol* 42(6): 283-5, 1990.
14. Seydel AS, Sichel JZ, Warner ED, Sax HC. Extra pelvic endometriosis: Diagnosis and treatment. *Am J of Surg* 171: 239-41, 1996.
15. Koger KE, Shatney CH, Hodge K, McClenathan JH. Surgical scar endometrioma. *Surg Gynecol Obstet* 177: 243-46, 1993.
16. Daye SS, Barone JE, Lincer RM, et al. Pfannenstiel syndrome. *Am Surg* 59: 459-460, 1993.
17. Lu PY, Org SJ. Endometriosis. Current management. *Mayo Clin Proct* 70: 453-63, 1995.