

Hripsime Artjun BOHCHELIAN¹
Anelia Dimitrova KLISAROVA²
Lidia Asenova KOEVA¹

Radioimmune Imaging of Diabetic Foot Infection - Tc-99m-Labelled Antigranulocyte Antibody in Combination with Tc-99m-Methylene Diphosphonate Bone Scintigraphy

Received: April 04, 2001

Abstract: The aim of this study was to evaluate the clinical efficacy of immunoscintigraphy with Tc-99m-labelled antigranulocyte antibody in combination with Tc-99m-methylene-diphosphonate (MDP) bone scanning in diabetic foot infection. The study group comprised 42 Type 2 diabetics with foot infection. Pre- and postprandial blood glucose level, HbA1c, urinary glucose, microalbuminuria, total cholesterol, LDL-cholesterol, HDL-cholesterol, and bacteriological cultures were analyzed. Investigation of transcutaneous oxygen tension, vibration sensation, electromyography, and Doppler ankle/brachial systolic blood pressure index was carried out. Radiographs centered on the feet were performed. All patients underwent bone scintigraphy with 370 MBq Tc-99m-MDP three hours after injection in 3 projections. Radioimmune planar immunoscintigraphy was performed with 740 MBq Technetium - 99m

conjugated with monoclonal antigranulocyte antibody BW 250/183 in the same three projections. Immunoscintigraphy was performed 4 and 24 hours after administration of 740 MBq Tc-99m-MAB BW 250/183 in positive bone scan cases. Final assessment of immunoscintigraphic images based on parallel analysis of isotopic images and final diagnosis revealed 21 true positive cases, 16 true negative cases, 3 false positive cases, and 2 false negative cases. The analysis of diagnostic validity revealed a diagnostic accuracy of 86 %. Immunoscintigraphy with Tc-99m-labelled antigranulocyte antibody in combination with Tc-99m-MDP bone scanning is an efficient method for the early detection of foot bone infection and the precise diagnosis of osteomyelitis in diabetics.

Key Words: diabetic foot, infection, immunoscintigraphy, bone scintigraphy

Departments of ¹Endocrinology, ²Radiology, Medical University, Varna, BULGARIA

Introduction

Diabetic foot is a common pathology among diabetic complications (1,2). Early diagnosis and effective treatment of diabetic foot infection is essential for prevention of amputation. Adequate diagnosis and treatment of diabetic foot is based on a multidisciplinary and multifactorial approach carried out by a diabetic foot care team (3-8).

Isotopic procedures may be applied as part of the complex diagnostic schedule of diabetic foot infection. Technetium - 99m - methylene diphosphonate (Tc-99m-MDP) bone scanning has high sensitivity, but low specificity for the detection of osteomyelitis. The neuroarthropathy, superimposition of cellulite, and trauma increase non-specifically the uptake of bone tracers. Therefore, several studies have applied labelled leucocytes for the specific detection of diabetic foot infection and osteomyelitis (9-12).

The aim of this study was to evaluate the clinical efficacy of immunoscintigraphy with Tc-99m-labelled antigranulocyte antibody in combination with Tc-99m-MDP bone scanning in diabetic foot infection.

Materials and methods

The study design was that of a longitudinal prospective study including in-patients admitted for diagnosis and treatment in the Clinic of Endocrinology, Medical University, Varna.

Subjects

The study group comprised 42 Type 2 diabetics with possible foot infection. The study was approved by the local ethics committee. Informed consent was obtained from all patients.

Methods

All patients were subjected to a clinical, biochemical and X-ray examination. Degree of glycemic control and available complications were assessed. Pre- and postprandial blood glucose level, HbA1c, urinary glucose, microalbuminuria, total cholesterol, triglycerides, LDL-cholesterol, HDL-cholesterol, bacteriological cultures were analyzed. Lipid profile was investigated by an enzyme method (Boehringer), glucose level by a glucose-oxidase method, and HbA1c by immuno-assay (Abbott). Investigation of transcutaneous oxygen tension, vibration sensation, electromyography, and Doppler ankle/brachial systolic blood pressure index was carried out. Radiographs centered on the feet were performed. Vibration sensation was measured by Rydel-Seiffer's tuning fork with a scale for quantitative assessment (values below 4 being considered an indication of diabetic neuropathy).

Isotopic imaging techniques.

All patients underwent bone scintigraphy with 370 MBq Tc-99m-MDP three hours after injection in 3 projections. The MDP index (affected area/normal bone tissue) was calculated. Radioimmune planar imaging was performed in the same three projections by immunoscintigraphy with 740 MBq Technetium (Tc) - 99m conjugated with monoclonal antigranulocyte antibody (MAb) BW 250/183 (Behring Werke, Marburg FRG/ Cis/France). Immunoscintigraphy was performed 4 and 24 hours after administration of 740 MBq Tc-99m-MAB BW 250/183 in cases with positive bone scans.

Interpretation of the images. Bone scan and immunoscintigraphic images were compared and defined as positive or negative for osteomyelitis. Final diagnosis was established by clinical follow-up, and radiographic and bacteriological results. Immunoscintigraphy was evaluated as true positive if osteomyelitis was confirmed as the final diagnosis and as false positive if osteomyelitis was not confirmed. Immunoscintigraphy was assessed as true negative if there were no other data for osteomyelitis and as false negative if osteomyelitis was confirmed by clinical, radiographical and bacteriological results.

Statistical methods. Statistical analysis included estimation of criteria for diagnostic validity: sensitivity, specificity and diagnostic accuracy.

Results

The data concerning the patients' main characteristics are summarized in Table 1. Table 2 illustrates the calculated MDP index of the investigated patients. Final diagnosis was verified by bacteriological cultures from surgical material or bone biopsy and a long-term follow-up. After 6 months' follow-up, a retrospective analysis of clinical, radiological, isotopic and bacteriological data for osteomyelitis was carried out. Final assessment of immunoscintigraphic images based on parallel analysis of isotopic images and final diagnosis revealed 21 true positive cases, 16 true negative cases, 3 false positive cases and 2 false negative cases (Table 3).

Table 1. Clinical characteristics of the investigated patients

Characteristics	units	result
mean age	years	53.7±6.1
BMI	kg/m ²	25.6±3.2
duration of diabetes	years	12.5±5.2
male / female		22/20
preprandial blood glucose	mmol/l	10.1±1.2
postprandial blood glucose	mmol/l	14.1±1.1
HbA1c	%	9.4±1.4
serum cholesterol	mmol/l	6.8±0.7
triglycerides	mmol/l	2.3±0.9
HDL-cholesterol	mmol/l	0.74±0.2
LDL-cholesterol	mmol/l	4.4 ±0.15
vibration sensation (values are given after the scale of Rydel-Seifer's tuning fork)		3± 1
Doppler ankle-arm systolic blood pressure index		0.7 ± 0.1
Transcutaneous tissue oxygen tension	%	92± 1.5

Values are given as mean±SD.

Table 2. MDP - index of the investigated patients.

MDP-index	11.15 – 1.25	1.25 -130	1.30-1.35	1.35<
Patients	22	12	6	2

Table 3. Assessment of immunoscintigraphic images

true positive cases	21
true negative cases	16
false positive cases	3
false negative cases	2

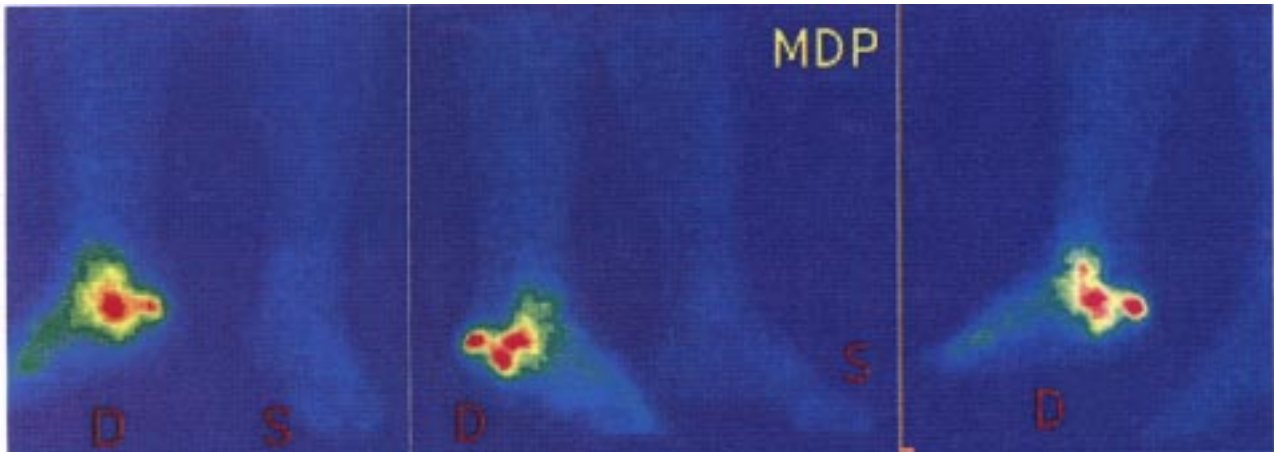
Osteomyelitis was confirmed in 21 cases (Figure 1a, Figure 1b) on the basis of clinical, radiographical and bacteriological criteria. In 16 cases osteomyelitis was not confirmed; the final diagnosis was cellulitis (out of these - 12 cases were infected neuropathic plantar ulcers with superimposed cellulitis, and 4 cases were infected neuroischaemic foot ulcers with cellulitis). Two false negative results were found in cases with chronic infection. Three false positive results were established in patients with infected ulcer.

Characteristics of diagnostic validity were analyzed (Table 4). The estimated parameters of diagnostic validity

Table 4. Parameters of diagnostic validity of the method of combined application of Tc-99m-MDP- bone scintigraphy and antigranulocyte immunoscintigraphy in patients with diabetic foot and osteomyelitis.

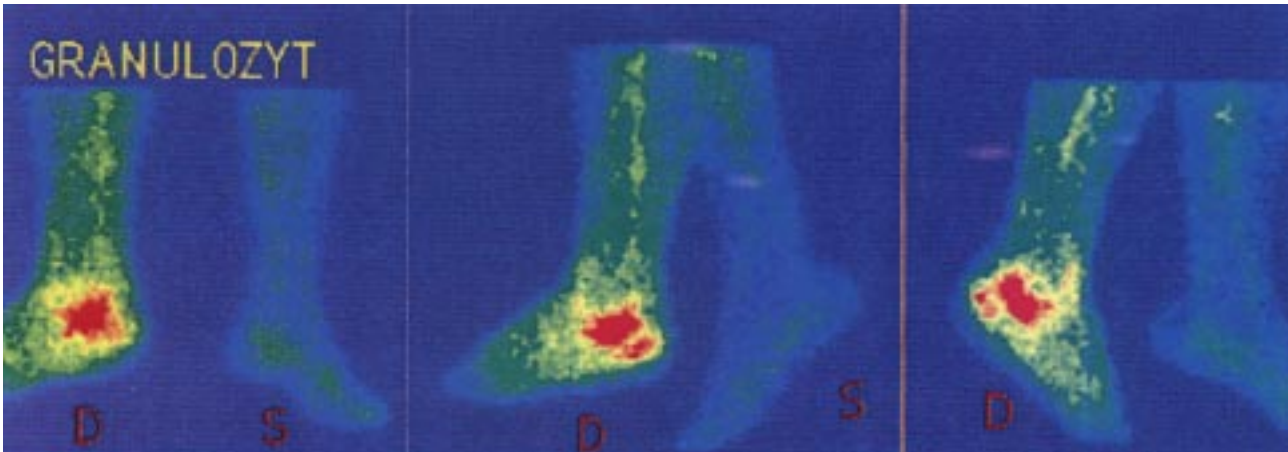
Sensitivity	91%
Specificity	85%
Diagnostic accuracy	86%

of the applied method for detection of osteomyelitis were sensitivity 91%, specificity 85%, and diagnostic accuracy 86%. The separate assessment of MDP-bone scintigraphy applied at the first stage before application of



MEDICAL UNIVERSITY - VARNA Siemens Medical Systems

Figure 1a. A case of a patient with type 2 diabetes - an ulcer of the right heel and foot bone infection. Bone scintigraphy demonstrates intensive activity in the zone of the right calcaneus. The MDP index is 1.42.



MEDICAL UNIVERSITY - VARNA Siemens Medical Systems

Figure 1b. Planar immunoscintigraphy with 740 MBq Technetium-99m conjugated with monoclonal antigranulocyte antibody demonstrates an increased uptake of labelled granulocytes in an area congruent with the MDP scanning. Final diagnosis osteomyelitis was confirmed by bacteriological cultures.

immunoscintigraphy revealed a sensitivity of 72% and a specificity of 51%.

Discussion

This study presents data concerning the application of isotopic methods for the visualization and precise localization of osteomyelitis in diabetic patients. Patients with possible foot infection requiring precise diagnosis and adequate treatment were investigated. Patients' biochemical and instrumental characteristics (Table 1) confirm the state of poor glycemic control (preprandial blood glucose level above 7.8 mmol/l), the existence of diabetic neuropathy (low vibration sensation), and peripheral diabetic macroangiopathy (Doppler ankle-arm systolic pressure index below 0.9). Poor glycemic control and available chronic diabetic complications (neuropathy, macroangiopathy) are the background and one of the main pathogenic reasons for the present diabetic ulcerations and osteomyelitis. The MDP index (Table 2) is above normal (upper normal limit 1), which could be attributed to impaired foot bone turnover in the investigated diabetic patients.

Different imaging techniques are applied for the diagnosis of diabetic foot pathology (13-15). The obligatory screening method applied in our study was MDP bone scintigraphy. When applied in patients with diabetic foot it non-specifically reveals zones of impaired bone turnover. Because of the coexistence of different pathogenic mechanisms (diabetic osteoarthropathy, inflammation and trauma) positive bone scans alone are insufficient to distinguish bone tissue damage from osteomyelitis (16,17). Our data revealed relatively low specificity (51%) and sensitivity (72%) as parameters of MDP scanning. It is only the specific binding of antigranulocyte antibody during immunoscintigraphy that can differentiate infection from other causes (18,19). Therefore, planar immunoscintigraphy was applied at a second stage in all cases when bone scanning was positive. The addition of MAb to MDP scanning raised both the sensitivity and specificity and determined high final diagnostic accuracy (86%).

Planar immunoscintigraph serves as an effective diagnostic tool for precise localization of infection. Granulocytes do not accumulate normally in the bones of the foot. Uninfected neuropathic bones and

osteoarthropathy do not fix granulocytes. The increased uptake of labelled granulocytes is specific for infection. Immunoscintigraphy detects any inflammatory accumulation of granulocytes, both in soft and bone tissue. For this reason it is a good diagnostic tool for the accurate diagnosis of both cellulitis and osteomyelitis (17).

It is not always possible to verify inflammation in bone marrow using the gold standard procedure of bone biopsy. Because of its high diagnostic accuracy, immunoscintigraphy can serve as an efficient non-invasive procedure for the early detection of bone marrow inflammation. On the basis of verified diagnosis, adequate early treatment can be undertaken. This leads to a better prognosis and the avoidance of further complications, surgical treatment and amputations.

The analysis of diagnostic validity in the detection and precise localization of foot infection by the applied method of planar immunoscintigraphic imaging in combination with bone technetium scintigraphy revealed a diagnostic accuracy of 86%. Our data are similar to those of other studies (19,20). The established data for high diagnostic accuracy confirm that antigranulocyte immunoscintigraphy with 99m-Tc-labelled monoclonal antigranulocyte antibody is an efficient method for the early diagnosis and adequate therapeutic decision in diabetic foot infection. Isotopic procedures could be helpful in cases of diabetic foot infection; they could be considered an essential part of the diabetic foot infection diagnostic schedule.

In conclusion, our data confirm that the application of immunoscintigraphy with Tc-99m-labelled antigranulocyte antibody in combination with Tc-99m-MDP bone scanning is an efficient method for the detection of foot bone infection and the precise diagnosis of osteomyelitis in diabetics.

Correspondence author:

Hripsime Artjun BOHCHELIAN

MD Clinic of Endocrinology

Medical University

"Marin Drinov" Street 55

Varna, 9002 - BULGARIA

References

1. Armstrong DG, Lavery LA. Diabetic foot ulcers: prevention, diagnosis and classification. *Am Fam Physician* 57: 1325-32, 1998.
2. Currie CJ, Morgan CL, Peters JR. The epidemiology and cost of inpatient care for peripheral vascular disease, infection, neuropathy, and ulceration in diabetes. *Diabetes Care* 21: 42-8, 1998.
3. Mancini L, Ruotolo V. The diabetic foot: epidemiology. *Rays* 22: 511-23, 1997.
4. Slovenkai MP. Foot problems in diabetes. *Med Clin North Am* 82: 949-71, 1998.
5. Vowden K. Diabetic foot complications. *J Wound Care* 6: 4-8, 1997.
6. Mayfield JA, Reiber GE, Nelson RG, Greene T. Do foot examinations reduce the risk of diabetic amputation? *J Fam Pract* 49 – Suppl: 499-504, 2000.
7. Smith RJ. Saving the diabetic foot. *J Natl Med Assoc* 92: 405-10, 2000.
8. Frykberg RG, Armstrong DG, Giurini J, Edwards A, Kravette M, Kravitz S, Ross C, Stavosky J, Stuck R, Vanore J. Diabetic foot disorders. A clinical practice guideline for the American College of Foot and Ankle Surgeons and the American College of Foot and Ankle Orthopedics and Medicine. *J Foot Ankle Surg suppl*: 1-60, 2000.
9. Becker W, Goldenberg DM, Wolf F. The use of monoclonal antibodies and antibody fragments in the imaging of infectious lesions. *Seminars in nuclear medicine*, 14: 142-153, 1994.
10. Dominguez-Gadea L, Martin-Curto LM, de la Calle H, Crespo A. Diabetic foot infections: scintigraphic evaluation with ⁹⁹Tcm-labelled anti - granulocyte antibodies. *Nuclear Medicine Communications*, 14: 212-218, 1993.
11. Fox IM, Zeiger L. Tc-^{99m}-HMPAO leukocyte scintigraphy for the diagnosis of osteomyelitis in diabetic foot infections. *J Foot Ankle Surg*, 32: 591-594, 1993.
12. Krznaric E, De Roo M, Verbrugen A, Stuyck J, Mortelmans L. Chronic osteomyelitis: diagnosis with technetium -^{99m}-d,l.-hexamethylpropylene amine oxime labelled leucocytes. *Eur J Nucl Med*, 23: 792-797, 1996.
13. Newman LG. Imaging techniques in the diabetic foot. *Clinics in Podiatric Medicine & Surgery*, 12: 75-86, 1995.
14. Oyen WJ, Netten PM, Lemmens JA, Corstens FH. Evaluation of infectious diabetic foot complications with indium-111-labeled human nonspecific immunoglobulin G. *J Nucl Med*, 33: 1330-1336, 1992.
15. Wang DC, Kottamassu SR, Karvelis K. Scintigraphy in metabolic bone disease. In: *Primer on the metabolic bone diseases and disorders of mineral metabolism*. Raven Press Ltd. 1993, 129-136, 1993.
16. Gibbons GW, Habershaw GM. Diabetic foot infections. *Anatomy and surgery, Infectious Disease Clinics of North America*, 9: 131-142, 1995.
17. Lupo MM. An overview of foot disease associated with diabetes mellitus. *Med-surg Nurs* 6: 225-9, 1997.
18. Devillers A, Moisan A., Hennion F, Garin E, Poirier GY, Bourguet P. Contribution of Technetium -^{99m} hexamethyl-propylene amine oxime labelled leucocyte scintigraphy to the diagnosis of diabetic foot infection. *Eur J Nucl Med*, 25: 132-137, 1998.
19. Lind P, Langsteger W, Koltringer P, Dimai HP, Passl R, Eber O. Immunoscintigraphy of inflammatory process with a Technetium - ^{99m}-labeled monoclonal antigranulocyte antibody (MAb BW 250/183). *J Nucl Med*, 31: 417-423, 1990.
20. Scheidler J, Leinsinger G, Pfahler M, Kirsch CM. Diagnosis of osteomyelitis. Accuracy and limitations of antigranulocyte antibody imaging compared to three-phase bone scan. *Clin. Nucl. Med*, 19: 731-737, 1994.