

Gülay ÖZBİLİM<sup>1</sup>  
Bahar KILIÇARSLAN<sup>1</sup>  
Ekmel TEZER<sup>3</sup>  
Ayla BÜYÜKKEÇE<sup>2</sup>  
Melek ÜSTÜN<sup>1</sup>  
Şeyda KARAVELİ<sup>1</sup>  
Nezihi OYGÜR<sup>2</sup>

## Breast Carcinoma Showing Neuroendocrine Differentiation Characterized with Ectopic Hormone Production (2 case reports)

Departments of <sup>1</sup>Pathology, <sup>2</sup>General Surgery, Faculty of Medicine, Akdeniz University, Antalya, <sup>3</sup>Department of Pathology, Faculty of Medicine Süleyman Demirel University, Isparta-TURKEY

Received: September 09, 1999

**Key Words:** Neuroendocrine differentiation, ectopic hormone production, breast carcinoma

Neuroendocrine differentiation can be found in benign or malignant lesions of various organ systems. In 1947, Vogler indicated the existence of neuroendocrine cells in mammary tissue (1). Recent studies have reported the incidence of neuroendocrine differentiation in breast carcinomas as being between 3% and 21% (2). The existence of neuroendocrine differentiation was also shown in male breast carcinomas (3). Neuroendocrine differentiation detected in breast carcinomas shows morphological similarities to carcinomas of the gastrointestinal system, lung, and other non-endocrine organs with endocrine differentiation and carcinoid tumours. In order to verify the existence of these cells, in addition to morphological examination, histochemical and immunohistochemical staining is used. The presence of argyrophilic and electron-dense granules is usually sufficient (4,5). For immunohistochemical staining, Neuron Specific Enolase (NSE) and Chromogranin A are frequently used (6-9). Rarely, hormone production of the tumor is also present, the most common hormones being: ACTH, leucoencephalin, gastrin, pancreatic polypeptide, bombesin, serotonin, HCG, prolactin, vasointestinal polypeptide (VIP), and luteinizing hormone releasing factor (5,10,11,12).

In this study, two cases of breast carcinoma showing neuroendocrine differentiation and ectopic hormone secretion are presented together with their histochemical and immunal staining properties.

### Case Reports

Case 1 (Case A): A sixty-seven-year-old patient was admitted to a medical center complaining of a mass in her right breast. After a biopsy, "invasive lobular carcinoma" was diagnosed and her mastectomized tissue was sent to the pathology department for consultation and the determination of prognostic factors. An examination of her organ systems did not reveal any pathological findings.

Macroscopic findings: Tumors were found in two foci on the examination of thin sections of the mastectomized tissue. The tumor tissues were hard in consistency, and gray-white in color. One of them was under the areola, and the other was in the lower medial quadrant. Their diameters were 2.7 and 3cm respectively. Two lymph nodes in the central axilla and one node in the midaxilla were found to be involved by macroscopy.

Microscopic findings: Paraffin slides were prepared from the tumor foci, from all quadrants, and the lymph nodes were evaluated by light microscopy. The tumor was made up of tubular and organoid structures consisting of atypical cells with oval and round hyperchromatic nuclei. Grimelius staining revealed argyrophilic granules in the tumor cells. Immunohistochemically, chromogranin A, NSE and S-100 were found to be positive (Fig.2). Since it has been reported that estrogen, progesteron, ACTH, HCG and prolactin can also be positive in these tumors, related stains were applied immunohistochemically. The

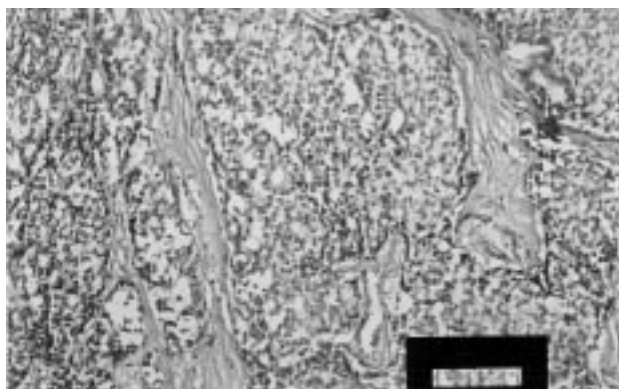


Figure 1. Microscopic appearance of breast carcinoma with neuroendocrine differentiation (HE; x 20)

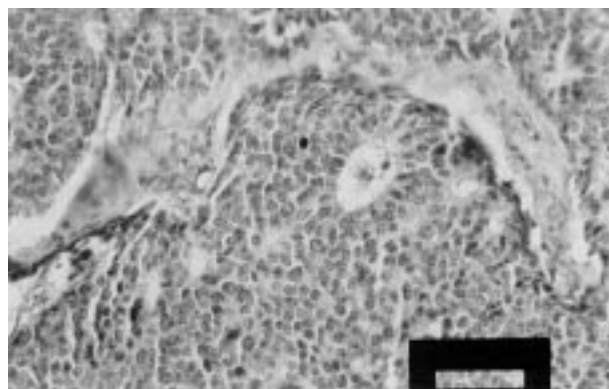


Figure 2. Immunohistochemical stain for Chromogranin A in breast carcinoma with neuroendocrine differentiation (Chromogranin A; x20).

results for these stains and other immunohistochemical stains used as determining prognostic factors are given in Table 1. This patient had two metastatic lymph nodes dissected from the central axilla.

Case 2 (Case B): A sixty-seven year-old patient (C.T.) was admitted to the outpatient clinics of the General Surgery Department of our medical school after she noticed a mass in her right breast. The mass, which was localized in the upper lateral quadrant of the right breast, was excised. The patient had been treated for essential hypertension for 30 years. There were no other pathological findings in her organ systems.

Macroscopic findings: The dimensions of the material sent to the pathology department were 3x2.5x1.2 cm. It was covered with mature fat tissue. When dissected, a tumoral mass of gray-white color, hard in consistency, with irregular borders, and 1.5 cm in diameter was found. All of the tissue was examined.

Macroscopic findings: It was noted that the structures of mammary tissue observed in mature fat tissue disappeared in large areas and transformed into tumor tissue. The tumor was made up of organoid structures consisting of atypical cells with oval, round, and hyperchromatic nuclei, and narrow cytoplasm, showing rare mitosis. In order to check for the existence of argyrophilic granules, Grimelius stain was applied histochemically and it was found to be positive in wide areas or most areas. The results of S-100, NSE, chromogranin A and ACTH, prolactin, HCG estrogen, and progesteron and other immunohistochemical staining applied are shown in Table 2 (Figures 3 and 4).

Both cases were diagnosed as breast carcinomas showing neuroendocrine differentiation according to the results of histochemical and immunohistochemical staining and histopathologic findings obtained by light microscopy. Fifty-micron-thick slices prepared from

Table 1. The results of immunohistochemical stains of A case.

	ACTH	HCG	Prolactin	Estrogen	Progesteron	CEA	S-100	NSE	Chromogranin	P53	Cat D	PCNA	cerbB2	Lectin
% of the fields	70	20	40	80	-	80	80	80	70	10	70	60	-	-
	+	++;+++	++;+	++		++	++;+	++	++	+	+++;+	++		

Table 2. The results of immunohistochemical stains of B case.

	ACTH	HCG	Prolactin	Estrogen	Progesteron	CEA	S-100	NSE	Chromogranin	P53	Cat D	PCNA	cerbB2	Lectin
% of the fields	-	60	-	80	40	60	90	80	20	-	70	5	90	80
		++		++	+	+++	++	+++	+		+	++	+++	+




Figure 3. Immunohistochemical stain for HCG in breast carcinoma with neuroendocrine differentiation (HCG; x 40).

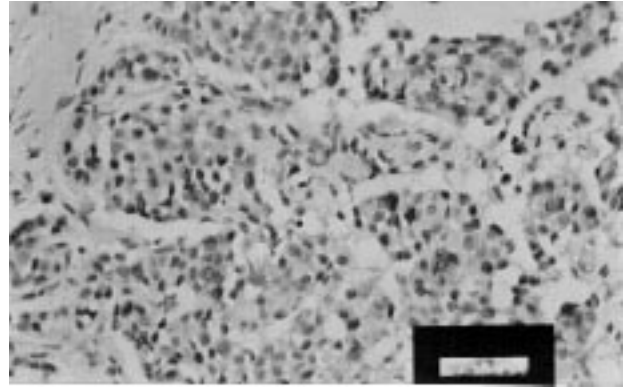


Figure 4. Immunohistochemical stain for estrogen receptors in breast carcinoma with neuroendocrine differentiation (Estrogen; x 40).

paraffin blocks of the specimens were digested with 0.5% pepsin after being treated in xylene and alcohol. The nuclei were washed by PBS and stained with propidium iodide. The DNA content was measured by an ICS-22 flow cytometry instrument. It was found that the cells of Case 1 were in the diploid cycle (Fig.5), whereas 83.8% of the cells of Case 2 were in the diploid cycle and 16.2% were in the aneuploid cycle (Fig.6). The S phases of Case 1 and Case 2 were found to be 6.1% and 13.2% respectively.

We observed that Case A, whose tumor was multifocal and had a diameter of 3 cm, showed positive reactions to p53, Cat-D, and PCNA stains. She had metastases in two lymph nodes. Macroscopically, in Case B, whose tumor was 1.5 cm in diameter, p53 was negative, PCNA

was one positive (+) in 5% of the areas; Cat-D, c-erbB2, and UEA-1 lectin were significantly positive. DNA analyses of these patients revealed that the cells of Case A were diploid, while the cells of Case B were 83.8% diploid and 16.2% aneuploid.

### Discussion

Breast carcinomas containing neuroendocrine cells used to be known as argyrophilic breast carcinomas or breast carcinoid tumors, but are now classified as "breast carcinomas with neuroendocrine differentiation" (2,13).

The incidence of neuroendocrine differentiation in breast carcinomas is between 3 and 21% (2,4,13,14), and the existence of neuroendocrine cells in ductal and

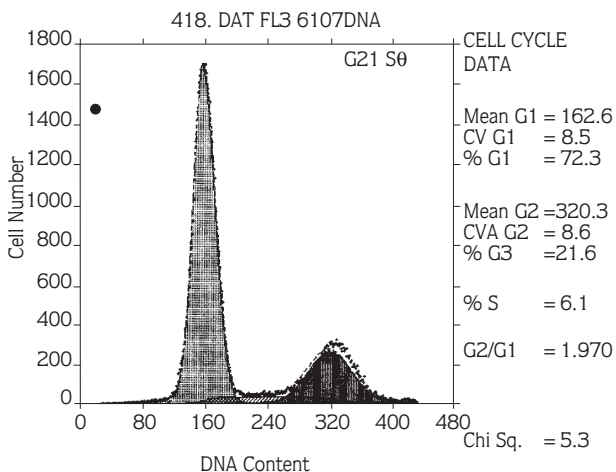


Figure 5. DNA histogram of diploid A case.

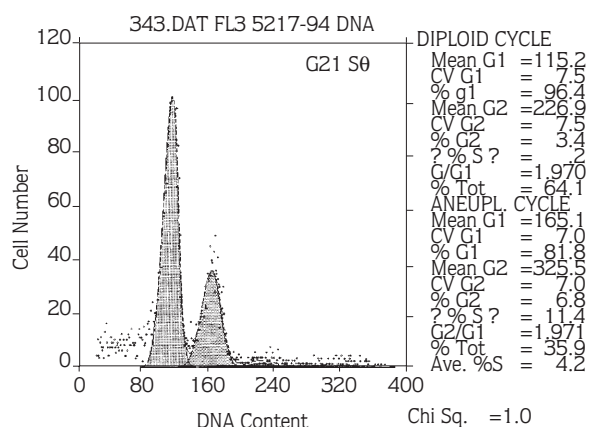


Figure 6. DNA histogram of aneuploid B case.

lobular carcinomas has also been reported (2,4,5,13,14). One study suggested that there are no neuroendocrine cells in normal breast tissue (5,15); however, in another study, a small number of neuroendocrine cells were determined in normal breast ducts (16).

Breast carcinomas showing neuroendocrine differentiation are histopathologically similar to the carcinoid tumors of the digestive and respiratory tracts. However, they are morphologically and clinically different from the classical carcinoid tumors of other systems (5,17). Grimelius staining is specific and shows argyrophilic granules to prove the existence of neuroendocrine cells in these tumors (14). The immunohistochemical reactivity of NSE is a useful indicator (6). However, in some normal breast tissues, myoepithelial cells show a weak positive reaction with NSE. Therefore, positivity determined with NSE should be supported by other findings (6). Fifty to eighty-six percent of breast carcinomas showing neuroendocrine differentiation exhibit chromogranin A positivity immunohistochemically (12,18).

Histopathological examination of both of our patients made us consider the presence of neuroendocrine differentiation because of the existence of solid and tubular structures of groups of uniform cells with oval and round hyperchromatic nuclei, and narrow cytoplasm, showing rare mitosis. Neuroendocrine granules were observed by means of the histochemical stain of Grimelius. Immunohistochemically applied NSE demonstrated two and three positive staining concentrations in 80% of areas in both patients. Chromogranin A was found to be two positive in

70% of areas in Case A and one positive in 20% of areas in Case B. The prognostic parameters p53, Cat-D, PCNA, c-erbB2 and UEA-1 lectin were applied to both cases. It was reported that Case A had been mastectomized at another hospital and she did not have any lymph node metastases. The synthesis phases in both cases were found to be low: in Case A, 5%, 6.1; in Case B, 5%, 13.2. In a previous study, it was reported that in NSE positive grade 1 neuroendocrine tumors there was aneuploidy, whereas in the NSE negative group there was diploidy (19).

In rare cases of tumors showing neuroendocrine differentiation, hormone production occurs (8,11). Estrogen, ACTH, epinephrin, gastrin, prolactin, luteinizing hormone and HCG are the hormones which can be determined. Estrogen and progesterone were investigated immunohistochemically. It was found that, in A there was ACTH and prolactin, while in B there was progesterone in addition to estrogen and HCG, which were determined in both cases. In these cases no clinical findings were observed which were in accordance with what has been reported in the literature as a result of hormone production (7) There was no evidence of recurrence postoperatively (24 months for Case A and 29 months for Case B).

These two cases, which exhibited neuroendocrine differentiation in the tumors and ectopic hormone production, were presented together with histochemical and immunohistochemical findings and the results of flow cytometry because of their rarity.

## References

1. Vogler E. Giber das basilore Helle-Zellen-Organ der menschlichen Brustdrüse-klm Med 1947; 2:159-168.
2. Tavasoli FA. Pathology of the Breast. First edition, Norwalk, Connecticut, Appleton & Lange 2000; 402-480.
3. Kaneko H, Sumida T, Sekiya M. A breast carcinoid tumor with special reference to ultrastructural study. Acta Pathol Jpn 32: 327-32, 1982.
4. Toyoshima S. Mamary carcinoma with Argyrophil Cells. Cancer 52: 121-38, 1983.
5. Fetissof F, Dubois MP, Brassart BA, Lansac J, Jobard P. Argyrophilic cells in mammary carcinoma. Hum Pathol 14:121-34, 1983.
6. Nesland JM, Holm R, Johannessen JV, Gould VE. Neurone Specific Enolase Immunostaining in the Diagnosis of Breast Carcinomas with Neuroendocrine Differentiation. Its Usefulness and Limitations. J Pathol 148: 35-43, 1986.
7. Monaghan P, Roberts JDB. Immunocytochemical Evidence for Neuroendocrine Differentiation in Human Breast Carcinomas. J Pathol 147: 281-89, 1985.
8. Papotti M, Macri L, Finzi G, Capella C, Eusebi V, Bussolati G. Neuroendocrine Differentiation in Carcinomas of the Breast: A study of 51 cases Semin Diag Pathol 6:174-88,1989.
9. Paties C, Zangrandi A, Taccagni GL, et al. Spindle cell non-argyrophil carcinoma of the breast with neuroendocrine differentiation. Histopathology 29:471-473,1996.
10. Cohle SD, Tschen JA, Smith FE. ACTH-secreting Carcinoma of the Breast. Cancer 43:2370-74, 1979.

11. Woodard BH, Eisenbarth G, Wallace NR. Adrenocorticotropin Production by a mammary Carcinoma. *Cancer* 47:1823-28,1981.
12. Tormey DC, Waalkes TP, Simon RM. Biological markers in breast carcinoma. II. Clinical correlations with human chorionic gonadotropin. *Cancer* 39: 2391-94,1977.
13. Alkanat MB, Özdemir N, Erhan Y, Eldem A, Özbal O, Erhan Y. mammary Carcinoma with Neuroendocrine Differentiation. *Turkish J Cancer* 26:146-53,1996.
14. Erlandson RA, Nesland JM. Tumors of the Endocrine/Neuroendocrine System: An overview. *Ultrastruc Pathol* 18:149-70,1994.
15. Viacava P, Castagna M, Bevilacqua G. Absence of neuroendocrine cells in fatal and adult mammary gland. Are neuroendocrine breast tumours real endocrine tumours? *Breast* 4: 143-146, 1995.
16. Bussolati G, Gugliotta P, Sapino A, Eusebi V, Lloyd RV. Chromogranin-Reactive Endocrine cells in Argyrophilic Carcinomas (Carcinoids) and Normal Tissue of the Breast. *Am J Pathol* 120:186-92, 1985.
17. Taxy JB, Tischler AS, Insalaco S, Battifora H. "Carcinoid" Tumor of the Breast. A variant of Conventional Breast Cancer? *Hum Pathol* 12: 170-79, 1981.
18. Bussolati G, Papotti M, Sapino A. Endocrine Markers in Argyrophilic Carcinomas of the Breast. *Am J Surg Pathol* 11: 245-56, 1987.
19. Nesland JM, Pettersen EO, Fossa SD, Hoie J, Johannessen JV. Nuclear DNA Content in Breast Carcinomas with Neuroendocrine Differentiation. *J. Pathol* 150:181-85, 1986.

