

2024

## Patterns of longitudinal subcortical atrophy over one year in amnesic mild cognitive impairment and its impact on cognitive performance: a preliminary study

BERRİN ÇAVUŞOĞLU

DUYGU HÜNERLİ

DERYA DURUSU EMEK SAVAŞ

GÖRSEV YENER

EMEL ADA

Follow this and additional works at: <https://journals.tubitak.gov.tr/medical>



Part of the [Medical Sciences Commons](#)

### Recommended Citation

ÇAVUŞOĞLU, BERRİN; HÜNERLİ, DUYGU; EMEK SAVAŞ, DERYA DURUSU; YENER, GÖRSEV; and ADA, EMEL (2024) "Patterns of longitudinal subcortical atrophy over one year in amnesic mild cognitive impairment and its impact on cognitive performance: a preliminary study," *Turkish Journal of Medical Sciences*: Vol. 54: No. 3, Article 14. <https://doi.org/10.55730/1300-0144.5826>

Available at: <https://journals.tubitak.gov.tr/medical/vol54/iss3/14>



This work is licensed under a [Creative Commons Attribution 4.0 International License](#).

This Research Article is brought to you for free and open access by TÜBİTAK Academic Journals. It has been accepted for inclusion in Turkish Journal of Medical Sciences by an authorized editor of TÜBİTAK Academic Journals. For more information, please contact [pinar.dundar@tubitak.gov.tr](mailto:pinar.dundar@tubitak.gov.tr).

## Patterns of longitudinal subcortical atrophy over one year in amnesic mild cognitive impairment and its impact on cognitive performance: a preliminary study

Berrin ÇAVUŞOĞLU<sup>1,\*</sup>, Duygu HÜNERLİ<sup>2</sup>, Derya Durusu EMEK SAVAŞ<sup>3</sup>, Görsev YENER<sup>2,4,5</sup>, Emel ADA<sup>6</sup>

<sup>1</sup>Department of Medical Physics, Institute of Health Sciences, Dokuz Eylül University, İzmir, Türkiye

<sup>2</sup>Department of Neuroscience, Institute of Health Sciences, Dokuz Eylül University, İzmir, Türkiye

<sup>3</sup>Department of Psychology, Faculty of Letters, Dokuz Eylül University, İzmir, Türkiye

<sup>4</sup>Faculty of Medicine, İzmir University of Economics, İzmir, Türkiye

<sup>5</sup>İzmir International Biomedicine and Genome Institute, İzmir, Türkiye

<sup>6</sup>Department of Radiology, Faculty of Medicine, Dokuz Eylül University, İzmir, Türkiye

Received: 21.05.2022

Accepted/Published Online: 11.03.2024

Final Version: 12.06.2024

**Background/aim:** Amnesic mild cognitive impairment (aMCI) is a risk factor for dementia, and thus, it is of interest to enlighten specific brain atrophy patterns in aMCI patients. We aim to define the longitudinal atrophy pattern in subcortical structures and its effect on cognition in patients with aMCI.

**Materials and methods:** Twenty patients with aMCI and 20 demographically matched healthy controls with baseline and longitudinal structural magnetic resonance imaging scans and neuropsychological assessments were studied. The algorithm FIRST (FMRIB's integrated registration and segmentation tool) was used to obtain volumes of subcortical structures (thalamus, putamen, caudate nucleus, nucleus accumbens, globus pallidus, hippocampus, and amygdala). Correlations between volumes and cognitive performance were assessed.

**Results:** Compared with healthy controls, aMCI demonstrated subcortical atrophies in the hippocampus ( $p = 0.001$ ), nucleus accumbens ( $p = 0.003$ ), and thalamus ( $p = 0.003$ ) at baseline. Significant associations were found for the baseline volumes of the thalamus, nucleus accumbens, and hippocampus with memory, the thalamus with visuospatial skills.

**Conclusion:** aMCI demonstrated subcortical atrophies associated with cognitive deficits. The thalamus, nucleus accumbens, and hippocampus may provide additional diagnostic information for aMCI.

**Key words:** Mild cognitive impairment, subcortical structures, magnetic resonance imaging, atrophy, neurocognitive functions

### 1. Introduction

Mild cognitive impairment (MCI) represents a transitional phase between dementia and normal aging [1]. Patients with MCI show dysfunction of cognitive domains involving memory, executive function, attention, language, and visuospatial, but do not fulfill the criteria for dementia [2]. Amnesic MCI (aMCI) that those with decreased memory ability have a greater risk of progression towards Alzheimer's disease (AD) dementia [3]. Therefore, in vivo imaging biomarkers, which allow early diagnosis of patients with aMCI at high risk of developing AD dementia, are of prognostic importance.

Distinguishing the signs of MCI on magnetic resonance imaging (MRI) from normal age-related changes represents a challenge in brain imaging studies. MRI-based estimates of brain atrophy have been evidenced as a valid marker

of neurodegenerative changes related to AD [4]. Being able to detect disease-related volumetric alterations before cognitive deterioration occurs is important for the early diagnosis of the disease. While most studies have focused primarily on the hippocampus and the neocortex because of their obvious role in memory processes and cognitive functions [5,6], subcortical structures have attracted much less attention [5,7]. Previous studies have revealed that patients with aMCI present the atrophy of subcortical grey matter (GM) including the thalamus, hippocampus, and other subcortical structures [8-10]. However, it still is unclear to what extent the aMCI affects the neurocognitive functions and subcortical structures. These structures might be differentially affected by long-term structural alterations and these changes may contribute to the cognitive deficit in aMCI patients.

\* Correspondence: [berrncavusoglu@gmail.com](mailto:berrncavusoglu@gmail.com)

MRI brain atrophy rate measured using serial images is a promising biomarker of AD progression [11,12]. Longitudinal volumetric analysis of subcortical structures might supply beneficial knowledge about the pattern of structural alterations that are associated with cognitive decline in aMCI. It is crucial to understand how the atrophy rate is related to cognitive decline to provide more effective plans for clinical research that can slow or prevent disease progression.

To the best of our knowledge, no study to date has examined the longitudinal progression of subcortical atrophy and its effect on cognition in aMCI. In the present study, we aimed to investigate the progression of subcortical atrophy over one year between aMCI and normal aging controls. We hypothesized that longitudinal subcortical GM atrophy contributes to an aMCI-related cognitive impairment with disease-specific patterns and that the subcortical GM atrophy pattern is associated with poorer cognitive test scores. We also hypothesized aMCI will have a greater subcortical GM atrophy rate and differ from normal aging controls.

## 2. Materials and methods

### 2.1. Participants

The retrospective study included 20 individuals with aMCI, and 20 age-, sex- and education-matched healthy elderly participants. Individuals with aMCI were recruited from the outpatient memory clinic of Dokuz Eylül University whereas healthy elderly participants were recruited from various community sources. Each subject underwent both baselines and repeat MRI scans and neuropsychological assessments at a one-year ( $14.85 \pm 6.47$  months) interval between 2013 and 2016.

For healthy elderly participants, the inclusion criteria were as follows: 1) no history of neurological abnormality and/or cognitive deficits (mini-mental state examination (MMSE) score  $\geq 27$ ); and 2) no self-reported cognitive complaints. The diagnosis of aMCI was performed according to NIA-AA diagnostic criteria [13]. In patients where amyloid-beta biomarkers were not evaluated according to the criteria, individuals whose neuronal damage occurring in MCI due to possible AD was detected with structural MRI of the temporal, parietal, hippocampus, and posterior cingulate [13]. The "positivity" was determined by the expert neurologists responsible for releasing the clinical diagnosis to the patients. The other clinical inclusion criteria of the aMCI patients were as follows: 1) memory complaints by the patient; 2) clinical dementia rating score of 0.5 (CDR [14]); 3) preserved daily life functionality; and 4) memory impairment defined with performances  $\geq 1.5$  standard deviation below for age- and education-matched controls in a battery of neuropsychological tests.

The clinical exclusion criteria of the aMCI patients were as follows: 1) systematic use of antidepressant drugs with anticholinergic side effects; and 2) actual participation in a clinical trial using disease-modifying drugs. For all participants, the exclusion criteria were as follows: 1) history of psychiatric and/or neurological including evidence of depression as demonstrated by Yesavage geriatric depression scale scores higher than 13; 2) history of alcohol and/or drug misuse and severe head injury; 3) presence of nonstabilized medical illnesses; 4) presence of a brain tumor, hydrocephalus, or vascular brain lesions; and 5) chronic use of narcotics, neuroleptics, analgesics, sedatives, or hypnotics and/or cognitive enhancers including acetylcholinesterase inhibitors.

For the determination of sample size, we used G\*power (version 3.1) [15]. Since no study so far examined the longitudinal progression of subcortical atrophy in aMCI, we opted for the detection of at least hippocampal atrophy rate between groups according to a previous study [16]. We used the following criteria to calculate sample size: ANCOVA model,  $\alpha = 0.05$ ,  $1-\beta = 0.80$ , number of groups = 2, number of covariates = 4. This calculation rendered a total sample size of 44. For the present study, we only achieved a total sample size of 40 due to the following exclusion criteria for each subject; poor image quality, MRI interval greater than one year, or lack of follow-up scanning.

### 2.2. Neuropsychological assessment and diagnostic criteria

A detailed neuropsychological test battery was applied to all participants. Global cognitive status was evaluated with MMSE [17]. In order to constitute cognitive domains, neuropsychological scores were first converted into z-scores according to age and education-adjusted norms. Then, composite scores were formed for each domain using the average z-scores of related neuropsychological tests. Memory domain was evaluated with Öktem Verbal Memory Processes Test (ÖVMPT) [18], attention/executive functions with Stroop test [19], WMS-R digit span test, verbal fluency test (phonemic), language domain with Boston Naming Test [20] and verbal fluency test (categorical), visuospatial domain with clock drawing test [21], and simply copying tests.

### 2.3. MRI acquisition and preprocessing

Both baseline and repeat brain MRI acquisitions were performed at the Department of Radiology in Dokuz Eylül University using the same 1.5 T Philips Achieva scanner (Philips Medical Systems, Best, the Netherlands) and a standard imaging protocol. A high-resolution 3D T1-weighted magnetization prepared rapid gradient echo sequence (repetition time: 25 ms, echo time: 6 ms, matrix: 512, field of view: 230 mm, number of signal averages: 1, slice thickness: 1 mm) was obtained for volumetric

analysis. Axial T2 weighted dual-echo images were acquired for radiological assessment.

Automatic volume estimation of the subcortical structures was performed by using the FSL software package<sup>1</sup>. FMRIB's integrated registration and segmentation tool (FIRST) [22] was applied to perform the segmentation and to estimate volumes in seven subcortical structures, including the thalamus, putamen, caudate nucleus, amygdala, globus pallidus, nucleus accumbens, and hippocampus, at each time point. FIRST initially performed an affine registration of 3D T1-weighted images to the MNI space. Next, the algorithm applies the inverse transformation to bring the images back to native space, followed by a boundary correction. The volume of each region was extracted bilaterally. All subcortical raw volumes were normalized for head size by multiplying by the volumetric scaling factor, which was automatically calculated using SIENAX (an adaptation of SIENA (Structural Image Evaluation, using Normalization, of Atrophy) for cross-sectional measurement [23]). Finally, the left and right hemispheric measurements of the same structure were summed to reduce the number of comparisons between groups. An example of FSL-segmentation of subcortical structures for a healthy subject is demonstrated in Figure 1.

#### 2.4. Statistical analysis

SPSS version 24.0 (IBM; Armonk, NY, USA) was used for all statistical analyses. Comparisons of demographic variables between groups were conducted using Mann-Whitney U test for continuous variables and the chi-square test for categorical variables. Change rates in subcortical volumetric measurements and z-scores of cognitive domains between two-time points were calculated with the following formula:  $[(\text{data}_{\text{follow-up}} - \text{data}_{\text{baseline}}) / \text{data}_{\text{baseline}}] / \text{interval (in years)}$ .

<sup>1</sup> FMRIB (2022). FMRIB Software Library, version 6.0 [online]. Website [www.fmrib.ox.ac.uk/fsl](http://www.fmrib.ox.ac.uk/fsl) [accessed 05 January 2022].

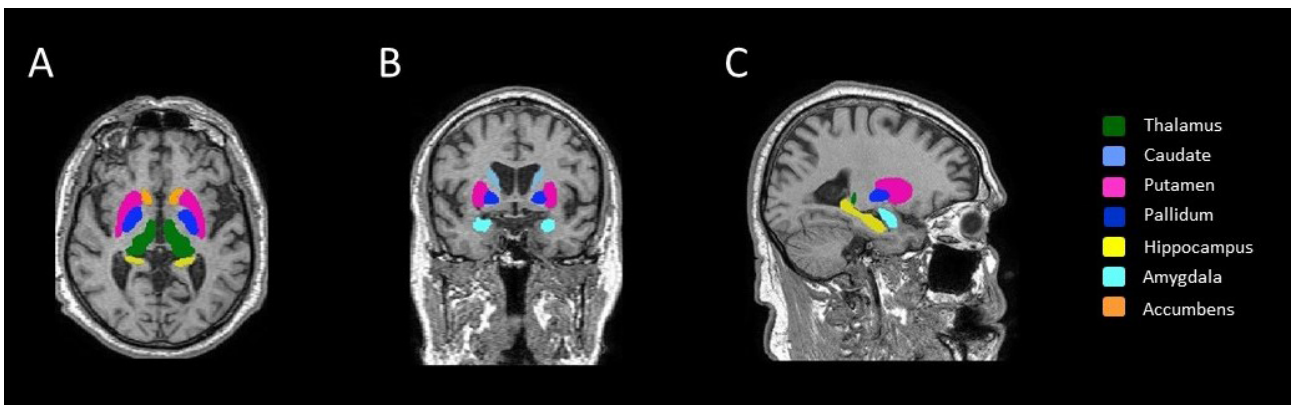
Group differences in the volumetric values and z-scores of cognitive domains were tested using analysis of covariance (ANCOVA). Age, sex, and education were included in the model as covariates of no interest, while baseline data served as additional covariates for comparing change rates between groups. Correlations between volume measurements and z-scores of cognitive domains were performed using either Pearson or Spearman correlation analysis after the Kolmogorov-Smirnov test was run to evaluate whether the variables show normal distribution. We also conducted partial correlations corrected for age, sex, and education.

The results were corrected with the Bonferroni correction for multiple tests [24]. For cognitive domains, corrections were applied to the four tests, and the statistical significance threshold was set to  $p \leq 0.0125$  ( $\alpha/4$ ). For volumetric analysis, corrections were applied to the seven tests, and the statistical significance threshold was set to  $p \leq 0.007$  ( $\alpha/7$ ). For correlation analysis, corrections were applied to the 28 tests (seven subcortical structures  $\times$  four cognitive domains), and the statistical significance threshold was set to  $p \leq 0.0018$  ( $\alpha/28$ ). We presented the unadjusted p values and only the p values that survived Bonferroni correction were reported as significant.

### 3. Results

#### 3.1. Demographic and clinical variables characteristics of the participants

The demographic and clinical characteristics by the group are shown in Table 1. There were no differences in age, sex, education, hand dominance, or GDS between controls and aMCI. At baseline, aMCI presented significantly lower scores in visuospatial skills ( $p = 0.005$ ), episodic memory ( $p < 0.001$ ), attention/executive functions ( $p = 0.002$ ), and language ( $p = 0.007$ ) domains compared to controls.



**Figure 1.** Example of automated segmentation of subcortical grey matter structure using FIRST on 3D T1-weighted images in A) axial, B) coronal, and C) sagittal planes.

Additionally, aMCI showed poorer scores on MMSE than controls. There were no differences in change rates between the groups. Table 2 presents the mean composite scores by group.

**3.2. Subcortical volumetric analysis**

At baseline, subjects with aMCI had a significantly lower volume in the thalamus ( $p = 0.003$ ), hippocampus ( $p = 0.001$ ), and nucleus accumbens ( $p = 0.003$ ) compared to controls. There were no other significant subcortical volume differences between the aMCI and the control group. We also observed a greater hippocampus atrophy rate ( $p = 0.009$ ) between groups; however, this result did not survive Bonferroni correction for multiple

comparisons. Table 3 presents the comparisons of baseline volumes and the change rates in volumes between baseline and follow-up.

**3.3. Correlation between the change rates of subcortical volume and cognitive performance**

Correlations were analyzed for the total sample as a whole, as well as separately for the aMCI group. Only the significant correlations that survived the Bonferroni correction were reported.

At baseline, strong correlations were detected between memory and hippocampus volume ( $r = 0.575$ ,  $p < 0.001$ ) (Figure 2A) and nucleus accumbens volume ( $r = 0.522$ ,  $p = 0.001$ ) (Figure 2B). Moreover, thalamus volumes were

**Table 1.** Demographic and clinical characteristics of participants.

	Healthy controls (n = 20)	aMCI patients (n = 20)	p
Age (years)	70.15 ± 5.90	73.32 ± 4.63	0.052
Sex (M/F)	9/11	10/10	0.752
Education (years)	10.15 ± 5.21	9.48 ± 4.69	0.424
Hand dominance (R/L/both)	20/0/0	19/0/1	0.311
MMSE	29.26 ± 0.99	25.56 ± 3.52	<b>&lt;0.001</b>
Yesavage GDS	5.75 ± 4.67	7.60 ± 5.34	0.236

M: male, F: female, R: right, L: left, MMSE: mini-mental state examination, Yesavage GDS: Yesavage geriatric depression scale. Significant p-value is highlighted in bold.

**Table 2.** Neuropsychological performances of participants.

	Healthy controls (n = 20)	aMCI patients (n = 20)	p
<b>Episodic memory</b>			
Baseline	0.00 ± 0.86	-3.68 ± 1.28	<b>&lt; 0.001</b>
% change	0.00 ± 0.03	0.00 ± 0.00	0.845
<b>Attention/executive function</b>			
Baseline	0.05 ± 0.61	-0.85 ± 1.39	<b>0.002</b>
% change	0.00 ± 0.05	-0.01 ± 0.06	0.520
<b>Visuospatial</b>			
Baseline	0.03 ± 0.77	-1.60 ± 2.39	<b>0.005</b>
% change	-0.00 ± 0.02	0.00 ± 0.07	0.584
<b>Language</b>			
Baseline	-0.03 ± 0.78	-1.00 ± 1.50	<b>0.007</b>
% change	-0.00 ± 0.01	0.01 ± 0.16	0.583

Results of the ANCOVA model adjusted are reported. p values where the model is significant after Bonferroni correction for multiple comparisons are highlighted in bold.

**Table 3.** Volumetric measurements of baseline and follow-up MRI in MCI subjects compared to controls.

	Healthy controls (n=20)		aMCI (n=20)		p-value	
	Baseline volume	% change	Baseline volume	% change	Baseline volume	% change
<b>Thalamus</b>	18.6 ± 1.3	-0.3 ± 1.2	17.1 ± 1.4	-1.4 ± 2.4	<b>0.003</b>	0.079
<b>Caudate</b>	8.5 ± 0.9	-1.4 ± 2.7	8.6 ± 1.1	-1.9 ± 5.9	0.977	0.849
<b>Putamen</b>	12.1 ± 1.3	0.4 ± 4.7	10.8 ± 1.9	-1.7 ± 7.2	0.076	0.232
<b>Pallidum</b>	4.5 ± 0.5	0.6 ± 4.7	4.4 ± 0.8	-1.5 ± 7.0	0.299	0.384
<b>Hippocampus</b>	10.3 ± 1.0	-0.5 ± 4.2	8.8 ± 1.3	-5.0 ± 6.4	<b>0.001</b>	0.009
<b>Amygdala</b>	3.7 ± 0.6	-1.7 ± 10.4	3.2 ± 0.6	0.9 ± 11.2	0.016	0.924
<b>Accumbens</b>	1.3 ± 0.2	-7.3 ± 17.9	0.9 ± 0.2	-6.3 ± 21.7	<b>0.003</b>	0.418

Total volumes (mean ± standard deviation) are reported in cm<sup>3</sup>. Results of the ANCOVA model are reported. p values where the model is significant after Bonferroni correction for multiple comparisons are highlighted in bold.

associated with memory ( $r = 0.483, p = 0.0016$ ) (Figure 2C) and visuospatial skills ( $r = 0.506, p = 0.001$ ) (Figure 2D). There were no significant findings when we used partial correlations corrected for age, sex, and education. No significant associations were found between change rates in subcortical volumes and cognitive tests. No significant correlations were observed in the aMCI group in terms of measures at baseline or change rate.

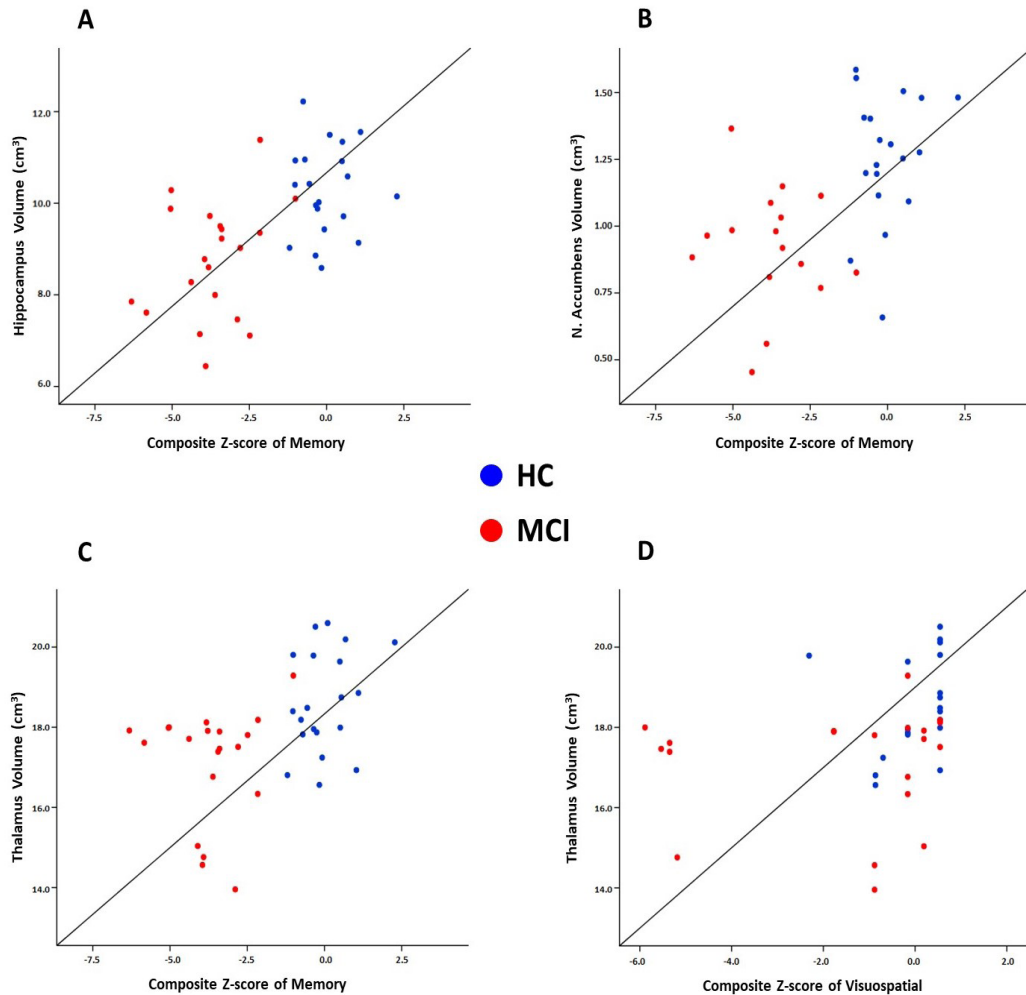
#### 4. Discussion

In this study, we assessed the longitudinal pattern of structural alterations in subcortical deep GM structures and investigated their relations with neurocognitive functions in patients with aMCI. Compared with normal aging controls, we found that among all seven pairs of structures, the thalamus, nucleus accumbens, and hippocampus volumes were significantly lower in aMCI patients at baseline. In addition, we also showed associations between these structures and cognitive composite scores. These results suggested that the atrophy of these three subcortical structures was associated with clinical impairment in aMCI patients, which might be useful in the evaluation and diagnosis of aMCI.

At present, the roles of subcortical structures in neurodegenerative pathophysiology and its effect on cognitive outcomes in patients with aMCI remain poorly understood. Previous cross-sectional imaging studies revealed varying degrees and significance of patterns of subcortical atrophy [8-10,25]. These findings indicate that there might be a specific subcortical atrophy pattern accompanied by a cognitive decline that can be early signs of aMCI. As expected, aMCI patients had significantly smaller hippocampal volumes in our study compared to cognitively normal subjects. We also showed a relation

between hippocampal atrophy and memory decline, which is in line with previous studies. The hippocampus is involved in episodic and semantic memory, which are commonly impaired in patients with aMCI [26]. Numerous structural MRI studies have consistently demonstrated greater hippocampal atrophy in aMCI and hippocampal atrophy is typically seen as the earliest hallmark of AD [27-30].

The thalamus is a critical deep brain structure with interactions across cortical areas serving various cognitive processes [31]. Thalamic nuclei as a relay station regulate cortical network interactions and coordinate switching between networks [32]. In the current study, our findings were on par with previous studies indicating that the thalamus was atrophied in aMCI compared to controls [33,34], comparable to that of the hippocampus. The thalamic atrophy was suggested to be the result of amyloid accumulation and axonal degeneration [35]. The anterior nucleus of the thalamus, as well as the hippocampus, is one of the earliest locations of tau accumulation in the forebrain [32]. As part of the Papez circuit, the anterior thalamus is connected to the hippocampus and posterior cingulate, two key nodes of the default mode network (DMN), and it plays an important role in memory processing [32,36]. DMN, which supports episodic memory, has consistently been identified as dysfunctional in MCI [37]. Previous studies have also supported the relationship between thalamic atrophy and memory decline [38,39]. Moreover, we also found an association between the thalamus and visuospatial skills. The pulvinar nucleus is the posterior part of the thalamus and has strong connectivity with several areas of the visual cortex via its connections with the posterior parietal cortex [40]. Electrophysiology studies have provided evidence that pulvinar plays an important



**Figure 2.** Scatter plots show the significant associations between subcortical volumes and composite scores of cognitive domains.

role in information transmission between visual cortical areas and visuospatial processing [41]. Taken together, the thalamus could be a possible subcortical neural substrate for cognitive impairment. Thus, thalamus atrophy may be used as another evaluation methodology for aMCI.

In line with the previous studies [7,8,25], the nucleus accumbens in our study were atrophied in aMCI and had an association with memory. The nucleus accumbens, located within the basal ganglia, can be affected in the early stages of AD and cause cognitive decline [42]. As a part of the limbic striatal loop, the nucleus accumbens contributes to memory and spatial learning with close connections with limbic structures of the prefrontal cortex, the amygdala, and the hippocampus [8]. The nucleus accumbens, the main component of the ventral striatum, receives a dense projection from the hippocampus and is involved in memory functions [43]. The previous study showed beta-amyloid deposition in the striatum in cognitively normal

elders, as well as changes in the structure and functional connection between the striatum and other brain regions in MCI patients [44,45]. Neuroimaging studies reported that the nucleus accumbens had smaller volumes even in the preclinical stages of dementia compared to normal cognition [7,8,46], and they revealed that the nucleus accumbens atrophy was associated with an increased risk of progression to AD dementia in MCI patients [7]. These findings indicated that in addition to the thalamus and hippocampus, the atrophy in the nucleus accumbens may also play an important role in clinical impairment in aMCI.

Longitudinal assessments can reduce the impact of individual differences in neuroimaging evaluations. Previous studies revealed that the value of longitudinal measures of brain shrinkage is more informative than that of cross-sectional estimates [47,48]. Therefore, measurements of atrophy rates of subcortical structures may be a more

practical and sensitive method to differentiate aMCI from controls. Moreover, there is a poor understanding of how longitudinal volume changes interact with cognitive performance. Atrophy rates were close between groups, in opposition to our hypothesis of greater atrophy rates in patients with aMCI than in controls. Contrary to the current study, several studies revealed a higher atrophy rate in the hippocampus [11,16,48-50] in aMCI patients than in the healthy group. Our negative findings may be due to the relatively small sample size of the aMCI group ( $n = 20$ ) and short follow-up duration (one year), which was likely not long enough to catch statistically significant differences in atrophy rates. However, it should be noted that there are also studies that reported no significant differences between MCI in comparison with healthy elderly subjects [30,51]. Possible explanations for these inconsistent findings among previous studies could be the result of using the different segmentation techniques or statistical procedures used in each study. In our volume analysis, the group effect was controlled for age, sex, and education, and the multiple comparison correction with Bonferroni correction was also performed.

Although aMCI demonstrated clinically stable cognitive performance over one year, we found a trend for a greater hippocampal atrophy rate in aMCI patients ( $p = 0.009$ ). This confirms our prediction of a higher atrophy rate being evident in aMCI subjects before they become aware of cognitive decline. The current findings suggest that monitoring longitudinal changes in hippocampal volume may differentiate age-related hippocampal damage from that associated with MCI. Hippocampal atrophy is not an AD-specific measure and is also present in patients with other neurodegenerative diseases such as hippocampal sclerosis, vascular dementia, and frontotemporal lobar degeneration, as well as in typical aging [52,53]. Therefore, hippocampal atrophy rate might be used as information in support of diagnostic evaluation for patients with aMCI. Furthermore, early detection of a greater hippocampal atrophy rate during healthy aging may help predict future MCI. It also provides a signal for future work in the development of biomarkers to clinically identify patients with aMCI.

The main strength of this study is the longitudinal design of a single cohort, which allows the examination of progression and clinical implications of subcortical GMV in patients with MCI. In addition, two groups were matched for age, sex, and educational level. Furthermore, all participants undertook a comprehensive neuropsychological assessment battery. Moreover, our findings were robust after applying multiple comparisons correction and considering the effects of age, sex, and education. To the best of our knowledge, the current study is the first investigation of the association between change rates in cognition and volumes of seven subcortical structures.

This study had some limitations. Patients who were not able to complete follow-up neurocognitive tests or MRI scanning led to decreased sample size. Due to our small sample size, our study may not be robust enough to determine the effect of longitudinal progression of subcortical atrophy in the aMCI group. Although this study's sample size is relatively low, it is similar to published studies that include groups with small sample sizes [16,51]. Furthermore, the mean follow-up period of one year may not have been sufficient. Studies with longer follow-up periods have been capable of capturing volumetric change rates [16,48,50]. In addition, due to the short follow-up duration, it is difficult to make the final diagnosis for MCI patients, some of these patients may revert to normal cognition, while some may later progress to AD dementia. Previous longitudinal studies have reported no difference in MCI patients who do not convert to AD dementia compared to controls [30,51]. Therefore, it is plausible to assume that stable MCI patients in our patient group probably diminish the change rate differences between controls and MCI. The effect of cognitive impairment on volumetric changes in subcortical structures in the brain needs to be further investigated in a larger sample over an extended follow-up duration.

In conclusion, this study highlights the potential of subcortical GMV analysis to demonstrate the structural abnormalities accompanying MCI and its association with cognitive decline to obtain imaging-based measures for monitoring the disease. Our study presents valuable data as decreased volumes in the hippocampus, nucleus accumbens, and thalamus at baseline in aMCI patients. Also, we found that the baseline volumes of the thalamus, nucleus accumbens, and hippocampus had positive correlations with memory. Additionally, the thalamus was associated with visuospatial skills. Our results indicate that the atrophy of these structures in MCI may provide further information related to the clinical features. Since these measures were associated with neurocognitive performance at baseline, volume measures might be useful for investigating cognitive impairment. In addition, the present study explored a trend for a greater hippocampal atrophy rate in aMCI patients over one year. Our longitudinal findings suggest that prospectively following the hippocampal atrophy rate could be an important indicator for early detection of MCI. A prospective study with a longer observation duration will provide more information on its usefulness in the clinical practice of MCI.

#### **Acknowledgment**

This study was supported by a grant from The Scientific and Technological Research Council of Türkiye (TÜBİTAK) under number 112S459. The results obtained in this study were not taken from a thesis.



**Informed consent**

Approval for the study was received from the Non-Invasive Research Ethics Board of Dokuz Eylül University (decision no: 2020/01-28). Informed consent was obtained from all individual participants included in the study.

**Conflict of interest**

The authors declare that they have no conflict of interest.

**References**

- Petersen RC, Smith GE, Waring SC, Ivnik RJ, Tangalos EG et al. Mild cognitive impairment: clinical characterization and outcome. *Archives of Neurology* 1999; 56 (3): 303-308. <https://doi.org/10.1001/archneur.56.3.303>
- Kim BS, Kim YB, Kim H. Discourse measures to differentiate between mild cognitive impairment and healthy aging. *Frontiers in Aging Neuroscience* 2019; 11: 221. <https://doi.org/10.3389/fnagi.2019.00221>
- Pinto C, Subramanyam AA. Mild cognitive impairment: the dilemma. *Indian Journal of Psychiatry* 2009; 51 (Supp 1): 44-51.
- Pini L, Pievani M, Bocchetta M, Altomare D, Bosco P et al. Brain atrophy in Alzheimer's disease and aging. *Ageing Research Reviews* 2016; 30: 25-48. <https://doi.org/10.1016/j.arr.2016.01.002>
- de Jong LW, van der Hiele K, Veer IM, Houwing JJ, Westendorp RG et al. Strongly reduced volumes of putamen and thalamus in Alzheimer's disease: an MRI study. *Brain* 2008; 131 (12): 3277-3285. <https://doi.org/10.1093/brain/awn278>
- Li W, Xie Y, Yu T, Wu W, Wang K et al. APOE ε4 allele modified the correlation between deep grey matter volume and cognitive performance in non-demented elders. *Chinese Journal of Academic Radiology* 2020; 3 (3): 152-161. <https://doi.org/10.1007/s42058-020-00043-1>
- Yi HA, Möller C, Dieleman N, Bouwman FH, Barkhof F et al. Relation between subcortical grey matter atrophy and conversion from mild cognitive impairment to Alzheimer's disease. *Journal of Neurology, Neurosurgery & Psychiatry* 2016; 87 (4): 425-432. <https://doi.org/10.1136/jnnp-2014-309105>
- Nie X, Sun Y, Wan S, Zhao H, Liu R et al. Subregional structural alterations in hippocampus and nucleus accumbens correlate with the clinical impairment in patients with Alzheimer's disease clinical spectrum: parallel combining volume and vertex-based approach. *Frontiers in Neurology* 2017; 8: 399. <https://doi.org/10.3389/fneur.2017.00399>
- Kälın AM, Park MTM, Chakravarty MM, Lerch JP, Michels L et al. Subcortical shape changes, hippocampal atrophy and cortical thinning in future Alzheimer's disease patients. *Frontiers in Aging Neuroscience* 2017; 9: 38. <https://doi.org/10.3389/fnagi.2017.00038>
- Zidan M, Boban J, Bjelan M, Todorović A, Vujančić TS et al. Thalamic volume loss as an early sign of amnesic mild cognitive impairment. *Journal of Clinical Neuroscience* 2019; 68: 168-173. <https://doi.org/10.1016/j.jocn.2019.07.004>
- Risacher SL, Shen L, West JD, Kim S, McDonald BC et al. Longitudinal MRI atrophy biomarkers: relationship to conversion in the ADNI cohort. *Neurobiology of Aging* 2010; 31 (8): 1401-1418. <https://doi.org/10.1016/j.neurobiolaging.2010.04.029>
- Whitwell JL. Progression of atrophy in Alzheimer's disease and related disorders. *Neurotoxicity Research* 2010; 18 (3): 339-346. <https://doi.org/10.1007/s12640-010-9175-1>
- Albert MS, DeKosky ST, Dickson D, Dubois B, Feldman HH et al. The diagnosis of mild cognitive impairment due to Alzheimer's disease: recommendations from the National Institute on Aging-Alzheimer's Association workgroups on diagnostic guidelines for Alzheimer's disease. *Alzheimer's & Dementia* 2011; 7 (3): 270-279. <https://doi.org/10.1016/j.jalz.2011.03.008>
- Morris J. The clinical dementia rating (CDR): current version and scoring rules. *Neurology* 1993; 43 (11): 2412-2414. <https://doi.org/10.1212/WNL.43.11.2412-a>
- Faul F, Erdfelder E, Lang AG, Buchner A. G\*Power 3: a flexible statistical power analysis program for the social, behavioral, and biomedical sciences. *Behavior Research Methods* 2007; 39 (2): 175-191. <https://doi.org/10.3758/BF03193146>
- Stoub TR, Rogalski EJ, Leurgans S, Bennett DA, deToledo-Morrell L. Rate of entorhinal and hippocampal atrophy in incipient and mild AD: relation to memory function. *Neurobiology of Aging* 2010; 31 (7): 1089-1098. <https://doi.org/10.1016/j.neurobiolaging.2008.08.003>
- Folstein MF, Folstein SE, McHugh PR. "Mini-mental state": a practical method for grading the cognitive state of patients for the clinician. *Journal of Psychiatric Research* 1975; 12 (3): 189-198. [https://doi.org/10.1016/0022-3956\(75\)90026-6](https://doi.org/10.1016/0022-3956(75)90026-6)
- Öktem Ö. A verbal test of memory processes. *Archives of Neuropsychiatry* 1992; 29: 196-206.
- Stroop JR. Studies of interference in serial verbal reactions. *Journal of Experimental Psychology: General* 1992; 121 (1): 15-23. <https://doi.org/10.1037/0096-3445.121.1.15>
- Kaplan E, Goodglass H, Weintraub S. Boston Naming Test. Pro-ed. 2001.
- Manos PJ, Wu R. The ten point clock test: a quick screen and grading method for cognitive impairment in medical and surgical patients. *The International Journal of Psychiatry in Medicine* 1994; 24 (3): 229-244. <https://doi.org/10.2190/5A0F-936P-VG8N-0F5R>

22. Patenaude B, Smith SM, Kennedy DN, Jenkinson M. A Bayesian model of shape and appearance for subcortical brain segmentation. *NeuroImage* 2011; 56 (3): 907-922. <https://doi.org/10.1016/j.neuroimage.2011.02.046>
23. Smith SM, Zhang Y, Jenkinson M, Chen J, Matthews PM et al. Accurate, robust, and automated longitudinal and cross-sectional brain change analysis. *NeuroImage* 2002; 17 (1): 479-489. <https://doi.org/10.1006/nimg.2002.1040>
24. McDonald JH. *Handbook of Biological Statistics*. 3rd ed. Baltimore, MD, USA: Sparky House Publishing; 2014.
25. Topkan TA, Erdogan N, Barutcu B, Cindil E, Tali ET et al. Volumetric assessment of hippocampus and subcortical gray matter regions in Alzheimer disease and amnesic mild cognitive impairment. *Cognitive and Behavioral Neurology* 2022; 35 (2): 95-103. <https://doi.org/10.1097/WNN.0000000000000296>
26. Serra L, De Simone MS, Fadda L, Perri R, Caltagirone C et al. Memory for public events in amnesic mild cognitive impairment: the role of hippocampus and ventro-medial prefrontal cortex. *Journal of Neuropsychology* 2022; 16 (1): 131-148. <https://doi.org/10.1111/jnp.12259>
27. Braak H, Braak E. Frequency of stages of Alzheimer-related lesions in different age categories. *Neurobiology of Aging* 1997; 18 (4): 351-357. [https://doi.org/10.1016/S0197-4580\(97\)00056-0](https://doi.org/10.1016/S0197-4580(97)00056-0)
28. McDonald CR, McEvoy LK, Gharapetian L, Fennema-Notestine C, Hagler DJ et al. Regional rates of neocortical atrophy from normal aging to early Alzheimer disease. *Neurology* 2009; 73 (6): 457-465. <https://doi.org/10.1212/WNL.0b013e3181b16431>
29. Fouquet M, Desgranges B, La Joie R, Rivière D, Mangin JF et al. Role of hippocampal CA1 atrophy in memory encoding deficits in amnesic mild cognitive impairment. *Neuroimage* 2012; 59 (4): 3309-3315. <https://doi.org/10.1016/j.neuroimage.2011.11.036>
30. Goerlich KS, Votinov M, Dicks E, Ellendt S, Csukly G et al. Neuroanatomical and neuropsychological markers of amnesic MCI: a three-year longitudinal study in individuals unaware of cognitive decline. *Frontiers in Aging Neuroscience* 2017; 9: 34. <https://doi.org/10.3389/fnagi.2017.00034>
31. Mukherjee A, Halassa MM. The associative thalamus: a switchboard for cortical operations and a promising target for schizophrenia. *The Neuroscientist* 2024; 30 (1): 132-147. <https://doi.org/10.1177/10738584221112861>
32. Fredericks CA, Brown JA, Deng J, Kramer A, Ossenkoppele R et al. Intrinsic connectivity networks in posterior cortical atrophy: a role for the pulvinar? *NeuroImage: Clinical* 2019; 21: 101628. <https://doi.org/10.1016/j.nicl.2018.101628>
33. Hahn C, Lee CU, Won WY, Joo SH, Lim HK. Thalamic shape and cognitive performance in amnesic mild cognitive impairment. *Psychiatry Investigation* 2016; 13 (5): 504. <https://doi.org/10.4306/pi.2016.13.5.504>
34. Li Y, Cong L, Hou T, Chang L, Zhang C et al. Characterizing global and regional brain structures in amnesic mild cognitive impairment among rural residents: a population-based study. *Journal of Alzheimer's Disease* 2021; 80 (4): 1429-1438. <https://doi.org/10.3233/JAD-201372>
35. Poulin SP, Dautoff R, Morris JC, Barrett LF, Dickerson BC. Amygdala atrophy is prominent in early Alzheimer's disease and relates to symptom severity. *Psychiatry Research: Neuroimaging* 2011; 194 (1): 7-13. <https://doi.org/10.1016/j.psychres.2011.06.014>
36. Sweeney-Reed CM, Buentjen L, Voges J, Schmitt FC, Zaehle T et al. The role of the anterior nuclei of the thalamus in human memory processing. *Neuroscience & Biobehavioral Reviews* 2021; 126: 146-158. <https://doi.org/10.1016/j.neubiorev.2021.02.046>
37. Aggleton JP, Pralus A, Nelson AJD, Hornberger M. Thalamic pathology and memory loss in early Alzheimer's disease: moving the focus from the medial temporal lobe to Papez circuit. *Brain* 2016; 139 (7): 1877-1890. <https://doi.org/10.1093/brain/aww083>
38. Aggleton JP, O'Mara SM, Vann SD, Wright NF, Tsanov M et al. Hippocampal-anterior thalamic pathways for memory: uncovering a network of direct and indirect actions. *European Journal of Neuroscience* 2010; 31 (12): 2292-2307. <https://doi.org/10.1111/j.1460-9568.2010.07251.x>
39. Forno G, Saranathan M, Contador J, Guillen N, Falgàs N et al. Thalamic nuclei changes in early and late onset Alzheimer's disease. *Current Research in Neurobiology* 2023; 4: 100084. <https://doi.org/10.1016/j.crneur.2023.100084>
40. Benarroch EE. Pulvinar: associative role in cortical function and clinical correlations. *Neurology* 2015; 84 (7): 738-747. <https://doi.org/10.1212/WNL.0000000000001276>
41. Eradath MK, Pinsk MA, Kastner S. A causal role for the pulvinar in coordinating task-independent cortico-cortical interactions. *Journal of Comparative Neurology* 2021; 529 (17): 3772-3784. <https://doi.org/10.1002/cne.25193>
42. Zhao Q, Du X, Chen W, Zhang T, Xu Z. Advances in diagnosing mild cognitive impairment and Alzheimer's disease using 11C-PIB- PET/CT and common neuropsychological tests. *Frontiers in Neuroscience* 2023; 17: 1216215. <https://doi.org/10.3389/fnins.2023.1216215>
43. Alexander GE, DeLong MR, Strick PL. Parallel organization of functionally segregated circuits linking basal ganglia and cortex. *Annual Review of Neuroscience* 1986; 9: 357-381. <https://doi.org/10.1146/annurev.ne.09.030186.002041>
44. Rodriguez-Vieitez E, Saint-Aubert L, Carter SF, Almkvist O, Farid K et al. Diverging longitudinal changes in astrocytosis and amyloid PET in autosomal dominant Alzheimer's disease. *Brain* 2016; 139 (3): 922-936. <https://doi.org/10.1093/brain/aww404>
45. Han SD, Arfanakis K, Fleischman DA, Leurgans SE, Tuminello ER et al. Functional connectivity variations in mild cognitive impairment: associations with cognitive function. *Journal of the International Neuropsychological Society* 2012; 18 (1): 39-48. <https://doi.org/10.1017/S1355617711001299>

46. Qin R, Li M, Luo R, Ye Q, Luo C et al. The efficacy of gray matter atrophy and cognitive assessment in differentiation of aMCI and naMCI. *Applied Neuropsychology: Adult* 2022; 29 (1): 83-89. <https://doi.org/10.1080/23279095.2019.1710509>
47. Raz N, Lindenberger U, Rodrigue KM, Kennedy KM, Head D et al. Regional brain changes in aging healthy adults: general trends, individual differences and modifiers. *Cerebral Cortex* 2005; 15 (11): 1676-1689. <https://doi.org/10.1093/cercor/bhi044>
48. Wei X, Du X, Xie Y, Suo X, He X et al. Mapping cerebral atrophic trajectory from amnesic mild cognitive impairment to Alzheimer's disease. *Cerebral Cortex* 2023; 33 (4): 1310-1327. <https://doi.org/10.1093/cercor/bhac137>
49. Henneman WJP, Sluimer JD, Barnes J, Van Der Flier WM, Sluimer IC et al. Hippocampal atrophy rates in Alzheimer disease: added value over whole brain volume measures. *Neurology* 2009; 72 (11): 999-1007. <https://doi.org/10.1212/01.wnl.0000344568.09360.31>
50. Wang PN, Liu HC, Lirng JF, Lin KN, Wu ZA. Accelerated hippocampal atrophy rates in stable and progressive amnesic mild cognitive impairment. *Psychiatry Research: Neuroimaging* 2009; 171 (3): 221-231. <https://doi.org/10.1016/j.psychres.2008.05.002>
51. Cardenas VA, Du AT, Hardin D, Ezekiel F, Weber P et al. Comparison of methods for measuring longitudinal brain change in cognitive impairment and dementia. *Neurobiology of Aging* 2003; 24 (4): 537-544. [https://doi.org/10.1016/S0197-4580\(02\)00130-6](https://doi.org/10.1016/S0197-4580(02)00130-6)
52. Coupé P, Catheline G, Lanuza E, Manjón JV. Towards a unified analysis of brain maturation and aging across the entire lifespan: a MRI analysis. *Human Brain Mapping* 2017; 38 (11): 5501-5518. <https://doi.org/10.1002/hbm.23743>
53. Harper L, Barkhof F, Scheltens P, Schott JM, Fox NC. An algorithmic approach to structural imaging in dementia. *Journal of Neurology, Neurosurgery & Psychiatry* 2014; 85 (6): 692-698. <https://doi.org/10.1136/jnnp-2013-306285>