

1-1-1998

Hüseyin Eray BULUT,Erdoğan GÜRSOY

An Ultrastructural Study

Follow this and additional works at: <https://journals.tubitak.gov.tr/medical>



Part of the [Medical Sciences Commons](#)

Recommended Citation

Study, An Ultrastructural (1998) "Hüseyin Eray BULUT,Erdoğan GÜRSOY," *Turkish Journal of Medical Sciences*: Vol. 28: No. 2, Article 3. Available at: <https://journals.tubitak.gov.tr/medical/vol28/iss2/3>

This Article is brought to you for free and open access by TÜBİTAK Academic Journals. It has been accepted for inclusion in Turkish Journal of Medical Sciences by an authorized editor of TÜBİTAK Academic Journals. For more information, please contact academic.publications@tubitak.gov.tr.

Hüseyin Eray BULUT
Erdoğan GÜRSOY

The Effect of Experimental Cryptorchidism on Rat Adrenal Cortex: An Ultrastructural Study

Received: November 25, 1996

Abstract: Cryptorchidism causes a failure in testosterone secretion from the testicles. The metabolism of the adrenocortical steroids is influenced by sex hormones. Therefore testicular failure may cause structural and functional alterations in adrenal cortex. It is the aim of the present study to evaluate the effect of experimental cryptorchidism on the ultrastructure of the rat adrenal cortex, especially on the reticularis region during prepubertal and postpubertal ages.

Three groups of animals were used in the present study. The first (prepubertal) group consisted of 5,21-day old rats whereas the second (postpubertal) group was made of 5,3-month old rats. Third group was the control group which had 5,6-month old normal animals. Testicles from each animal in experimental groups were pulled into the peritoneal cavity and fixed on the peritoneal wall. Following a 3 month period, all animals were killed and the adrenal glands were obtained from each animal. Adrenal cortical tissue were processed for electron microscopy, and

the ultrastructure of zona reticularis cells was evaluated using a JEOL 100C electron microscope.

In the prepubertal group, hypertrophic smooth endoplasmic reticulum (SER), a dramatic increase in tubular type mitochondrial size, and the number and size of the lipid droplets in reticularis cells were major findings of the present study. On the other hand, cellular structures of the rat adrenal cortex in the postpubertal group were similar to those seen in the control group.

These findings suggested a more changed cellular structure under the influence of experimental cryptorchidism in rats during prepubertal age. However, experimental cryptorchidism had no effect when performed in the postpubertal age.

Key Words: Cryptorchidism, adrenal cortex, ultrastructure

Department of Histology-Embryology,
Faculty of Medicine, Cumhuriyet University,
Sivas-Turkey

Introduction

Cryptorchidism occurs in childhood due to either testicular dysgenesis or malformation of the inguinal tract or insufficient gonadotrophin secretion (1). Cryptorchidism causes decreased amounts of steroid hormone secretion from the testicles (2,3). Disruption or damage to the seminiferous tubules by radiation, anti-androgen, vitamin A deficiency or experimental cryptorchidism causes Leydig cell hypertrophy and hyperplasia along with decreased steroidogenesis via the activation of some mitogenic factors that released from Sertoli cells (3).

Testicular dysfunction may cause structural and functional changes in the adrenal cortex since the adrenocortical function is under the control of gonads (4,5). Therefore the present study was designed to determine the effect of experimental cryptorchidism on

rat adrenocortical morphology at the electron microscope level.

Materials and Methods

A total number of 15 male Swiss albino rats were recruited in 3 groups each of which contained 5 animals. The control group consisted of 6-month old rats whereas the first experimental group contained 3-month old rats (postpubertal group) and the second experimental group had animals which were 21-day old (prepubertal group). All animals used in the present study were obtained from The Experimental Animal Laboratory, Cumhuriyet University, Sivas where they were bred and fed under standard laboratory conditions.

Experimental cryptorchidism was performed under

ether anaesthesia. Testicles of the animals were pulled into the peritoneal cavity and were fixed onto the peritoneal wall. After 3 months of feeding period, all animals were killed, and the adrenal glands from each animal were taken.

Tissues were fixed in 5 % glutaraldehyde (pH: 7.4) in phosphate buffer and postfixed in 1% osmium tetroxide in phosphate buffer. Following fixation, tissues were dehydrated at increasing concentrations of ethanol, then were embedded in Araldyte-CY212 resin (Spi-Chem, Structure Probe Inc., USA). Semi-thin and

ultra-thin sections were cut using an LKB IV ultratome (LKB, Bromma, Sweden). Ultra-thin sections were stained by uranyl acetate saturated in 70% ethanol and Reynolds' lead citrate (6). Tissue sections were evaluated using a JEOL 100C (Jeol, Japan) transmission electron microscope.

Results

Cellular characteristics of the control group zona reticularis were abundant tubular mitochondria, SER and lipid droplets (Figure 1) which are thought to be involved in the steroid hormone synthesis.




Figure 1. Electron micrograph shows the cellular characteristics of the zona reticularis (ZR) of the rat adrenal cortex in the control group. Tubular mitochondria (Mi), smooth endoplasmic reticulum (SER), lipid (L), nucleus (N), nucleolus (No), erythrocyte (Er). Mag. X7500

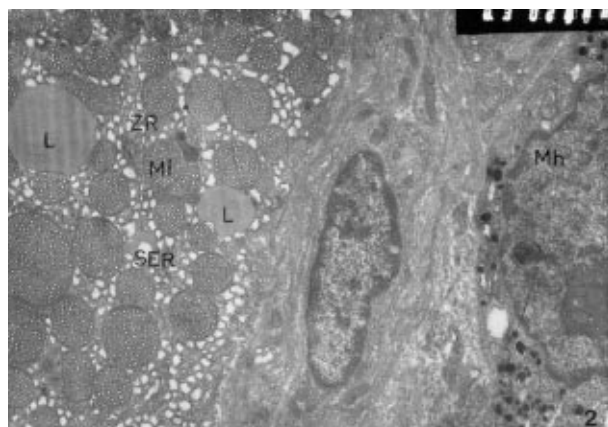


Figure 2. Cortico-medullary region of the rat adrenal gland from the prepubertal group. Hypertrophic SER membranes and increased lipid content (L) could be seen in cortical cells. Zona reticularis (ZR), medullar cell (Mc), mitochondria (mi).




Figure 3. Electron micrograph at higher magnification shows the increase in the size of the lipid droplet (L) in the prepubertal group rat adrenal cortical cells. Nucleus (N), smooth endoplasmic reticulum (SER), mitochondria (Mi). Mag. X 11000




Figure 4. Postpubertal group rat zona reticularis cells show structures similar to those seen in the control group. Zona reticularis (ZR), mitochondria (Mi), nucleus (N). Mag. X 11000.

Cells in the cortica-medullar region of the adrenal gland had abundant mitochondria in their cytoplasm which also contained hypertrophic SER membranes (Figure 2). The amount of SER membranes seemed to be increased due to experimental cryptorchidism when compared to the control group. In addition, the size and the number of lipid droplets increased in this group following 3 months of experimental cryptorchidism (Figure 3). This increased lipid content in zona reticularis was consistent with the increased amount of SER membranes which all together indicated an increased steroid synthesis and secretion from this region of the rat adrenal gland.

Zona reticularis had cellular features similar to those seen in the control group (Figure 4). Mitochondria were abundant and in normal morphology. SER membranes and lipid content in these cells were also similar to the control group, indicating an unchanged or possibly a restored cellular structure and function in the postpubertal group following a three months of experimental cryptorchidism.

Discussion

The mechanism(s) of the occurrence of cryptorchidism is still unclear. Testicular dysgenesis, inguinal tract malformations and insufficient gonadotrophin secretion are several implications of the spontaneous cryptorchidism (1). However, there is now good evidence that testicular descent occurs in two morphologically and hormonally distinct phases(7,8). Transabdominal migration of the testis occurs at 10-15 weeks of gestation in the human and inguino-scrotal migration occurs at 26-35 weeks of gestation (7). The first phase is suggested to be controlled by Mullerian inhibiting substance whereas the second phase is androgen dependent (7). Following experimental cryptorchidism, deformations of the germinal cells in the testis and interruption in meiotic and mitotic divisions have been shown (2). In addition, it has been suggested that these degenerative changes in germ cells and disruption of spermatogenesis occurs via apoptotic mechanisms (9). It has also been suggested that cryptorchidism could cause hyperplastic SER membranes, mitochondria and Golgi apparatus accompanied by decreased levels of steroid synthesis from Leydig cells (2).

Adrenocortical function is under the influence of gonads (4,5). It has been shown that the orchidectomy could cause an increase in thymus and adrenal gland weights (4,5,10,11). Therefore orchidectomy causes hypertrophy in adrenal cortex, especially in the zona reticularis (4,5,10).

In a stereological study, orchidectomy increased the cytoplasmic volume in zona fasciculata and reticularis regions (4). In the present study, similar findings, such as hypertrophic SER membranes, increased lipid content and so on, were observed in the prepubertal group. This may indicate that orchidectomy and cryptorchidism have similar effects on adrenocortical structure and function.

Similar to the cryptorchidism and orchidectomy, castration had similar effects on adrenal cortex (12). Cortical cellular components such as rough endoplasmic reticulum (RER), SER and mitochondria following castration (12). These findings also agreed with the results of the present study.

Cells of the zona fasciculata and zona reticularis of the female adrenal cortex had more mitochondria, SER and lipid than the male adrenal cortex (10). These authors suggested an inhibitory effect of testosterone on hypothalamo-pituitary-adrenal axis whereas oestrogen might induce proliferation (10).

It has been shown that 9 week after experimental cryptorchidism, Leydig cells regained their normal morphology, also plasma testosterone elevated to its normal level in adult male rats (13).

In the present study, hypertrophic cellular organelles of the zona reticularis seen in the prepubertal group may be due to delayed puberty which could cause decreased plasma testosterone level. On the other hand, normal cellular ultrastructure observed in the postpubertal group could be the result of restored plasma testosterone level which has been suggested to increase after 9 weeks of experimental cryptorchidism (13).

In conclusion, adrenocortical structure and function is closely related to the gonadal function, and this hypothesis has been proved morphologically by the present study.

References

1. Gendrel D, Roger M, Chaussain J L, Canlorbe P, Job JC. Correlation of pituitary and testicular responses to stimulation tests in cryptorchid children. *Acta Endocrinol.* 86 : 641,1977.
2. Aytekin Y. Siçan testislerinde deneysel ve spontan cryptorchidizmde görülen ışık ve elektronmikroskopik değişiklikler. Doktora Tezi I.U Tıp Fak. Basımevi No: 15, 1976.
3. Wu N., Murona E.P. A sertoli cell-secreted paracrine factor(s) stimulates proliferation and inhibits steroidogenesis of rat Leydig cells. *Mol. Cell. Endocrinol.* 106: 99-109, 1994.
4. Malendowicz L.K. Sex differences in adrenocortical structure and function. II. The effects of postpubertal gonadectomy and gonadal hormone replacement on the rat adrenal cortex evaluated by stereology at the light microscope level. *Cell Tissue Res.* 151: 537, 1974.
5. Kubota K., Suzuki M. Note: The effects of orchietomy and androgen supplement on the adrenal cortex and medulla of rats. *Endocrinol. Japon.* 21: 167, 1974.
6. Reynolds E.A. The use of pH as an electron-opaque stain in electron microscopy. *J. Cell Biol.* 17: 208, 1963.
7. Hutson J.M., Baker M., Terada M., Zhou B., Paxton G. Hormonal control of testicular descent and the cause of cryptorchidism. *Reprod. Fertil. Dev.* 6 : 151-156, 1994.
8. Van der Schoot P. Doubts about the first phase of testis descent in the rat as a valid concept. *Anat. Embryol.* 187: 203-208, 1993.
9. Shikone T., Billig H., Hsueh A.J. Experimentally induced cryptorchidism increases apoptosis in rat testis. *Biol. Reprod.* 51: 865-872, 1994.
10. Malendowicz L.K., Robba C., Nussdorfer G.G. Sex differences in adrenocortical structure and function. XXII. Light and electron microscopic morphometric studies on the effects of gonadectomy and gonadal hormone replacement on the rat adrenal cortex. *Cell Tissue Res.* 224: 141, 1986.
11. Malendowicz L.K. Sex differences in adrenocortical structure and function. V. The effects of postpubertal gonadectomy and gonadal hormone replacement on nuclear cytoplasmic ratio, morphology and histochemistry of rat adrenal cortex. *Folia Histochem. Cytochem.* 17: 195, 1979.
12. Nickerson P.A. Short communication. Stimulation of the adrenal gland of the Mongolian gerbil after ovariectomy. *Cell Tissue Res.* 165: 155, 1975.
13. Jones T.M., Anderson W., Fang V.S., Landau R.L., Rosenfield R.I. Experimental cryptorchidism in adult male rats: Histological and hormonal sequel. *Anat. Record* 189: 1,1977.