

1-1-1998

## Translocation 13;14 Associated With Myelodysplastic Syndrome in Down's Syndrome

Gül SAPMAZ

Ferda ÖZKINAY

Hasan YÜKSEL

Cihangir ÖZKINAY

Figen AKDENİZLİOĞLU

*See next page for additional authors*

Follow this and additional works at: <https://journals.tubitak.gov.tr/medical>



Part of the [Medical Sciences Commons](#)

---

### Recommended Citation

SAPMAZ, Gül; ÖZKINAY, Ferda; YÜKSEL, Hasan; ÖZKINAY, Cihangir; AKDENİZLİOĞLU, Figen; TOPÇUOĞLU, Nejat; and ÖZTOP, Şenay (1998) "Translocation 13;14 Associated With Myelodysplastic Syndrome in Down's Syndrome," *Turkish Journal of Medical Sciences*: Vol. 28: No. 6, Article 7. Available at: <https://journals.tubitak.gov.tr/medical/vol28/iss6/7>

This Article is brought to you for free and open access by TÜBİTAK Academic Journals. It has been accepted for inclusion in Turkish Journal of Medical Sciences by an authorized editor of TÜBİTAK Academic Journals. For more information, please contact [academic.publications@tubitak.gov.tr](mailto:academic.publications@tubitak.gov.tr).

---

## Translocation 13;14 Associated With Myelodysplastic Syndrome in Down's Syndrome

### Authors

Gül SAPMAZ, Ferda ÖZKINAY, Hasan YÜKSEL, Cihangir ÖZKINAY, Figen AKDENİZLİOĞLU, Nejat TOPÇUOĞLU, and Şenay ÖZTOP

Gül SAPMAZ<sup>1</sup>  
Ferda ÖZKINAY<sup>2</sup>  
Hasan YÜKSEL<sup>2</sup>  
Cihangir ÖZKINAY<sup>2</sup>  
Figen AKDENİZLİOĞLU<sup>3</sup>  
Nejat TOPÇUOĞLU<sup>3</sup>  
Senay ÖZTOP<sup>2</sup>

## Translocation 13;14 Associated With Myelodysplastic Syndrome in Down's Syndrome

Department of <sup>1</sup>Medical Biology, <sup>2</sup>Pediatrics,  
Faculty of Medicine, Ege University, <sup>3</sup>Yenişehir  
Teaching Hospital, Department of Pediatrics;  
Izmir-Turkey

Received: March 11, 1996

**Key Words:** Down's syndrome,  
myelodysplastic syndrome, translocation.

Extensive epidemiological studies investigating Down's syndrome have shown an association between cancer and Down's syndrome (1-3). The most common cancers seen in children with Down's syndrome are acute leukemias. Myelodysplastic syndrome is a rare hematological disorder in childhood, which can lead to acute leukemia.

In this paper, we report on a child with Down's syndrome who was diagnosed as having myelodysplastic syndrome. He also has Robertsonian translocation between chromosome 13 and 14(t(13q;14q)), inherited from the mother.

H.Ö., a 14-year-old boy, was the ninth child of the family. When he was born his mother was 22 years old. She had had four previous abortions and four previous healthy children. The pregnancy and delivery occurred without complications. In the newborn period, by clinical findings he was diagnosed as having Down's syndrome. His motor and mental development were retarded. One and a half years ago he was examined by the hematology department of another hospital for his pallid appearance and fatigue. During that period his CBC showed anemia and mild leukopenia (2800/mm<sup>3</sup>). The cause of anemia was considered to be nutritional deficiency because of the low levels of serum iron and ferritin. He was given iron orally but his anemia did not respond to therapy for several months. Subsequent CBCs performed at monthly intervals for one year showed refractory anemia, leukopenia and thrombocytopenia. During that year bone marrow examinations showed hypercellularity in all series of cells. He was referred to our hospital for further examination.

On admission his weight was 35 kg (25th-50th centile), height 142 cm (25th-50th centile), head circumference 50 cm (10th-25th centile). He had the

typical symptoms of Down's syndrome such as upslanting palpebral fissures, hypertelorism, depressed nasal bridge, geographical tongue, high-arched palate, dental malocclusion, simian creases and clinodactyly in the hands. The liver and spleen were 3 cm and 2 cm the costal margin, respectively.

Laboratory tests revealed profound anemia (Hb: 5.9 gm/dl, Hct: 21.9%, MCV: 79), leukopenia (1900/mm<sup>3</sup>), thrombocytopenia (90 000/mm<sup>3</sup>). The distribution of peripheral blood cells was normal for his age group. The erythrocyte sedimentation rate, blood electrolytes, liver function tests, thyroid function tests and ECG were normal. Serum iron and iron binding capacity were found to be 25 gamma, and 308 gamma, respectively. Both of them showed iron-deficiency anemia. The serum ferritin level was lower than normal, 3 ng/ml. Bone marrow aspiration and biopsy showed hypercellularity and micromegakaryocytosis. No abnormality was observed in the examination of bone marrow with cytochemical stain for iron. Karyotyping studies revealed that the patient has 46,XY, t(13;14), +21(Fig.1) and the mother and one of the siblings were the carriers of t(13;14).

According to the FAB classification, myelodysplastic syndromes have five categories: refractory anemia (RA), refractory anemia with ringed sideroblast (RARS), refractory anemia with excess blasts (RAEB), refractory anemia with excess blasts in transformation (RAEB-t) and chronic myelomonocytic leukemia (CMML). The syndromes are most common in patients over 50 and are quite rare in childhood (4). In patients with myelodysplastic syndrome, peripheral blood tests show the symptoms of bone marrow failure such as anemia, neutropenia and/or thrombocytopenia. However, bone marrow cellularity is usually normal to increased. Excessive reticulin is present in most cases (4).

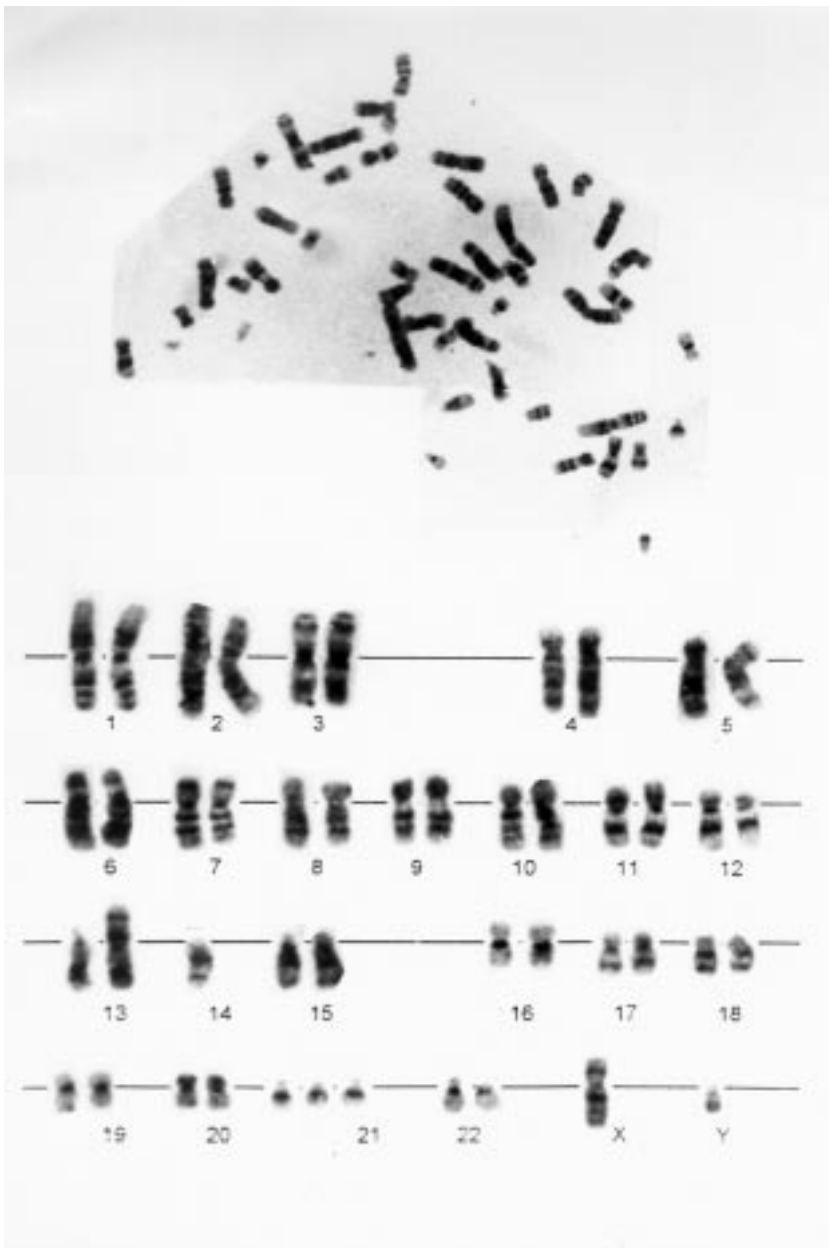


Figure 1. Karyotyping of patient.

The patient discussed here was diagnosed as having first category myelodysplastic syndrome in addition to Down's syndrome. He had the typical peripheral blood counts and bone marrow findings for myelodysplastic syndrome. Despite his refractory anemia he had hypercellular bone marrow. This is an example of relative bone marrow failure, which is one of the characteristics of myelodysplastic syndrome (4). Micromegakaryocytic changes are also common in myelodysplastic syndrome. Megakaryocytic changes may be in size, nuclear to cytoplasmic ratio and nuclei (4). In our patient micromegakaryocytosis was observed. There were no

ringed sideroblasts or blastic transformations which indicate a more progressive form of myelodysplastic syndrome in bone marrow examination.

Nair et al. reported on 16 children with myelodysplastic syndrome, one of which had regular Down's syndrome (5). Homans et al. described a unique myelodysplastic syndrome in children with Down's syndrome (6). In their study of 95 children, 27% of the patients died, 33% of the patients developed subsequent hematological disorders, most often acute leukemias (5). Leukemic transformation, however, is not inevitable,

myelodysplastic syndromes are usually classified as preleukemic (4). Although the frequencies of leukemias are different in different studies, megakaryoblastic leukemia (M7) is much more common in children with Down's syndrome than in normal children (7, 8, 9, 10). In our study micromegakaryocytosis found in bone marrow may be one of the signs of myelodysplastic syndrome.

Karyotyping studies of the patient (Figure 1), his mother and one of his siblings exhibited t(13;14). A number of cases with the same circumstances have been reported (11, 12). Whether the balanced Robertsonian translocations make the child predisposed to Down's syndrome is controversial. In our opinion, the case

presented here, would appear to support this hypothesis. Although our case has two different types of chromosomal abnormality, we believe that trisomy 21 is the causative factor and t(13;14), found in our patient, we consider to be a coincidental chromosomal abbreviation. To our knowledge no cases have been reported showing t(13;14) in conjunction with myelodysplastic syndrome. However many cases have been reported with both hematological abnormalities and trisomy 21.

*Correspondence author:*

*Ferda ÖZKINAY*

## References

- Mann JR, Dodd HE, Draper GJ, Waterhouse JA, Birch JM, Cartwright RA, Hartley AL, Mc Kinney PA, Stiller CA: Congenital abnormalities in children with cancer and their relatives: Results from a case-control study (IRESCC). *Br J Cancer* 68(2): 357-63, 1993.
- Milli F, Lynch CF, Khoury MJ, Flanders WD, Edmonds LD: Risk of childhood cancer for infants with birth defects. II A record-linkage study, IOWA, 1983-1989. *Am J Epidemiol* 137(6): 637-44, 1993.
- Milli F, Khoury MJ, Flanders WD, Greenberg RS: Risk of childhood cancer for infants with birth defects. I A record-linkage study. Atlanta, Georgia 137(6): 629-38, 1993.
- Grier HE: Chronic myeloproliferative disorders and myelodysplasia. In: *Hematology*. Ed by Oski N. B Saunders Company. 1075-78, 1987.
- Nair R, Athale UA, Lyer RS, Nair CN, Pai SK, Kurkure PA, Kadam PR, Advani SH: Childhood myelodysplastic syndromes: Clinical features, cytogenetics and prognosis. *Indian J Pediatr* 59(4): 443-8, 1992.
- Homans AC, Verrisimo AM, Vlacha V: Transient abnormal myelopoiesis of infancy associated with trisomy 21. *Am J Pediatr Hematol Oncol* 15(4): 392-9, 1993.
- Hecht F, Hecht BK, Morgan R, Sandberg AA, Link MP: Chromosome clues to acute leukemia in Down syndrome. *Cancer Genet Cytogenet* 21(2): 93-8, 1986.
- Kojima S, Matsuyama T, Sato T, Horiba K, Konishi S, Tauchida M, Hayashi Y, Kigasava H, Akiyama Y, Okamura J: Down's syndrome and acute leukemia in children: an analysis of phenotype by use of monoclonal antibodies and electron microscopic platelet peroxidase reaction. *Blood* 76(11): 2348-53, 1990.
- Hayashi Y, Hanado R, Yamamoto K: Chromosome abnormalities and prognosis in childhood acute leukemia. *Acta Paediatr Jpn* 33(4): 497-506, 1991.
- Suarez CR, Le Beau MM, Silberman S, Fresco R, Rowley JD: Acute megakaryoblastic leukemia in Down's syndrome. Report of a case and review of cytogenetic findings. *Med Pediatr Oncol* 13(4): 225-31, 1985.
- Sudha T, Jayam S, Ramachandran R: The association of t(13q;14) with Down's syndrome and its inheritance. *Indian J Pediatr* 57(2): 249-52, 1990.
- Frag TI, Krishna Murty DS, Al-AWadi SA, Sundereshan TS, Ai-Othman, SA, Mady SA, Redna MA: Robertsonian translocation t dic(14p;22p) with regular trisomy 21: a possible interchromosomal effect. *Ann Genet* 30(3): 189-92, 1987.