

1-1-1999

The Effect of Race on the Exposure of the Internal Auditory Canal Via the Retrosigmoid Approach in Turkish Subjects

ENİS ALPİN GÜNERİ

HANDAN ÇAKMAKÇI

AHMET ÖMER İKİZ

KERİM CERYAN

Follow this and additional works at: <https://journals.tubitak.gov.tr/medical>



Part of the [Medical Sciences Commons](#)

Recommended Citation

GÜNERİ, ENİS ALPİN; ÇAKMAKÇI, HANDAN; İKİZ, AHMET ÖMER; and CERYAN, KERİM (1999) "The Effect of Race on the Exposure of the Internal Auditory Canal Via the Retrosigmoid Approach in Turkish Subjects," *Turkish Journal of Medical Sciences*: Vol. 29: No. 2, Article 16. Available at: <https://journals.tubitak.gov.tr/medical/vol29/iss2/16>

This Article is brought to you for free and open access by TÜBİTAK Academic Journals. It has been accepted for inclusion in Turkish Journal of Medical Sciences by an authorized editor of TÜBİTAK Academic Journals. For more information, please contact academic.publications@tubitak.gov.tr.

Enis Alpin GÜNERİ¹
Handan ÇAKMAKÇI²
Ahmet Ömer İKLİZ¹
Kerim CERYAN¹

The Effect of Race on the Exposure of the Internal Auditory Canal Via the Retrosigmoid Approach in Turkish Subjects

Received: October 27, 1997

Departments of ¹Otolaryngology,
²Radiodiagnosics, Faculty of Medicine,
Dokuz Eylül University, Izmir-Turkey

Abstract: Hearing conservation in acoustic neuroma surgery via the retrosigmoid approach depends upon a good exposure of the internal auditory canal from behind avoiding labyrinthine injury. The accessibility is influenced largely by the individual characteristics of the temporal bone and the variability of the surgical landmarks is the result of different skull base shapes among different races. The aim of this study was to evaluate the effect of race on the exposure of the internal auditory canal of Turkish subjects via the retrosigmoid approach. Axial temporal bone CT scans of 40 Turkish

individuals were studied by measuring the relevant parameters and the results were statistically analysed and compared with those reported previously for Chinese and Europeans (3). The results showed significant differences in the position of the sigmoid sinus, orientation of the petrous bone and posterior fossa dimensions. This led to the conclusion that a bigger craniotomy is needed in Turkish individuals than in Chinese and Europeans.

Key Words: Craniometry, internal auditory canal, race, retrosigmoid approach.

Introduction

Since the common use of Magnetic Resonance Imaging (MRI) has resulted in early diagnosis of small acoustic neuromas in ears with good hearing, an increased number of patients are now considered suitable for hearing conservation surgery via the retrosigmoid approach.

Craniotomy size is important in the retrosigmoid approach, a small craniotomy results in a narrow angle of exposure of the internal auditory meatus (IAM) without breaching the labyrinth, a large craniotomy requires marked cerebellar retraction that may result in significant injury (1, 2, 3). In addition, there is a substantial interindividual variability of the surgical landmarks; the geometrical relationship between the fundus and the labyrinth seems to be the most important determinant of this variability.

Since it was reported that there were significant differences in the dimensions of the posterior cranial fossa between Chinese and Europeans and a larger craniotomy was required in Europeans (3), we aimed to evaluate the importance of race on the craniotomy size in

Turkish subjects and compared our results with those obtained previously.

Materials and Methods

Forty healthy Turkish individuals were studied; there were 24 females and 16 males, the ages were between 2 and 81 (mean: 35). Axial High Resolution Computed Tomography (CT) scans (GE Hi-light Advantage Unit, General Electric, Milwaukee) of the temporal bones were obtained in a plane passing through the common crus of the vestibule. CT scans were 1 millimeter in thickness with 3 millimeter gaps between the slices. All of the scans were examined using the bone algorithm.

The measurements were obtained with the on screen capability of the software (Figure 1 and Figure 2). They were, the line (L) drawn to join the tip of Bill's bar at the lateral end of the IAM to the edge of the common crus and projected backwards to the occipital bone; the distance (D) in millimeters from the point of occipital intersection of L to the posterior border of the sigmoid sinus; the best line of fit (F) along the posterior border of the petrous bone; the acute angle (A) in degrees between

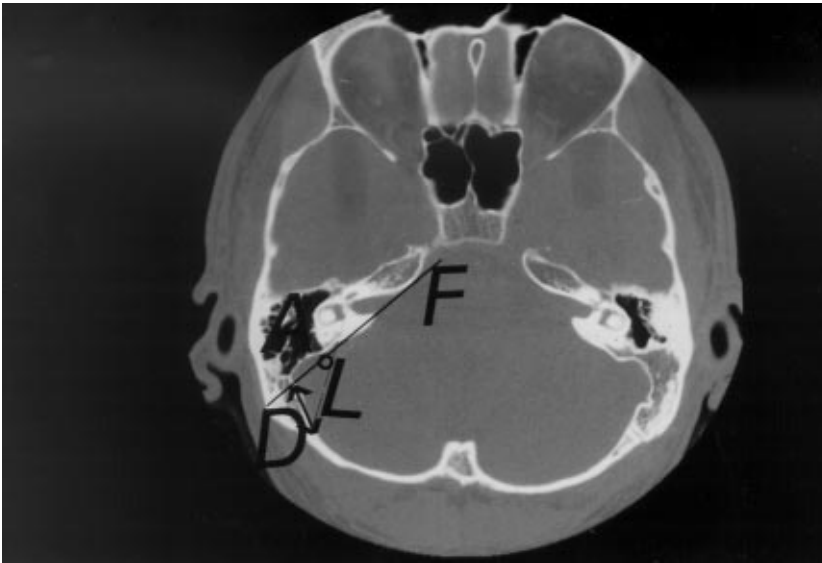


Figure 1. CT scan of the right temporal bone showing the distance D, line L, line F and angle A.

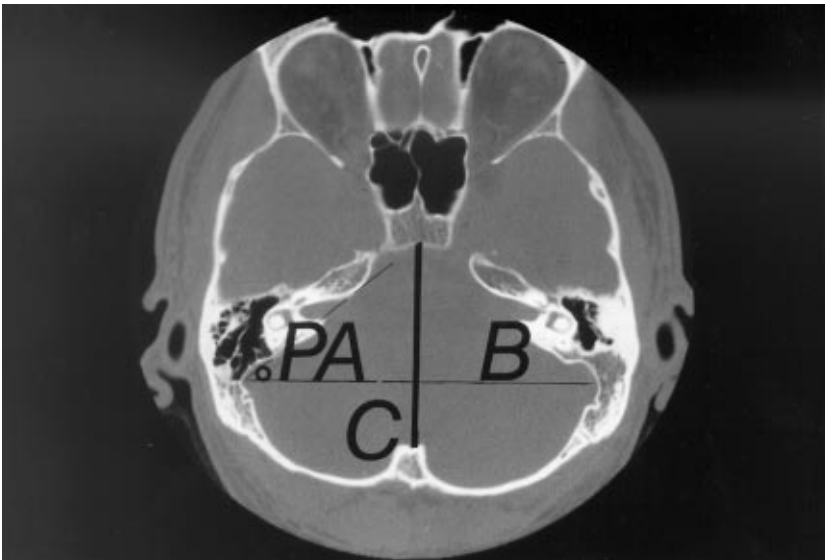


Figure 2. CT scan of the posterior cranial fossa showing the PA and PFI (the ratio of B/Cx100).

L and F, the petrous angle (PA) in degrees between F and the coronal plane and the posterior fossa index (PFI) which is the ratio of maximum breadth (B) and length (C) of the posterior cranial fossa x 100 (3).

The measurements D, PA and PFI were compared with those obtained previously, reporting the significantly different data of Chinese and European races (3). Student's *t* test was used in the comparison, and multivariate linear regression analysis was performed for angle A and distance D in Turkish individuals.

Results

The results of the CT measurements obtained from Turkish individuals are shown in Table 1. In Turkish

individuals, D was found to be significantly shorter than in Europeans ($p: 0.00043$) but not different from Chinese ($p: 0.074$). PA was significantly higher than in both Europeans and Chinese ($p: 0.00045$ and $p: 0.00036$). PFI was found to be significantly higher than in Europeans ($p: 0.00046$) but it was not different from in Chinese ($p: 0.00087$) (Table 2).

The results were also evaluated in order to examine the influence of sex (Table 3). It was found that in Turkish subjects the measurements D, PA and PFI were significantly lower in females than in males ($p: 0.00043$). Multivariate linear regression analysis showed that there is a positive relationship between distance D and angle A ($p: 0.0010$, $r: 0.77$).

Table 1. Posterior fossa CT measurement parameters in Turkish people.

	RANGE		
	MEAN	LOW	HIGH
A (degrees)	36.4±6.53	27	54
D (millimeters)	1.95±0.57	0.8	3.4
PA (degrees)	45.85±5.47	32	57
PFI	150.75±11.62	126.50	169.70

A: The acute angle between L and F, D: the distance from the point of occipital intersection of L to the posterior border of the sigmoid sinus, PA: the petrous angle between F and the coronal plane, PFI: the ratio of maximum breadth (B) and length (C) of the posterior cranial fossa x100.

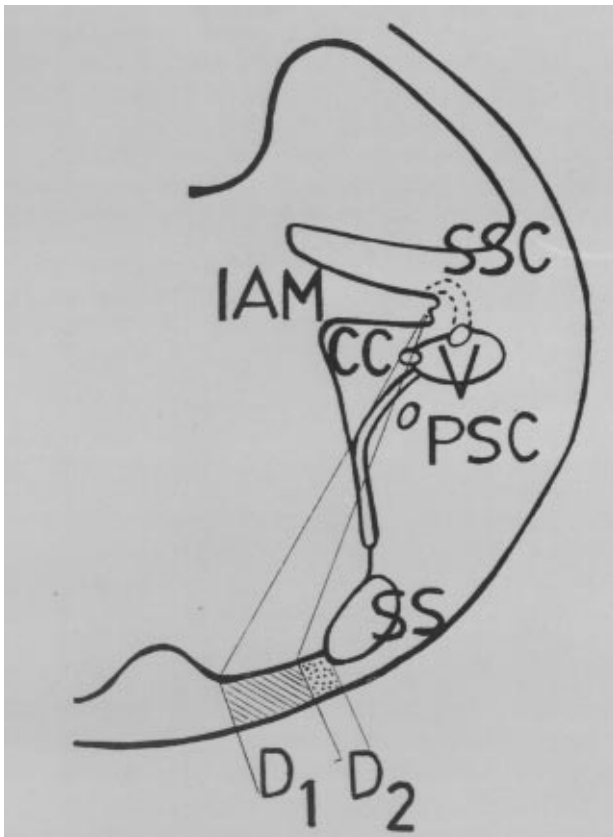


Figure 3. Schematic illustration demonstrating how a large craniotomy (D1) avoids labyrinthine injury in contrast to a small craniotomy (D2) used in the retrosigmoid approach (IAM: Internal auditory meatus, SSC: Superior semicircular canal, CC: Common crus, V: Vestibule, PSC: Posterior semicircular canal, SS: Sigmoid sinus).

Table 2. The comparison of the posterior fossa measurement parameters D, PA and PFI between Turkish, European and Chinese people.

	TURKISH	EUROPEAN	CHINESE
D (millimeters)	1.95±0.57	2.46±0.46	1.70±0.64
PA (degrees)	45.85±5.47	41.56±3.16	37.71±5.52
PFI	150.75±11.62	140.09±9.21	146.38±13.78

D: the distance from the point of occipital intersection of L to the posterior border of the sigmoid sinus, PA: the petrous angle between F and the coronal plane, PFI: the ratio of maximum breadth (B) and length (C) of the posterior cranial fossa x100.

Discussion

Hearing conservation in acoustic neuroma surgery is a difficult task, and complete familiarity with the anatomy and use of all available landmarks are required for successful tumor removal.

Tumors of the IAC and cerebellopontine angle may be removed with preservation of serviceable hearing through the retrosigmoid approach via a suitably sized craniotomy. However, anatomical studies have shown that it was impossible to expose the lateralmost recess of the IAC through this route without injury to the labyrinth (2, 4). Direct neural injury, disruption of the blood supply, and surgical entry into the labyrinth upon removal of the posterior wall of the IAC are likely to result in permanent sensorineural hearing loss (4).

The recommended size of the optimal craniotomy in the retrosigmoid approach was reported to be more than 3 cm (5), 4.0-4.5 cm (6) and 5 cm (7). The larger the craniotomy, the more favorable is the angle of approach and the longer IAC wall may be exposed (Figure 3). A four centimeter craniotomy size was reported to result in a 30 to 40 degree of approach angle which is sufficient to remove a full two-thirds of the posterior IAC wall without damage to the labyrinth (2). Also, every centimeter of cerebellar retraction affords 1 millimeter greater access to the IAC or approximately and additional 10% exposure of the IAC's total length (1).

CT is a useful modality to assess the cephalometric landmarks; the difference between the estimated and true landmark was reported to be significantly high when cephalograms were used for the evaluation (8) but excellent agreement was found between them using CT (9).

Table 3. Evaluation of the posterior fossa measurement parameters D, PA and PFI obtained from Turkish people with regard to sex.

	FEMALE	MALE
D (millimeters)	1.65±0.58	2.50±0.47
PA (degrees)	38.61±5.45	47.86±5.64
PFI	143.72±11.46	163.80±12.06

D: the distance from the point of occipital intersection of L to the posterior border of the sigmoid sinus, PA: the petrous angle between F and the coronal plane, PFI: the ratio of maximum breadth (B) and length (C) of the posterior cranial fossax100.

The exposure of the IAC wall through the retrosigmoid approach was reported to be safely accomplished medial to an imaginary line drawn on an axial CT scan from the posterior and medial aspect of the sigmoid sulcus passing through the fundus tangential to the structures of the bony labyrinth (1, 10). The surgeon must rely on measurements obtained from individual CT scans to define the anatomy of each patient as to how far laterally the IAC may be opened without compromising the labyrinth (1, 2, 11, 12).

The shape and size of the cranial base is related to the facial length and other maxillofacial morphologic features in all species including humans (13). Anthropologically, there is a limited variation in modern humans among major geographic regions (14), and the race and sex of the human skull can be determined by craniometry (15, 16). All humans have approximately equal skull capacities (17) in spite of the differences in the size, shape and structure of the cranium (16).

References

1. Blevins NH, Jackler RK. Exposure of the lateral extremity of the internal auditory canal through the retrosigmoid approach: A radioanatomic study. *Otolaryngol Head Neck Surg* 111: 81-90, 1994.
2. Day DJ, Kellogg JX, Fukushima T, Giannotta SL. Microsurgical anatomy of the inner surface of the petrous bone: Neuroradiological and morphometric analysis as an adjunct to the retrosigmoid transmetal approach. *Neurosurgery* 34: 1003-8, 1994.
3. Low WK, Fentol JE, Fagan PE, Gibson WPR. Racial considerations in acoustic neuroma removal with hearing preservation via the retrosigmoid approach. *Acta Otolaryngol (Stockh)* 115: 783-86, 1995.

Since there are no uniform criteria regarding the angle of approach to the IAC or the length of the posterior IAC wall that may be removed safely (2); it becomes clear that a recommended craniotomy size may not be suitable for a patient from a different race.

The racial factor should be considered in recommending an optimal size for a retrosigmoid craniotomy to remove acoustic neuromas completely whilst preserving hearing. It was reported that a larger craniotomy was required in Europeans than in Chinese with the explanation that the petrous angle was greater in Europeans possibly accounting for the difference in the appropriate craniotomy sizes (3).

Our results indicate that the significantly shorter D in Turkish subjects may either be due to the more posterior displacement of the sigmoid sinus or the more anterior localization of the temporooccipital suture line. The second characteristic is the significantly wider PA in Turkish subjects pointing to a more laterally rotated petrous bone. Also the significantly higher PFI may reflect the greater breadth or shorter length of the posterior cranial fossa of the population studied.

The positive relationship between D and A (3) was confirmed in our study; if the distance D becomes longer then angle A increases and vice versa. Therefore, for a given angle of approach to reach the lateral end of the IAC, a bigger craniotomy is needed in Turkish subjects than in Europeans and Chinese, but its size may be smaller for female Turkish patients.

We think that in light of this information, it will be possible to more accurately predict the probability of success of the retrosigmoid approach in Turkish people. More hearing preservation will obviously be achieved by properly analyzing the size of the craniotomy sufficient to visualize the depth of tumor penetration into the IAC.

4. Domb GH, Chole RA. Anatomical studies of the posterior petrous apex with regard to hearing preservation in acoustic neuroma removal. *Laryngoscope* 90: 1769-76, 1980.
5. Glasscock III ME, Poe DS, Johnson GD. Hearing preservation in surgery of cerebellopontine angle tumors. In: Fisch U, Valavanis A, Yaşargil MG, eds. *Neurological Surgery of the Ear and Skull Base*. Amstelveen, Kugler & Ghedini, pp: 207-16, 1989.
6. Maniglia AJ, Fenstermaker RA, Ratcheson RA. Preservation of hearing in the surgical removal of cerebellopontine angle tumors. *Otolaryngol Clin N Am* 22: 211-32, 1989.
7. Smith MFW. Retrosigmoid approach. In: Fisch U, Valavanis A, Yaşargil MG, eds. *Neurological Surgery of the Ear and Skull Base*. Amstelveen, Kugler & Ghedini, pp: 187-96, 1989.
8. Tng TT, Chan TC, Hägg U, Cooke MS. Validity of cephalometric landmarks. An experimental study on human skulls. *Eur J Orthod* 16: 110-20, 1994.
9. Waitzman A, Posnick JC, Armstrong DC, Pron GE. Craniofacial skeletal measurements based on computed tomography: Part I. Accuracy and reproducibility. *Cleft Palate Craniofac J* 29: 112-17, 1992.
10. Tatagiba M, Samii M, Matthies C, El Azm ME, Schonmayr R. The significance for postoperative hearing of preserving the labyrinth in acoustic neuroma surgery. *J Neurosurg* 77: 677-84, 1992.
11. Berlis A, Putz R, Schumacher M. Direct and CT measurements of canals and foramina of the skull base. *Br J Radiol* 65: 653-61, 1992.
12. Ronald PS, Meyerhoff WL, Wright CG, Mickey B. Anatomic considerations in the posterior approach to the internal auditory canal. *Ann Otol Rhinol Laryngol* 97: 621-25, 1988.
13. Kasai K, Moro T, Kanazawa E, Iwasawa T. Relationship between cranial base and maxillofacial morphology. *Eur J Orthod* 17: 403-10, 1995.
14. Relethford JH. Craniometric variation among modern human populations. *Am J Phys Anthropol* 95: 53-62, 1994.
15. Johnson DR, O'Higgins P, Moore WJ, McAndrew TJ. Determination of race and sex of the human skull by discriminant function analysis of linear and angular dimensions. *Forensic Sci Int* 41: 41-53, 1989.
16. Ross MD, Lee KA, Castle WM. Skull thickness of black and white races. *S Afr Med J* 50: 635-38, 1976.
17. Gould SJ. Morton's ranking of races by cranial capacity. Unconscious manipulation of data may be a scientific norm. *Science* 200: 503-9, 1978.