

1-1-1999

Autosomal Dominant Osteopetrosis Type II

KAZIM ŐENEL

SİNAN SÖNMEZ

LALE CERRAHOĐLU

MAHİR UĐUR

SELAMİ SUMA

Follow this and additional works at: <https://journals.tubitak.gov.tr/medical>



Part of the [Medical Sciences Commons](#)

Recommended Citation

ŐENEL, KAZIM; SÖNMEZ, SİNAN; CERRAHOĐLU, LALE; UĐUR, MAHİR; and SUMA, SELAMİ (1999)
"Autosomal Dominant Osteopetrosis Type II," *Turkish Journal of Medical Sciences*: Vol. 29: No. 3, Article
23. Available at: <https://journals.tubitak.gov.tr/medical/vol29/iss3/23>

This Article is brought to you for free and open access by TÜBİTAK Academic Journals. It has been accepted for inclusion in Turkish Journal of Medical Sciences by an authorized editor of TÜBİTAK Academic Journals. For more information, please contact academic.publications@tubitak.gov.tr.

Kazım ŞENEL¹
Sinan SÖNMEZ²
Lale CERRAHOĞLU¹
Mahir UĞUR¹
Selami SUMA³

Autosomal Dominant Osteopetrosis Type II

Departments of ¹Physical Medicine and Rehabilitation, ²Medical Genetics, ³Radiology, Faculty of Medicine Atatürk University, Erzurum-Turkey

Received: February 20, 1997

A 23 year-old man who was first seen in April 1996 gave a 8 year history of low back pain. This patient was treated with various antiinflammatory drugs for recent years. Father, mother and other sibships were normal and there were no parental consanguinity.

On physical examination; height 170 cm, weight 66 kg were found. Dorsal and lumbar vertebra motions were painful and limited. The other joints were normal. Lumbar Schober, chest expansion and fingertip to floor were found to be 3, 4 and 35 cm, respectively. Neurological and otolaryngological examinations revealed no abnormalities. Psychomotor development was normal.

Biochemical studies revealed a haemoglobin level of 10 gm/dL, an elevated Westergren sedimentation rate at 35 mm/hour, serum blood urea nitrogen (BUN) was 30 mg/dl, serum creatinine 0.6 mg/dl, serum calcium level was 8.5 mg/dL, serum phosphorus level 1.3 mg/dL, alkaline and acid phosphatase levels were 250 U/L and 12 U/L, respectively. Urine analyses showed urinary BUN 2000 mg/dL, urinary creatinine 65 mg/dL, creatinine clearance 125 ml/min. Carbonic anhydrase II (CA II) level was measured in erythrocyte hemolysates according to the routine technique and was found to normal (CA II CO₂ hydratase activity was 12.5 U/mg haemoglobin) (1). CA II levels, radiographic and laboratory examination in the patient and other members of family were found to be normal.

Radiographic investigations of skeletal survey showed generalised osteosclerosis with thickened cortex, but intracranial calcifications were not seen on skull films. Magnetic resonance imaging (MRI) scan disclosed osteosclerosis in superior and inferior portions of the vertebral bodies which is produced a "sandwich" appearance. The "bone within bone" appearance was seen

in the ileum of the patient (Figure 1). The vertebral bone density was assessed by quantitative computerised tomography (QCT) and was found markedly elevated (Figure 2). Abdominal organs ultrasonography was normal.

Cytogenetical analyses were performed from skin fibroblast and peripheral lymphocytes of all members in family. The all karyotypes were found to be normal constitution. Pedigree analysis of family has been performed and showed no inheritance pattern.

Based on standard radiographs, it is possible to describe two different subtypes of autosomal dominant osteopetrosis (ADO) with different clinical, biochemical, and histologic manifestations. Type I is radiographically characterised by pronounced osteosclerosis of the cranial vault, whereas Type II has end-plate thickening of the vertebrae (Rugger-Jersey spine) and endobones in the pelvis. Patients with ADO are often asymptomatic, and the diagnosis may be reached by chance. However, by systematic investigations, nearly all patients have manifestations related to the disorder. Symptoms are progressive with age, and correlated with osteosclerosis (2).

All forms of osteopetrosis are associated with failure to resorb bone (3). CA II deficiency is the primary defect in the syndrome of autosomal recessive osteopetrosis (4). However, it is demonstrated that CA II does not seem to play any pathogenetic role in two forms of ADO (5).

There is some variability in the severity of different clinical manifestations in different families. In some families, the symptoms related to the osteopetrosis dominated the clinical picture. Previous studies suggested that clinical heterogeneity is due to genetic heterogeneity. Multiple genetic defects produce osteopetrosis but the

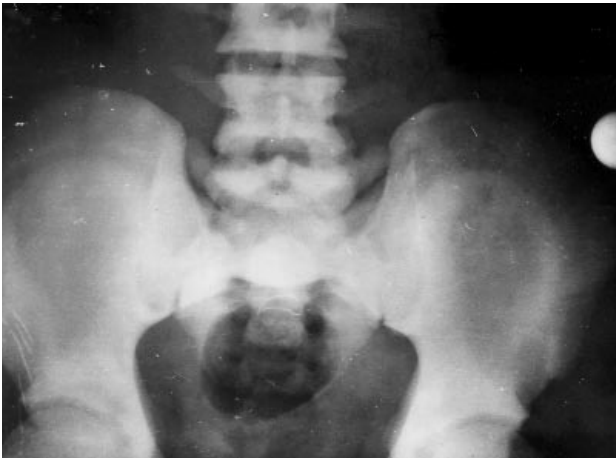

Figure 1. "Bone within bone" appearance in the ileum.

mechanism common to all the known forms of osteopetrosis is a failure of bone resorption.

In present case, CA II level was found to be normal. However, except radiological findings and anaemia the case not showed the other findings such as metabolic acidosis, growth failure, mental retardation, bone fracture, severe dental malocclusion, cerebral calcification and visual and hearing handicaps. By considering that normal CA II levels and absence other findings mentioned above, present case could not be evaluated as autosomal recessive osteopetrosis.

Interestingly, in some patients symptoms are few and phenotypic spectrum varied from an asymptomatic condition to a severely findings such as anemia, hepatosplenomegaly, hydrocephalus and blindness. In such cases, relatively benign and asymptomatic conditions are often diagnosed as osteopetrosis by radiographically and other biochemical findings. The clinic picture of present case has been evaluated as compatible with these observations, because of he first seen in 23 years old and had the complaint only low back pain. Biochemically, normal CA II levels, mild anaemia, increased acid and alkaline phosphatase levels, low plasma phosphate level, radiologically, increased bone mineral density, "sandwich" appearance in MRI scan of spine and "bone within bone" appearance in the ileum were detected. Further, the bones were diffusely osteosclerotic with thickened cortex. According to these information, the case was evaluated as ADO.

Andersen and Bollerslev suggested that ADO may be a heterogeneous group. In type 1 the most striking finding was pronounced sclerosis of the cranial vault while the spine was almost unaffected. In type 2 the sclerosis of the

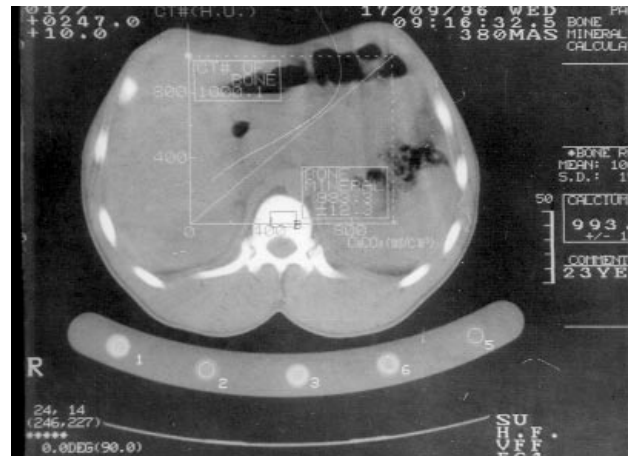


Figure 2. Increased bone mineral density in QCT.

skull was most pronounced at the base, the vertebrae always had end-plate thickening, and in the pelvis the iliac wings contained convex arcs of sclerotic bone (6). Biochemically, serum phosphate was found to be lower in Type I compared to Type II, and serum acid phosphatase was detected markedly increased in Type II (7). In the light of these information, the present case may be evaluated as type II ADO. Recently, the osteoclasts were found markedly reduced in number and size in type I, but in Type II, osteoclasts were large and highly multinucleated, with an increased number (8). Additionally, serum carboxy-terminal propeptide of type I collagen (S-PICP) was found significantly lower in type II ADO. Serum osteocalcin values in the two type ADO were insignificantly lower than controls (9). Unfortunately, in present case, osteoclast morphologies and S-PICP values could not be examined.

In genetic assessment, the pedigree analysis revealed that the condition is not inherited, because the proband have not any relative showing similar findings, because of this, the case may interpreted as Type II ADO resulting by a de novo mutation. There is not satisfactory information about the genetic etiology of ADO in literature. However, it can speculated that, collagen and/or osteocalcin gene mutations may contribute to etiopathogenesis of ADO.

In conclusion, we aimed to remind that ADO is a rare condition and it may be characterised with asymptomatic clinical picture. Because of this, some patients having only low back pain which is the etiology is remain undetermined must be suspect of ADO. Finally, the present case can provide new insights to the inheritance of ADO.

References

1. Conroy CW, Maron TH. The determination of osteopetrotic phenotypes by selective inactivation of red cell carbonic anhydrase isoenzymes. *Clin Chem Acta* 112: 347-54, 1985.
2. Bollerslev J, Mosekilde L. Autosomal dominant osteopetrosis. *Clin Orthop* 294: 45-51, 1993.
3. Marks SC Jr. Morphological evidence of reduced bone resorption in osteopetrotic mice. *Am j Anat* 163: 157-67, 1982.
4. Sly WS, Hewett-Emmett D, White MP, Yu Y-SL, Tashian RE. Carbonic anhydrase II deficiency identified as the primary defect in the autosomal recessive syndrome of osteopetrosis with renal tubular acidosis and cerebral calcification. *Proc Natl Acad Sci USA* 80: 2752-6, 1983.
5. Bollerslev J, Mondrup MP. The role of carbonic anhydrase in autosomal dominant osteopetrosis. *Scand J Clin Lab Invest* 49: 93-5, 1989.
6. Andersen PE Jr, Bollerslev J. Heterogeneity of autosomal dominant osteopetrosis. *Radiology* 164: 223-5, 1987.
7. Bollerslev J, Andersen PE Jr. Radiological, biochemical and hereditary evidence of two types of autosomal dominant osteopetrosis. *Bone* 9: 7-13, 1988.
8. Bollerslev J, Marks SC, Pockwinse S, Kassem M, Brixen K, Steiniche T, Mosekilde L. Ultrastructural investigations of bone resorptive cells in two types of autosomal dominant osteopetrosis. *Bone* 14: 865-9, 1993.
9. Bollerslev J, Thomas S, Grodum E, Brixen K, Djøseland O. Collagen metabolism in two types of autosomal dominant osteopetrosis during stimulation with thyroid hormones. *Eur J Endocrinol* 133: 557-63, 1995.