

1-1-1999

Clinical and Histopathological Indicators of NeckMetastasis in Laryngeal Carcinoma

ŞEFİK HALİT AKMANSU

HAKAN KORKMAZ

ENGİN DURSUN

SELİM SERMET ERBEK

HAKAN GÖÇMEN

See next page for additional authors

Follow this and additional works at: <https://journals.tubitak.gov.tr/medical>

 Part of the [Medical Sciences Commons](#)

Recommended Citation

AKMANSU, ŞEFİK HALİT; KORKMAZ, HAKAN; DURSUN, ENGİN; ERBEK, SELİM SERMET; GÖÇMEN, HAKAN; ÜNAL, TUĞBA; and ÖZERİ, CAVİT (1999) "Clinical and Histopathological Indicators of NeckMetastasis in Laryngeal Carcinoma," *Turkish Journal of Medical Sciences*: Vol. 29: No. 3, Article 18. Available at: <https://journals.tubitak.gov.tr/medical/vol29/iss3/18>

This Article is brought to you for free and open access by TÜBİTAK Academic Journals. It has been accepted for inclusion in Turkish Journal of Medical Sciences by an authorized editor of TÜBİTAK Academic Journals. For more information, please contact academic.publications@tubitak.gov.tr.

Clinical and Histopathological Indicators of NeckMetastasis in Laryngeal Carcinoma

Authors

ŞEFİK HALİT AKMANSU, HAKAN KORKMAZ, ENGİN DURSUN, SELİM SERMET ERBEK, HAKAN GÖÇMEN, TUĞBA ÜNAL, and CAVİT ÖZERİ

Şefik Halit AKMANSU¹
Hakan KORKMAZ¹
Engin DURSUN¹
Selim Sermet ERBEK¹
Hakan GÖÇMEN¹
Tuğba ÜNAL²
Caviz ÖZERİ¹

Clinical and Histopathological Indicators of Neck Metastasis in Laryngeal Carcinoma

Received: June 20, 1997

Abstract: Determination of cervical metastasis preoperatively is very important in planning the treatment strategy in laryngeal carcinoma. In spite of vigorous clinical and detailed high technology radiological examinations, the occult metastasis rate is between 12-17% in No necks. In recent years most of the studies are related to the clinical and histopathological risk factors that may effect cervical metastasis. In this study we reviewed the primary tumors and neck specimens of laryngeal carcinoma patients operated in our clinic retrospectively. In 46 laryngeal carcinoma patients with laryngectomy and neck dissection, the following criteria were examined; Tumor localization, T status, histologic grading, peripheral invasion pattern, perineural and vascular invasion in a follow up period of at least 2 years. Only those cases whose paraffin blocks had not deteriorated were eligible for the study. The results were

compared to neck status and although statistically insignificant, a numerically positive correlation between pathological factors and neck metastases were found. Statistical analysis was done with Chi-square and Fisher tests. Sensitivity and specificity were used as indices of accuracy. In 30,4% of the cases, there were metastatic lymph nodes in the surgical specimen. The diagnostic specificity of the clinical examination was 78% and diagnostic sensitivity was 80%. In recent years an anterolateral selective instead of a comprehensive neck dissection has also been recommended for the contralateral side of the neck by others, a method also accepted in our clinic. However, it should always be kept in mind that only low risk patients who can be closely followed up are candidates for conservative treatments.

Key Words: Laryngeal carcinoma, neck node metastasis, prognostic indicators.

Ministry of Health Ankara Hospital¹ ENT and Pathology² Clinics Ankara-Turkey

Introduction

The probability of regional control and survival is significantly reduced by the presence of lymph node metastasis in cancer of the larynx (1-3). There are strong arguments for elective node dissection in the face of high incidences of lymph node metastasis in carcinomas involving the supraglottis and the fallibility of palpating the neck. The reported number of false negative necks based only on clinical examination may reach 40% (1, 4). The rate of occult metastasis is still as high as 12%, even if the more updated and sophisticated methods of digagnostic imaging, computed tomography and magnetic resonance imaging are combined with the physical examination (1, 3, 5).

The purpose of this study is to identify and quantify the importance of clinical and histopathological indicators of cervical lymph node metastasis in patients with laryngeal cancer.

Materials and Methods

We reviewed the records of 46 consecutive patients with cancer of the larynx who had been referred to the Ear-Nose and Throat (E.N.T.) Clinic of the Turkish Ministry of Health Ankara Hospital. Only patients whose surgical treatment included either an elective or a therapeutic comprehensive neck dissection with a follow up period of at least 2 years and cases whose neck specimens could be histopathologically evaluated in retrograde (i.e.those whose paraffin blocks had not deteriorated) were eligible for the study.

The T status of disease was based on the 1992 revision of American Joint Committee on Cancer tumor-node-metastasis (TNM) staging system (6).

Tumors were graded by the criteria of Broders (7). The neoplasms were divided into well, moderately and poorly differentiated tumors with increasing anaplasia of

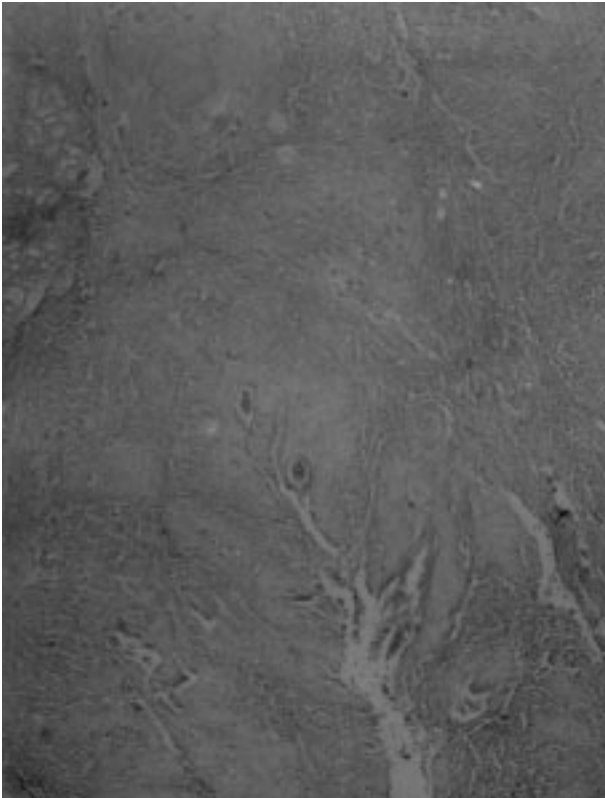


Figure 1. *Expansive border and well differentiation;* Keratin and keratinous concentric "pearl" and an apparently enclosing fibrous membrane forming a pushing border in a slowly expanding well differentiated squamous cell carcinoma (x8-HxE section).

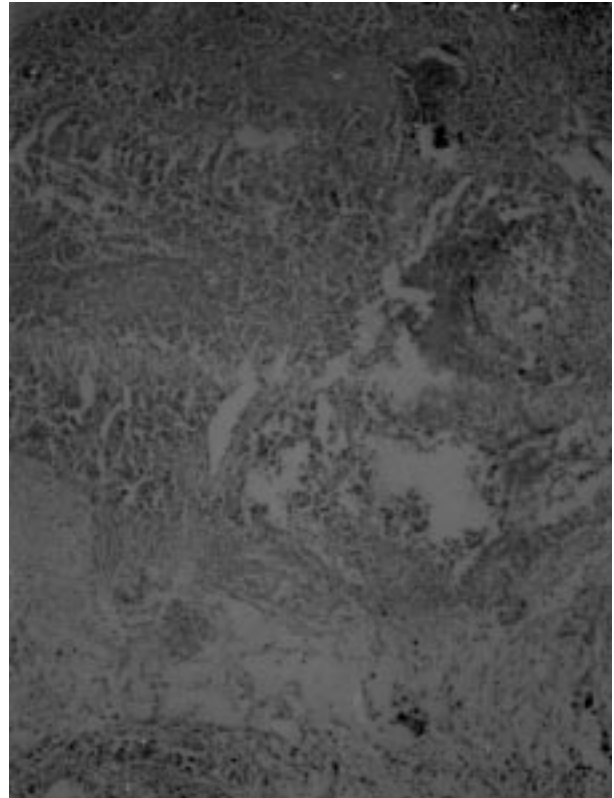


Figure 2. *Poor differentiation;* Poorly differentiated squamous cell carcinoma of larynx lacking keratin secretion, concentric keratinous pearl and intercellular bridges (x40-HxE section).

parenchymal cells and increasing numbers of mitoses as criteria of the probable aggressiveness and rapidity of the growth of the tumor (Figure 1, 2).

The peripheral invasion pattern of our cases were classified as expansive or infiltrative based on the findings of host-tumor margin in the most infiltrative zone. Those cases with well-defined borderline or in cord formation with less marked borderline were defined as expansive. Those cases with group of cells with no distinct borderline or diffuse growth pattern were defined as infiltrative (Figure 1, 3).

In some of our cases the neoplastic tissue permeated the blood vessels and perineural spaces. Such invasiveness made their surgical resection difficult and required removal of a margin of normal tissue about the infiltrative neoplasm; i.e. a radical versus a modified radical neck dissection was performed. Additionally postoperative adjuvant radiotherapy was considered in such instances.

Statistical analysis was done according to Chi-square

and Fisher tests. Sensitivity and specificity were used as indices of accuracy; here the sensitivity being the ratio of true positive cases to the sum of both true positive and false negative cases whereas, the specificity being the ratio of true negative cases to the sum of both true negative and false positive cases.

Results

All of our patients except one were male. Ages ranged from 32 to 66 years (median 53,04 years). Prior to surgery all diagnoses were confirmed histopathologically and anatomic site was ascertained postoperatively.

Treatments were total laryngectomy in 38 patients (82.6%), horizontal supraglottic laryngectomy in 6 (13,0%) and frontolateral laryngectomy in 2 (4,4%). The neck dissections were 53 neck dissections to 46 patients. Of these, 7 were bilateral. 4 of the 53 neck dissections were modified radical and 49 of them were radical classic neck dissections.

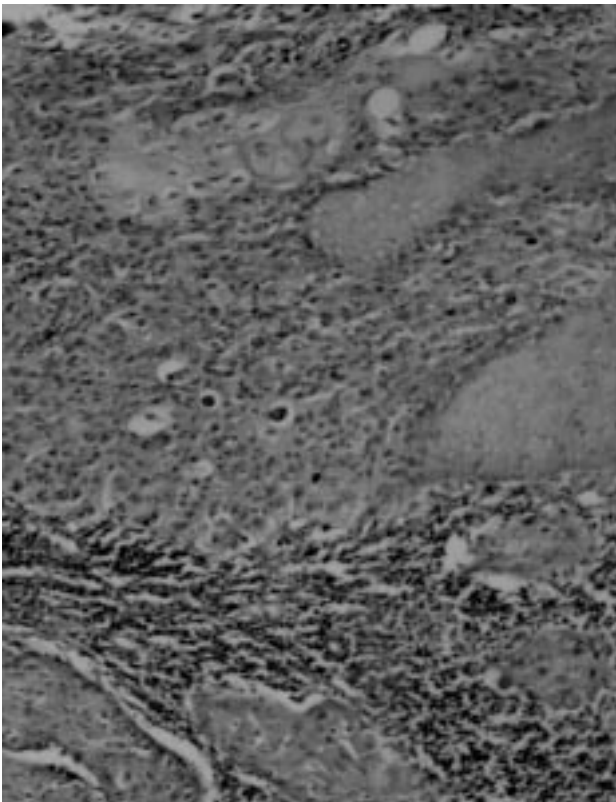


Figure 3. *Infiltrative border*: Laryngeal cancer characterized by an infiltrative border and erosive growth extending into adjacent tissues. (x 8-HxEx section)

In 34 patients (73,9%) the tumor location was supraglottic, in 6 (13,0%) it was glottic and in 6 (13,0%) it was transglottic, based on both clinical and histopathological examinations. The neck metastasis rates according to tumor localization were as follow; 26.5% in supraglottic, 16.7% in glottic and 66.7% in transglottic tumors. The statistical analysis revealed insignificant correlation ($p>0.05$) (Table).

The distribution of the T status in our series was: in 5 cases T_1 (10,9%), in 16 cases T_2 (34,8%), in 17 cases T_3 (37,0%) and in 8 cases T_4 (17,3%) based on both clinical and histopathological examinations. The neck metastasis rates according to tumor T-status were as follows; 0% in T_1 , 31.2% in T_2 , 29.4% in T_3 and 50% in T_4 . The statistical analysis revealed insignificant correlation ($p>0.05$) (Table).

Of the 46 patients in the series, 12 (26,1%) had a well differentiated tumor, 22 (47,8%) a moderately differentiated tumor, and 12 (26,1%) a poorly differentiated tumor based on histopathological examinations. The neck metastasis rates according to tumor cell differentiation were as follows; 16.7% in well differentiated, 27% in moderately differentiated and 50% in poorly differentiated cases. The statistical analysis revealed insignificant correlation ($p>0.05$) (Table).

The peripheral invasion pattern of the tumor was expansive in 7 cases (17,1%) and infiltrative in 34 cases (82,9%) based on histopathological examinations. The invasion pattern could not be evaluated in the specimens

Variable	categories	n	%	MN(-)	%	MN(+)	%	p
tumor site	Supraglottic	34	73,9	25	9	73,5	26,5	>0,05
	Glottic	6	13,0	5	1	83,3	16,7	
	Transglottic	6	13,0	2	4	33,3	66,7	
T stage	T_1	5	10,9	5	0	100,0	0,0	>0,05
	T_2	16	34,8	11	5	68,8	31,2	
	T_3	17	37,0	12	5	70,6	29,4	
	T_4	8	17,3	4	4	50,0	50,0	
differentiation	well	12	26,1	10	2	83,3	16,7	>0,05
	moderate	22	47,8	16	6	73,0	27,3	
	poor	12	26,1	6	6	50,0	50,0	
p.i.p*	expansive	7	17,1	5	2	71,4	28,6	>0,05
	infiltrative	34	82,9	22	12	64,7	35,3	
vascular/prineural invasion**		5	10,9	2	3	40,0	60,0	

Table. Distribution of cases and neck node metastasis according to selected clinical and histopathological parameters. *: In 5 of patients peripheral invasion pattern could not be assessed. **: Vascular or perineural invasion was detected in only 5 patients. (p.i.p.: peripheral invasion pattern. MN: Metastatic nodes)

of 5 cases so they were excluded from the study for this category. The neck metastasis rates according to peripheral invasion pattern were as follows; 28.6% in expansive and 35.3% in infiltrative cases. The statistical analysis revealed insignificant correlation ($p > 0.05$) (Table).

There was neoplastic perineural invasion and/or vascular embolization in 5 cases (10.9%). Statistical analysis was not done in this category due to low number of patients (Table).

In 14 cases (30.4%) there were metastatic lymph nodes in the specimen. The diameter of positive nodes of each patient ranged from 1 to 6 cm, none of them more than 6 cm in diameter. The diagnostic specificity of the clinical examination was 78% and the diagnostic sensitivity was 80%. In 4 of the true positive nodes there was transcapsular spreading of the tumor (Table). In 4 cases there was contralateral metastasis without any ipsilateral positive node and all of these tumors were located in the supraglottic region.

Discussion

In recent years most of the studies in laryngeal carcinoma are related to the clinical and histopathological risk factors that may effect cervical metastasis (8-11). The histologically proven presence or absence of metastatic nodes is a reliable prognostic marker for laryngeal carcinoma (1, 12). Unfortunately, there are no accurate non-invasive means for evaluating neck lymph nodes prior to their removal.

While neck lymph node involvements in supraglottic and glottic tumors were 26,5% and 16,7% respectively, we obtained a high 66,7% involvement rate in transglottic tumors. Although the statistical analysis was insignificant there seemed to be an increasing incidence of metastasis as the tumor affected areas with higher lymphatic density, namely the supraglottis. This numerical increasing incidence was also seen as the tumor affects a greater area. In addition to this it was detected that in four supraglottic cases there was contralateral neck metastasis without any ipsilateral involvement. The data suggest that all patients with supraglottic and patients with transglottic tumors with involvement of the epiglottis and preepiglottic space, should be subjected to bilateral neck dissection. Although due to low number of patients this phenomenon was not statistically analysed in our study, it was in accordance with the views of many authors who advocated bilateral elective neck dissection in N_0 supraglottic cancers (13, 14). Postoperative

irradiation given to the 4 supraglottic cancer cases who had positive nodes did not reduce the rate of neck recurrences; 3 of the 4 patients had a recurrence in the neck.

There was a gradual increasing trend in the frequency of metastasis with an increase of stage from T_1 to T_4 (T_1 -0%, T_2 -31.2%, T_3 -29.4%, T_4 -50%). There was a slight increase in the frequency of metastasis as histologic differentiation changed from well (16,7%) to moderate (27,3%) and then to poor (50%). There also was a tendency towards nodal involvement when there was vascular and perineural infiltration (60%). When statistically evaluated these figures are insignificant, which can be explained largely by the relatively low number of patients in some combinations. However, we still believe that, those figures with apparent numerical differences cannot be neglected in prediction of the results.

There were no differences in node involvement according to the microscopic peripheral invasion pattern of the primary tumor. Although, peripheral invasion pattern was searched in the post-operative specimens, we used this criterion for correlation of neck metastasis rate. There are cases that laryngectomy (either partial or total) is done without neck dissections. In such cases there are still not any well developed criteria to determine the risk of occult neck metastasis. Therefore we assessed the role of peripheral invasion pattern in neck metastasis in post-operative specimens. The peripheral invasion pattern in squamous cell carcinomas are defined as; either expansive in which slowly expanding malignant tumors develop an apparently enclosing fibrous membrane and push along a broad front into adjacent normal structures or infiltrative in which erosive growth extend crablike feet into adjacent tissues (15).

Patients with clinically positive nodes are candidates for either a classic or modified comprehensive neck dissection, preferably in conjunction with irradiation. A staging elective procedure was used to be advised for the contralateral side of neck whenever the tumor was supraglottic or was transglottic and involved the epiglottis and preepiglottic region. In recent years bilateral simultaneous elective neck dissection has been advocated for such cases. An anterolateral neck dissection instead of a comprehensive dissection has also been recommended in this situation by others, a method also accepted in our clinic (1, 13, 14, 16). An elective neck dissection must be performed when a satisfactory clinical assessment cannot be made or when there are geographic and social factors that would prevent adequate follow-up.

Only low risk patients who can be closely followed up are candidates for more conservative treatment.

This preliminary study reveals the results of an ongoing study in our clinic with larger number of patients and other tumor markers like Ki67, P53 etc. Our results have not proved a significant correlation between prediction of neck metastasis rate and the

histopathological-clinical parameters used. In spite of this conclusion, we still believe that, with further studies with larger number of patients and new immunological and histopathological indicators it would be possible to predict neck metastasis more accurately in laryngeal carcinoma patients soon.

References

1. Kowalski LP, Franco EL, Sobrinho JDA. Factors influencing regional lymph node metastasis from laryngeal carcinoma. *Ann Otol Rhinol Laryngol* 104: 442-7, 1995.
2. Candela FC, Shahh J, Jaques DP, Shah JP. Patterns of cervical node metastases from squamous carcinoma of the larynx. *Arch Otolaryngol Head Neck Surg* 116: 432-5, 1990.
3. Koç C, Çelikkanat S, Özyiğit S, Özdem C. The effect of occult lymph node metastasis on prognosis of squamous head and neck cancers. *KBB ve Baş Boyun Cerrahisi Dergisi* 4: 82-4, 1996.
4. Ali S, Tiwari RM, Snow GB. False-positive and false-negative neck nodes. *Head Neck Surg* 8: 78-82, 1985.
5. Friedman M, Mafee M, Pacella BL Jr, Strorigl TL, Dew LL, Toriumi DM. Rationale for elective neck dissection in 1990. *Laryngoscope* 100: 54-9, 1990.
6. Beahrs OH, et al (eds.). *Manual for Staging of Cancer*, 4th edition, JB Lippincott Co, Philadelphia, USA, 1992, p:34.
7. Broders AC. Carcinoma, grading and practical application. *Arch Pathol* 2: 376-81, 1926.
8. Dursun G, Sak SD, Beder E, Aktürk T. The prognostic significance of histopathological parameters in squamous cell carcinoma of the larynx. XV th World Congress of ORL-Head & Neck Surgery - Istanbul, 732-35, 1993.
9. Yıldırım A, Karasalihoğlu A, Koten M, Adalı MK. Assessment of prognosis with histopathological parameters in laryngeal carcinoma. XXIII rd Turkish National Otorhinolaryngology Congress-Antalya, 969-72, 1995.
10. Akçayöz N, Çuhruk Ç, Yılmaz O. Correlation of neck metastasis to primary tumor status, cellular differentiation and localization in laryngeal carcinoma. XX th Turkish National Otorhinolaryngology Congress-Istanbul, 207-8, 1989.
11. Kayhan V, Hacıhanefioğlu U, Etaner R. Importance of histological structure in prognosis of laryngeal carcinoma. XVII th Turkish National Otorhinolaryngology Congress-Istanbul, 175-84, 1985.
12. Shah JP, Tollefsen HR. Epidermoid carcinoma of the supraglottic larynx: Role of neck dissection in initial surgical treatment. *Am J Surg* 128: 494-9, 1974.
13. Johnson J. Carcinoma of the larynx: Selective approach to the management of cervical lymphatics. *ENT Journal* 75: 303-5, 1994.
14. Weber PC, Johnson J, Myers EN. The impact of bilateral neck dissection on pattern of recurrence and survival in supraglottic carcinoma. *Arch Otolaryngol Head Neck Surg* 120: 703-6, 1994.
15. Cotran Ramzi S. *Robbins-Pathologic basis of disease*, 5th edition, WB Saunders CO, Philadelphia, USA, 1994, p:248.
16. Byers RM, WolfPF, Ballantyne AJ. Rationale for elective modified neck dissection. *Head Neck Surg* 10: 160-7, 1988.