

1-1-1999

The Evaluation of Elongated Styloid Process in Panoramic Radiographs in Edentulous Patients

MEMDUHA GÜLHAL BOZKIR

HASAN BOĞA

FAHRİ DERE

Follow this and additional works at: <https://journals.tubitak.gov.tr/medical>



Part of the [Medical Sciences Commons](#)

Recommended Citation

BOZKIR, MEMDUHA GÜLHAL; BOĞA, HASAN; and DERE, FAHRİ (1999) "The Evaluation of Elongated Styloid Process in Panoramic Radiographs in Edentulous Patients," *Turkish Journal of Medical Sciences*: Vol. 29: No. 4, Article 23. Available at: <https://journals.tubitak.gov.tr/medical/vol29/iss4/23>

This Article is brought to you for free and open access by TÜBİTAK Academic Journals. It has been accepted for inclusion in Turkish Journal of Medical Sciences by an authorized editor of TÜBİTAK Academic Journals. For more information, please contact academic.publications@tubitak.gov.tr.

Memduha Gülhal BOZKIR¹
Hasan BOĞA²
Fahri DERE¹

The Evaluation of Elongated Styloid Process in Panoramic Radiographs in Edentulous Patients

Received: October 13,1997

Abstract: It has been estimated that between 2% to 28% of the general adult population has radiographic evidence of elongated styloid process. In adults, the mean radiographic length of the styloid process is 20 to 30 mm and its tip is located between the external and internal carotid arteries, just lateral to the tonsillar fossa. Eagle's syndrome occurs when an elongated styloid process or ossified stylohyoid ligament causes recurrent throat pain or foreign body sensation, dysphagia, or facial pain. It may develop inflammatory changes or impinge on the adjacent arteries or sensory nerve endings, leading to the symptoms described.

To study the incidence of elongated styloid process, panoramic radiographs of 100 male and 100 female patients who were over 50

years of age and were to have maxillary and mandibular total prostheses made were examined in a dental unit, Adana Numune Hospital (Turkey). In these radiographs, the comparison of the frequency of elongated styloid process and/or ossification of stylohyoid ligament which are longer than 30 mm were included in evaluation.

The elongation of the styloid process and/or ossification of stylohyoid ligament was found in 8 patients (4%): 3 females (37% of the cases), 5 males (63% of the cases). There was no statistical difference between the two sexes.

Key Words: The elongation of the styloid process, ossification of the stylohyoid ligament.

¹Department of Anatomy; Faculty of Medicine, Çukurova University.

²Dental Unit, Numune Hospital, Adana-Turkey

Introduction

The styloid process arises from the temporal bone immediately in front of the stylomastoid foramen. The normal length of this process is 20 to 25 mm in adults (1, 2), the mean radiographic length of the styloid process has been reported to be between 20 to 30 mm (3). Its shape is cylindrical, tapering gradually toward the apex like a pinnacle. The apex of the styloid process is clinically important, because it is located between internal and external carotid arteries, just lateral to the tonsillar fossa within the lateral pharyngeal wall. The tip of the styloid process is continuous with the stylohyoid ligament, which extends to the lesser cornu of the hyoid bone. Muscular and ligamentous structures are attached at various locations of the process. The attached muscles are the stylopharyngeus (arising from the base), the stylohyoid (attached to the middle portion) and the styloglossus muscle (originating from the extremity of the process). The innervations of these three muscles are the glossopharyngeal nerve, the facial nerve, and the hypoglossal nerve, respectively (4).

The stylohyoid process and ligament are derived from the first and second branchial arches, in addition to Reichert's cartilage. It has been demonstrated that during fetal development Reichert's cartilage links the styloid bone to the hyoid bone. The potential for calcification of this complex of structures and the resulting trauma is from this origin, namely, Reichert's cartilage during embryogenesis. In the adult the stylohyoid ligament, which is normally composed of dense fibrous connective tissue, may retain some of its embryonic cartilage and thus have the potential to become partially or completely ossified. If these structures solidify, they can cause the pain and suffering present in symptomatic cases (3, 5).

The mineralization and calcification of the styloid complex can be seen quite often. This complex is composed of the styloid process, stylohyoid ligament and the stylomandibular ligament (6, 7). Although patients may sometimes show clinical symptoms with the reported prevalence from 1% to 5%, the condition often occurs without any symptoms (6).

Elongation of the styloid process and/or ossification of stylohyoid ligament can result in styloid-stylohyoid

syndrome. This case is known as either "Eagle's Syndrome"; "Elongated Styloid Process Syndrome"; "Styloid Process-Carotid Artery Syndrome"; "Stylohyoid Syndrome" or "Styloid Process Neuralgia" (6). Eagle reported several cases of cervicopharyngeal symptoms associated with a radiographic diagnosis of an elongated, ossified styloid process occurring a few months post-tonsillectomy (8). He described the symptoms as nagging or aching sensation in the throat, similar to the chronic pharyngitis, and pain spreading to the ear and the mastoid region, difficulty in swallowing, and the sensation of a foreign object lodged in the throat (8, 9). It may develop inflammatory changes or impinge on the adjacent arteries or sensory nerve endings, leading to the symptoms described. A diagnosis of Eagle's syndrome is applied only when ossification develops within a period of time after trauma, with accompanying symptoms. Eagle's syndrome may be caused by tonsillectomy or traumatic fracture of a mineralized stylohyoid ligament (10). A diagnosis of stylohyoid syndrome is applied only when patients have stylohyoid chain ossification and/or styloid process elongation with symptoms; there is no history of cervicopharyngeal trauma (11). Diagnosis can usually be made on physical examination by digital palpation of the styloid process in the tonsillar fossa, which exacerbates the pain and with radiographic workup. In addition, relief of symptoms with injection of an anesthetic solution into the tonsillar fossa is highly suggestive of this diagnosis (12).

It had been estimated that between 2% and 4% of the general population presents radiographic evidence of an ossified portion of the stylohyoid chain (13). The majority of these 2% to 4% of patients are asymptomatic. When symptoms do exist, there is little correlation between the extent of the symptoms and the severity of the ossification. Those few patients who are symptomatic are usually over 40 years of age (13, 14). The majority of symptomatic patients have had no recent history of tonsillectomy or other cervicopharyngeal trauma (13, 14, 15). A developing anatomic variant of the styloid process rarely occurs in childhood or adolescence (11). The number and the length of calcifications increase with age, and there is no relationship to sex or mandibular size (2, 16).

Elongated styloid process was found as a cause of difficult intubation (7). Dysphonia may be seen secondary to Eagle's syndrome (17). The clinical symptoms of an elongated styloid process can be misdiagnosed, as salivary gland disease, otitis, temporomandibular myofascial dysfunction syndrome or glossopharyngeal neuralgia. In addition, stylohyoid syndrome must be differentiated

from all the various dysfunction related to temporomandibular joint problems (5, 18). The prevalence of an elongated styloid process in patients with temporomandibular disorder is 27% (19).

Treatment of stylohyoid syndrome has varied: surgical removal of the elongated styloid process or ossified stylohyoid ligament; injection of a steroid solution or long-acting anesthetic at the lesser horn of the hyoid or the inferior aspect of the tonsillar fossa (5, 20). Treatment in cases of true stylohyoid chain ossification caused by trauma (Eagle's syndrome) is immediate surgical excision. The most long-term treatment in such cases involves the intraoral approach, with complete surgical excision of the styloid process and/or ossified stylohyoid ligament. The extraoral lateral neck approach is only indicated when the intraoral approach is not possible—as in limited jaw opening (15). In the patients with stylohyoid syndrome (there is no trauma history), the first choice is local injection of long-acting local and steroidal solutions regionally to confirm the diagnosis and to offer relief. The patients, who are refractive to such initial treatments and who cannot obviously adapt to their developing symptoms with time, would then be required to undergo a surgical intervention (15). In surgical treatment, thrombosis of the internal carotid artery is a major complication (21).

More information about different cases of styloid process is obtained by using panoramic radiography in dentistry (3). Langlais proposed three radiographic appearance: Type I, elongated; Type II, pseudoarticulated; and Type III, segmented. The radiographic appearance of type I, of mineralized complex is characterized by an uninterrupted integrity of the styloid image. Illustrate of type II, the styloid process is apparently joined to the mineralized stylomandibular or stylohyoid ligament by a single pseudoarticulation. Type III, consist of either short or long noncontinuous portions of the styloid process or interrupted segments of mineralized ligament (6).

For brevity the term elongated styloid process will be used in this report, encompassing the truly elongated styloid process and the ossified stylohyoid or stylomandibular ligaments. We consider the styloid process to be elongated when the total length of the bony process and/or the mineralized portion of one of the ligaments exceeds 30 mm on the radiograph.

The purpose of this study is to evaluate the elongation of the styloid process and/or ligament ossification by using panoramic radiographs, the distribution according to sex and reviewing the literature. Here, both ossification of stylohyoid and stylomandibular ligaments

and truly elongated styloid process are defined as elongated styloid process.

Materials and Methods

The panoramic radiographs of 100 male and 100 female patients who were over 50 years old, and who require complete denture prosthesis were examined between the dates of August, 1994 and August, 1995 at the Dental Unit of Numune Hospital, Adana (Turkey). The median age of the woman was 57 years, with a range from 51 to 68 years. The median age of the men was 59 years, with a range from 52 to 71 years. The panoramic radiographs (Odontorama PC, Trophy, Cedex, France) were obtained by a standard method at 65 KV, 10 MA and in 15 seconds. Magnification was 25% uniformly.

The apparent lengths of styloid process were measured with the same steel metric ruler, from the point of emergence of the process to their tips, regardless of whether or not the styloid process was segmented. the length of the styloid process and/or ossification of stylohyoid ligament which are longer than 30 mm were included in evaluation.

Results

Panoramic radiographs of 200 patients; (100 male, 100 female) who were over 50 years old, were studied. In this research, elongated styloid processes and/or ossification of the stylohyoid ligaments were found in 8 out of 200 patients (4%) (Fig. 1). These 8 patients did not describe any clinical symptoms. Taking into account 8

patients, it was observed that 37% of the patients were female, and 63% males. When the chi-square test was applied, the result indicated that the occurrence of elongated styloid process is independent of the sex ($p < 0.001$). Twenty five percent of the patients (1 male, 1 female) with elongated styloid process were determined as unilateral, and 75% (4 males, 2 females) as bilateral (Table). In the other words, total 14 elongated styloid processes was considered. The average length of the elongated styloid process was 53 mm, and it was found that 42% of the cases (6 of them) were of uninterrupted Type I, and 58% (8 of them) of interrupted Type III.

Discussion

The styloid process, styloid ligament and the lesser cornua of the hyoid bone derive from the second branchial arch (4).

It has been previously reported that, the normal radiographic length of styloid process is 20 to 30 mm. Of pathogenic importance is the spatial position of the tip of this process (4, 8). Keur states that, if the length of the process or the mineralized part of ligaments appear radiography is 30 mm and more, this can be considered as elongated styloid process (4).

In the present study, the length of the styloid process and/or ossification of stylohyoid ligament, which are longer than 30 mm, were included in evaluation. In this research, elongated processes were found in 8 out of 200 patients (4%). Twenty five percent of the patients (1 male, 1 female) with elongated process were determined

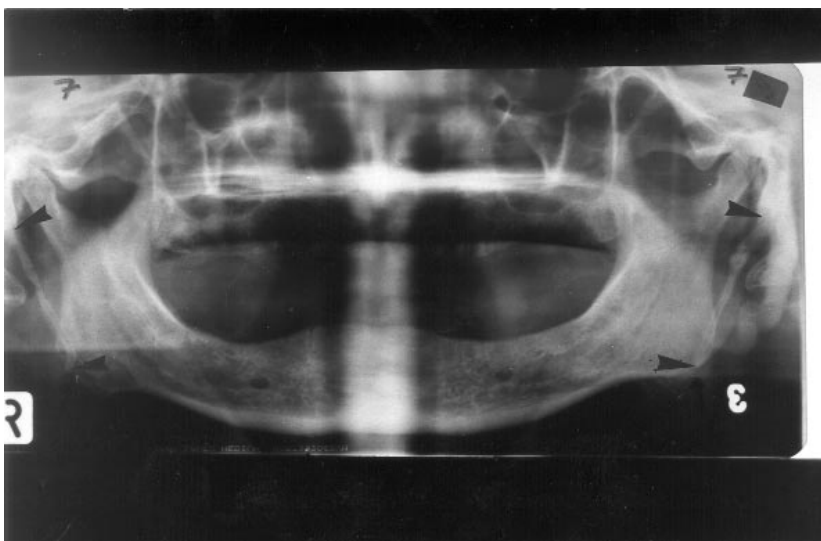


Figure 1. Elongated styloid process 63 mm.
Arrows: The measured points of styloid process.

Case	Gender	Age	Side	Length of Styloid Process (mm)	
1	Female	54	Bilateral	Right: 65	Left: 67
2	Female	56	Bilateral	Right: 39	Left: 48
3	Female	61	Unilateral	Right: --	Left: 43
4	Male	54	Bilateral	Right: 47	Left: 50
5	Male	55	Unilateral	Right: 43	Left: --
6	Male	58	Bilateral	Right: 42	Left: 35
7	Male	60	Bilateral	Right: 59	Left: 63
8	Male	63	Bilateral	Right: 51	Left: 52

Table 1. The distribution of 14 elongated styloid processes in patients.

as unilateral and 75% (4 males, 2 females) as bilateral. In the previously researches, some authors indicated that incidence of elongation occurred as 1%, 4%, 8.2%, 28% (3, 5, 6, 7, 8). The 4% incidence that, obtained in our study, can be observed close to Eagle's result. In some reports, high incidence of elongated styloid process was found (3, 14). For example, Monsour et al found that

incidence of elongated styloid process was 21%. But, magnification was 37% in their study.

In conclusion, panoramic radiography may be helpful for the investigation of elongated styloid process and/or ossification of stylohyoid ligament in patients with or without symptoms in order to avoid misdiagnosis.

References

- Eagle W.W., Elongated styloid process. Arch Otolaryngol 47: 630-40, 1948.
- Ferrario V.F., Sigurt'a D., Daddona A., Dalloca L., Miani A., Tafuro F., Sforza C. Calcification of the stylohyoid ligament: Incidence and morphoquantitave evaluations. Oral Surg Oral Med Oral Pathol 69: 524-9, 1990.
- Monsour P.A., Yougn W.G., Variability of the styloid process and stylohyoid yigament in panoracmic radiographs. Oral Surg Oral Med Oral Pathol 61: 522-526, 1986.
- Keur J.J., Campbell J.P.S., Mc Carthy J.F., Ralph W.J. The cilinical significance of the elongated styloid process. Oral Surg Oral Med Oral Pathol 61: 399-404, 1986.
- Winkler S., Sammartino F.J., Monari J.H. Stylohyoid Syndrome. Oral Surg Oral Med Oral Pathol 51: 215-7, 1981.
- Langlais R.P., miles D.A., Van Dis M.L. Elongated and mineralized styholyoid ligament complex: A proposed classification and report of a case of Eagle's syndrome. Oral Surg Oral Med Oral Pathol 61: 527-32, 1986.
- Kawai T., Shimimozato K., Ochiai S.. Elongated styloid proress as a cause of difficult intubation. J Oral Maxillofac Surg 48: 1225-8, 1990.
- Eagle W.W., Elongated styloid process report of two cases. Arch Otolaryngol 25: 584-7, 1937.
- Bhaskar S.N.. Synopsis of Oral Pathology. St. Louis: CV Mosby, London 1981, p 707.
- Babad M.S.. Eagle's syndrome caused by traumatic fracture of a mineralized stylohyoid ligament. Cranio 13: 188-92, 1995.
- Camarda A.J., Deschamps C., Forest D.. II. Stylohyoid chain ossification: A discussion of etiology. Oral Surg Oral Med Oral Pathol 67: 515-20, 1989.
- Balbuena L. Jr., Hayes D., Ramirez S.G., Johnson R.. Eagle's syndrome (elongatid styloid process). South Med J 90: 331-4, 1997.
- Gossman Jr. J.R., Tarsitano J.J.. The styloid-stylohyoid syndrome. J Oral Surg 35: 355-60, 1977.
- Kaufman S.M., Elzay R.P., Irish E.F.. Styloid process variation: radiologic and clinical study. Arch Otolaryngol 91: 460-3, 1970.
- Camarda A.J., Deschamps C., Forest D.I. Stylohyoid chain ossification: A discussion of etiology. Oral Surg Oral Med Oral Pathol 67: 508-14, 1989.
- O Carroll M.K.. Calcification in the stylohyoid ligament. Oral Surg 58: 617-21, 1984.
- Blatchford S.J., Coulthard S.W.. Eagle's syndrome: an atypical cause of dysphonia. Ear Nose Throat J 68: 48-51, 1989.
- Barrett A.W., Griffiths M.J., Scully C.. Osteoarthritis, the temporomandibular woint, and Eagle's syndrome. Oral Surg Oral Med Oral Pathol 75: 273-5, 1993.
- Zaki H.S., Greco C.M., Rudy T.E., Kubinski J.A.. Elongated styloid process in a temporomandibular disorder sample: prevalance and treatment outcome. J. Prosthet Dent 75: 399-405, 1996.

20. Ozawa T., Hasegawa M., Okaue M., Shimoyama T., Hori M., Matsumoto N., Tanaka H.. Two cases of symptomatic elongated styloid process. *J Nihon Univ Sch Dent* 37: 178-82, 1995.
21. Rideiger D., Ehrenfeld M. Pathogenesis and clinical manifestation of the styloid syndrome. *Dtsch Zahnarztl Z* 44: 968-70, 1989.