

1-1-1999

Vancomycin-Induced Lupus ErythematosuslikeReaction

İFTİHAR KÖKSAL

KEMALETTİN AYDIN

RAHMET ÇAYLAN

SEVİM AYDIN

YAVUZ ÖZORAN

See next page for additional authors

Follow this and additional works at: <https://journals.tubitak.gov.tr/medical>

 Part of the [Medical Sciences Commons](#)

Recommended Citation

KÖKSAL, İFTİHAR; AYDIN, KEMALETTİN; ÇAYLAN, RAHMET; AYDIN, SEVİM; ÖZORAN, YAVUZ; REİS, ABDÜLKADİR; and ÇİMŞİT, GÜLSEREN (1999) "Vancomycin-Induced Lupus ErythematosuslikeReaction," *Turkish Journal of Medical Sciences*: Vol. 29: No. 5, Article 17. Available at: <https://journals.tubitak.gov.tr/medical/vol29/iss5/17>

This Article is brought to you for free and open access by TÜBİTAK Academic Journals. It has been accepted for inclusion in Turkish Journal of Medical Sciences by an authorized editor of TÜBİTAK Academic Journals. For more information, please contact academic.publications@tubitak.gov.tr.

Vancomycin-Induced Lupus ErythematosuslikeReaction

Authors

İFTİHAR KÖKSAL, KEMALETTİN AYDIN, RAHMET ÇAYLAN, SEVİM AYDIN, YAVUZ ÖZORAN, ABDÜLKADİR REİS, and GÜLSEREN ÇİMŞİT

İfhtihar KÖKSAL¹
Kemalettin AYDIN¹
Rahmet ÇAYLAN¹
Sevim AYDIN²
Yavuz ÖZORAN²
Abdülkadir REİS³
Gülseren ÇİMŞİT⁴

Vancomycin-Induced Lupus Erythematosuslike Reaction

Departments of ¹Infectious Diseases and
Clinical Microbiology, ²Histology, ³Pathology,
⁴Dermatology, Faculty of Medicine, Karadeniz
University, Trabzon-Turkey

Received: September 18, 1998

Vancomycin is a glycopeptide antibiotic that is active against staphylococci, streptococci, and other gram-positive bacteria. It is the drug of choice for the treatment of infection due to methicillin-resistant staphylococci, *Corynebacterium jeikeium*, and multiple resistant strains of *Streptococcus pneumoniae*. Vancomycin is an alternative treatment for serious the use of penicilins and cephalosporins (1-3). The most common adverse effects of vancomycin are "red man syndrome" and hypotension, both due to histamine release (4-6). Other adverse reactions are drug-associated fever, other hypersensitivity reactions, ototoxicity, nephrotoxicity, Stevens-Johnson-type reaction, and toxic epidermal necrolysis (6-8).

In this article, we present a case which developed a lupus erythematosuslike (LE) reaction in the course of vancomycin treatment. To our knowledge, this association has been previously suggested in only one published report (9).

A 57-year-old man was admitted to hospital because of fever, nausea, vomiting, and exhaustion on April 27, 1996. On physical examination, his temperature was 39°C orally, his pulse rate was 73/min, and respiration rate was 24/min. His blood pressure was 120/80 mm Hg. He had bilateral conjunctival hemorrhage and grade 3/6 systolic murmur on cardiac auscultation. The other physical findings were normal.

Pertinent laboratory studies on admission included a white blood cell count of 14,800/mm³, with 72% polymorphonuclear leukocytes, 12% band forms 16% lymphocytes. The hematocrit was 39.7%, platelet count 122,000 per cubic millimeter. The prothrombin and partial-tromboplastin times were normal, and

sedimentation rate was 61 mm/hour. Blood urea nitrogen, serum creatinine, glucose, bilirubin and other biochemical parameters were normal. Aspartate amino transferase (AST) was 71 mmol/lit (normal range 5-35 mmol/lit) and alanine amino transferase (ALT) 107 mmol/lit (normal range 5-40 mmol/lit). Urine analysis revealed microscopic hematuria. Echocardiography revealed moderately aortic stenosis, mitral stenosis, aortic failure, and valvular vegetation. Based on these cardiac findings, endocarditis was suspected. Six samples of blood were collected for microbiological diagnosis. The patient was started on vancomycin hydrochloride (2g/day, in 4 divided doses) empirically. All blood cultures yield *S. aureus*. Echocardiographic findings together with blood cultures clearly confirmed the diagnosis of staphylococcal endocarditis. The patient's clinical course started to improve three days after initiation of vancomycin therapy.

On vancomycin day 22, he developed fever (38°C) and a pruritic, erythematous, macular skin rash, distributed in a generalized fashion over his body, including the palms and soles. Shortly thereafter, palpebral and conjunctival edema and hypotension, malaise, arthralgia and myalgia also developed. Laboratory findings showed an erythrocyte sedimentation rate of 75mm in the first hour; the white blood cell count normal; serum AST and ALT were elevated. The IgE and complement levels were normal.

Vancomycin was suspected as the etiologic agent of the patient's skin and mucosal reaction, and was discontinued. His other medications were not changed. The patient was started on sulbactam-ampicillin and netilmicin therapy according to results of antimicrobial sensitivity testing.

Two pieces of punch biopsy from the edge of a dermal lesion each measuring 6mm in size were obtained and investigated histopathologically. Microscopic examination of the biopsy samples revealed epidermal keratosis, hydropic degeneration in the basal cells, prominent mixed infiltrate composed primarily of neutrophils and lymphocytes around the vessels. Extravasation of red cells was also noted. These histopathological findings were similar to those found in drugs related to lupus erythematosus-like reactions (Figures 1, 2). Immunofluorescence studies were negative. Rheumatoid factor, anti-nuclear antibodies and anti-DNA tests were negative, the complement levels were within normal limits.

After cessation of vancomycin therapy, the patient's complaints persisted for the next two days and the patient was put on steroid therapy. On the third day of steroid therapy, eruptions were noted to fade beginning from the trunk towards the distal parts of the body. All clinical findings subsided completely within 10 days and steroid therapy was eventually discontinued. On the 80th day after his admission, the patient expired due to a large newly formed vegetation.

Serious cutaneous reactions to vancomycin are uncommon (7). The occurrence of an erythematous, flushing-type reaction termed "*red man syndrome*" has been reported following intravenous administration of vancomycin (in 3-11 % of patients) which is characterized by flushing and itching, especially of the upper torso. In severe cases, hypotension may occur (4-6, 10). This phenomenon is believed to occur due to the direct effect of histamine release from the mast cells by nonimmunologic processes (11). Other adverse effects include nephrotoxicity (5%), rash (2-5%), neutropenia (2%), ototoxicity (1-5%), Stevens-Johnson Syndrome, toxic epidermal necrolysis, fever of unknown origin and rigors (5-8, 12, 13). There is only one case of a lupus erythematosuslike (LE) reaction due to vancomycin described in the literature (in a patient with serious staphylococcal infection) (9). A large number of drugs are reported to induce LE-like reactions (Table). Also various drugs have been implicated in precipitating or activating systemic lupus erythematosus (SLE) in 3-12 % of cases (14). Drug-induced SLE. However, cutaneous and renal manifestations are much rarer in drug-induced than spontaneous SLE. The clinical and laboratory manifestations usually, but not always subside when the medication is discontinued (15). However, there are features to suggest that drug-induced SLE differs from the spontaneous disease: it is uncommon in black, it

Table: Drugs inducing lupus erythematosus-like syndromes (15, 16).

Acebutolol	Oral contraceptives, including
Allopurinol	Chlormadinone
Aminoglutethimide	Ethynylloestradiol
Aminosalicylic acid	Ethinodiol diacetate
Atenolol	Medroxyprogesterone
Captopril	Mestranol
Carbamazepine	Norethindrone
Clofibrate	Norethynodrel
Clonidine	Oxprenolol
Co-trimoxazole	Oxyphenisatin
Diphenylhydantoin	p-Aminosalicylic acid
Ethosuximide	Penicillin
Gold salt	Penicillamine
Griseofulvin	Phenothiazine
Guanoxan	Phenylbutazone
Hydrallazine	Phenytoin
Ibuprofen	Pindolol
Isonicotinic acid hydrazide	Primidone
Isoniazid	Procainamide
Isoquinazepon	Propyranolol
	Propylthiouracil
Labetolol	Quinidine
Lithium	Reserpine
Methyl dopa	Streptomycin
Methylphenylethylhydantoin	Sulphasalazine
Methylthouracil	Sulphonamides
Methysergide	Tertalol
Minoxidil	Tetracycline
Nitrofuradantin	Trimethadione
Nomisfensine	Venocuran

occurs in an older age group, renal and central nervous system involvement is infrequent, antihistone antibodies are frequent, anti DNA antibodies are absent and serum complement is normal (14). In our patient, these findings were almost identical.

Cutaneous involvement in drug-induced SLE may be in the form of vasculitis, bullous, erythema multiforme or may resemble pyoderma gangrenosum (16). In our patient, vasculitis was documented histopathologically and clinically.

Among the theories that explain the occurrence of drug-induced LE, the widely accepted hypothesis is the formation of drug-nucleoprotein complex which is immunogenic in nature (16). Lesions with duration less

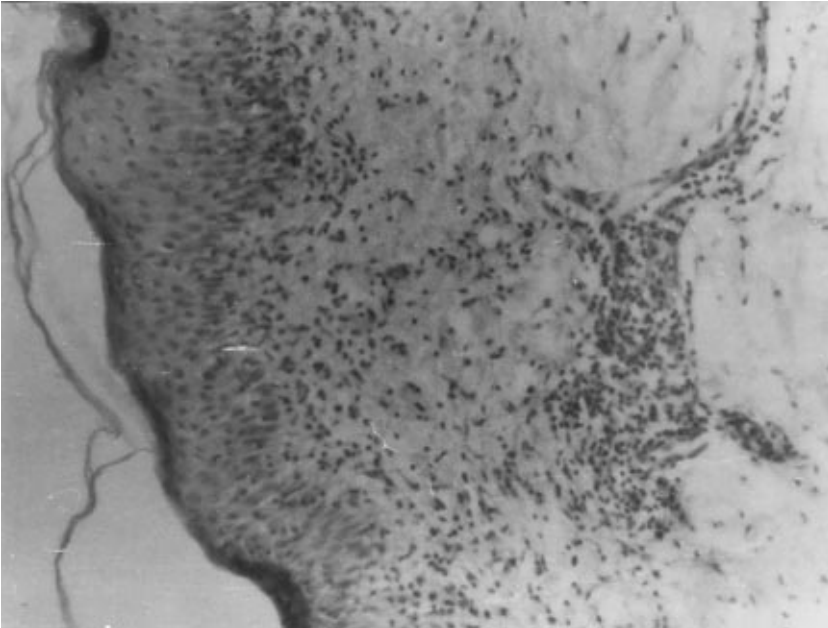


Figure 1 Skin biopsy (hematoxylin-eosin, X400): epidermal keratosis, hydropic degeneration in the basal cells prominent mixed infiltrate composed primarily of neutrophils and lymphocytes around the vessels

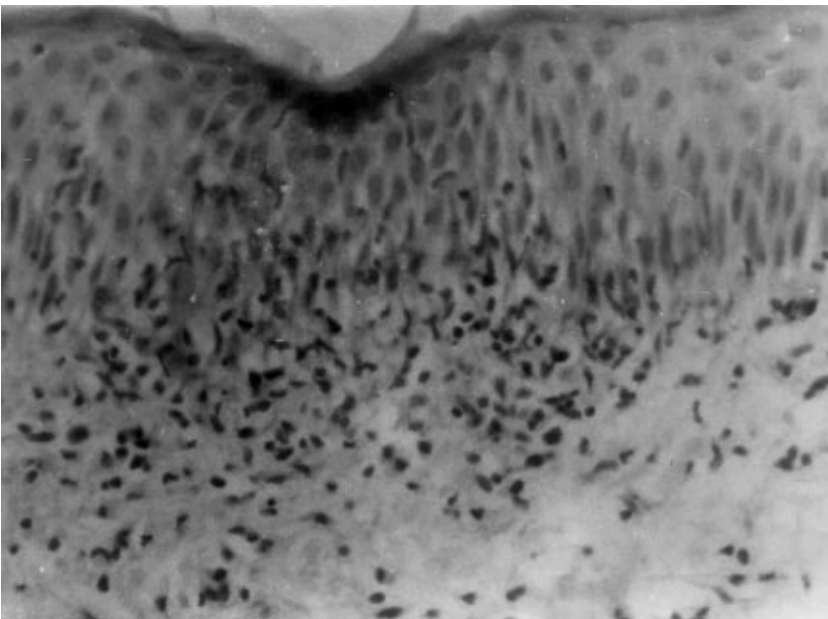


Figure 2. Skin biopsy (hematoxylin-eosin, X400): epidermal keratosis, hydropic degeneration in the basal cells prominent mixed infiltrate composed primarily of neutrophils and lymphocytes around the vessels

than 2 months may however, give negative results, with autoantibodies being formed in 6 months approximately (17). This explains the negative results for immunofluorescence studies and autoantibodies in our patients.

In conclusion, vancomycin, a potent antibiotic used in severe infections, has serious side effects. Lupuslike reaction is one of these side effects which should be included in the list of side effects of this antimicrobial agent.

References

1. Wilhelm MP. Vancomycin. *Mayo Clin Prac* 66: 1165-70, 1991.
2. Wenzel RP. The emergence of methicillin-resistant *Staphylococcus aureus*. *Ann Intern Med* 97: 440-42, 1982.
3. Wade JC, Schimpff SC, Newman KA, Wiernik PH. *Staphylococcus epidermidis*: an increasing cause of infection in patients with granulocytopenia. *Ann Intern Med* 97: 503-8, 1982.
4. Polk RE, Healy DP, Schwartz LB, rock DT, Garson ML, roller K. Vancomycin and the red-man syndrome: pharmacodynamics of histamine release. *J Infect Dis* 157: 502-7, 1988.
5. Polk RE, Israel D, Wang J, Venitz J, Miller J, Stotka J. Vancomycin skin tests and prediction of "red man syndrome" in healthy volunteers. *Antimicrob Agents Chemother* 37: 2139-43, 1993.
6. Duffull SB, Begg EJ. Vancomycin toxicity. What is the evidence for dose dependency. *Adverse Drugs React Toxicol Rev* 13: 103-14, 1994.
7. Laurencin CT, Horan RF, Senatus PB, Wheeler CB, Lipson SJ. Stevens-Johnson type reaction with vancomycin treatment. *Ann Pharmacother* 26: 1520-21, 1992.
8. Vidal C, Quintela AG, Fuente R. Toxic epidermal necrolysis due to vancomycin. *Ann Allergy* 68: 345-47, 1992.
9. Markman M, Lim HW, Bluestein HG. Vancomycin-induced vasculitis. *South Med J* 79: 382-3, 1986.
10. Pearson DA. "Red man syndrome" with vancomycin: a report case. *J Am Dent Assoc* 118: 59-60, 1989.
11. Levy JH, Marty AT. Vancomycin and adverse drug reactions. *Crit Care Med* 21: 1107-8, 1993.
12. Clayman MD, Capaldo RA. Vancomycin allergy presenting as fever of unknown origin. *Arch Intern Med* 149: 1425-6, 1989.
13. Conley NS, Weiner RS, Hiemenz JW. Rigors with vancomycin. *Ann Intern Med* 115: 330, 1991.
14. Rowell NR, Goodfield MJD. The connective tissue diseases. (Eds. Rook A, Wilkinson DS, Ebling FJG, Champin RH, Burton JL) *Textbook of Dermatology*. Oxford: Blackwell Scientific Publications 1992, pp: 2163-2294.
15. Lever F, Schaumburg G. Eruptions due to drugs. In: *Histopathology of the skin*. Philadelphia: Lippincott, 1990 pp: 284-297.
16. Breathnach SM. Drug reactions. (Eds. Rook A, Wilkinson DS, Ebling FJG, Champin RH, Burton JL) *Textbook of Dermatology*. Oxford: Blackwell Scientific Publications, 1992, pp: 2961-3035.
17. Lever F, Schaumburg G. Connective tissue diseases. In: *Histopathology of the skin*. Philadelphia: Lippincott 1990, pp: 494-522.