

1-1-1999

A Combined Variation in the Gluteal Region

ZELİHA KURTOĞLU

M. HALUK ULUUTKU

Follow this and additional works at: <https://journals.tubitak.gov.tr/medical>



Part of the [Medical Sciences Commons](#)

Recommended Citation

KURTOĞLU, ZELİHA and ULUUTKU, M. HALUK (1999) "A Combined Variation in the Gluteal Region," *Turkish Journal of Medical Sciences*: Vol. 29: No. 5, Article 14. Available at: <https://journals.tubitak.gov.tr/medical/vol29/iss5/14>

This Article is brought to you for free and open access by TÜBİTAK Academic Journals. It has been accepted for inclusion in Turkish Journal of Medical Sciences by an authorized editor of TÜBİTAK Academic Journals. For more information, please contact academic.publications@tubitak.gov.tr.

Zeliha KURTOĞLU,
M. Haluk ULUUTKU

A Combined Variation in the Gluteal Region

Department of Anatomy, Faculty of Medicine
Karadeniz Technical University
61080-Trabzon-Turkey

Received: September 14, 1998

Key Words: Nerve compression, variations,
buttocks, sciatic nerve, piriformis muscle.

A combined variation was identified in the left gluteal region of a new-born cadaver. The piriformis muscle consisted of a large upper part and a smaller lower part. The common peroneal nerve and a very small part of the posterior femoral cutaneous nerve passed through these two parts of the muscle. The common peroneal nerve formed the sciatic nerve by combining with the tibial nerve when it reached the lower part of the muscle. The two components of the sciatic nerve ran normally along the thigh in the same sheath, reaching the popliteal fossa, and then separated into two parts.

The thin bundle of posterior femoral cutaneous nerve passing through the muscle combined with the thick bundle in the usual way in the medial of the sciatic nerve. It spread over the posterior surface of the thigh. In addition to this, the inferior gluteal artery and inferior gluteal nerve in the lateral of the common peroneal nerve passed between the two parts of the piriformis muscle. (Fig. 1).

It is not rare for the piriformis muscle to be penetrated by some structures which are supposed to pass through the greater sciatic foramen in the normal anatomical position (1-4). The positional relationships between this muscle and the nerves located in the gluteal area were studied in 13 groups by Chiba (4). In Chiba's study, the whole or a part of this common peroneal nerve passed through the piriformis muscle in 175 of 514 extremities. Previous studies do not support Chiba's results. In fact, the rates found in similar studies were not as high. Lee and Tsai reported that this rate was 19.6 % in 168 lower extremity dissections, while Beaton and Anson reported a rate of 10 % in a series of 2250 samplings, and Hallin also determined 10 % (1-37).

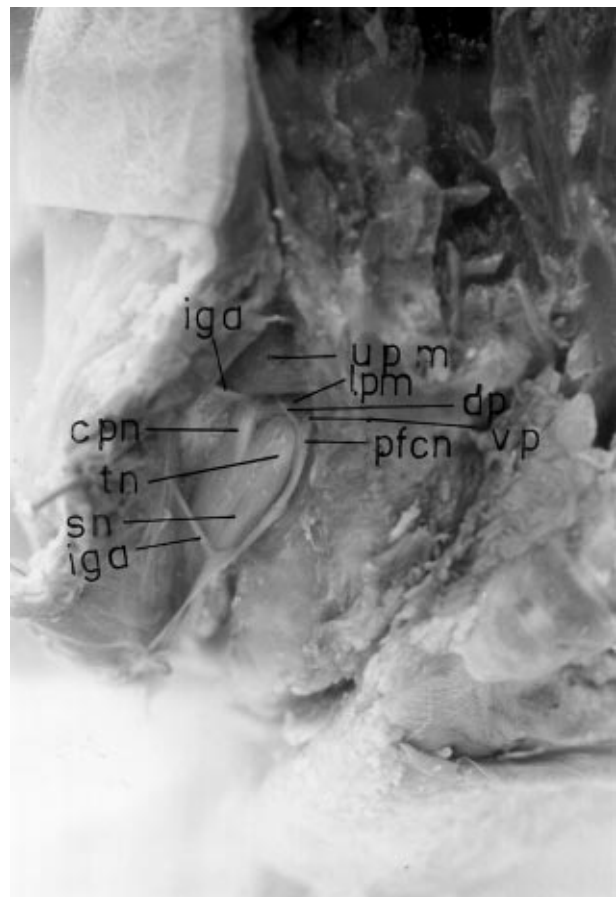


Figure 1. Location of the structures in the gluteal region. upm: upper piriformis muscle, lpm: lower piriformis muscle, dp: dorsal part of the posterior femoral cutaneous nerve, vp: ventral part of the posterior femoral cutaneous nerve, pfcn: posterior femoral cutaneous nerve, tn: tibial nerve, cpn: common peroneal nerve, sn: sciatic nerve, iga: inferior gluteal artery

Chiba classified occurrences of the inferior gluteal nerve passing through the piriformis muscle together with the common peroneal nerve as Type V, and cases in which the posterior femoral cutaneous nerve passes through the muscle as type VII. Our case could be classified as type VII, but only the bundles of posterior femoral nerve coming from the dorsal roots passed through the muscle (4).

Occurrences of the whole of the sciatic nerve passing through the muscle were observed in 0.8 % of the cases studied by Beaton and Anson, and in 2.2 % of those examined by Parsons and Keith. Cases of the whole or only a part of the sciatic nerve passing over the piriformis muscle have also been reported (1-5). The most interesting finding in our case was that the ventral branches of the sacral plexus ran in their normal course while only the dorsal branches of the sacral plexus. Passed between the parts of the piriformis muscle. Unlike Arifoğlu's report, in our case, along with the dorsal branches of the posterior femoral cutaneous nerve, the ventral part also passed through the muscle (6).

A clinical table resulting from compression of the sciatic nerve or its components by the piriformis muscle is known as piriformis syndrome (3, 7-12). According to Papadopoulos et al., the incidence of piriformis syndrome is six times more frequent in females than in males (13).

The etiology is variable, mainly shown by modification of the piriformis muscle, such as hypertrophy, contracture or continuous micro sport traumas, direct trauma, and by anatomical modifications of the sciatic nerve passing completely or in part through the muscle (3, 7, 9, 11, 14). Symptoms appear when the thigh is adducted, flexed and internally rotated. This maneuver, described by Beatty and Parziale et al., can reveal the symptoms of piriformis syndrome (12, 15).

The inferior gluteal artery has been localized in the medial to sciatic nerve in the gluteal area. It was reported in a study by Gabrielli that this artery or a branch of it penetrated the nerve in 22.5 % of cases. In the same study, it was observed that the inferior gluteal artery penetrated the tibial nerve where it passed under the piriformis. In our case, however, the artery did not pass through the muscle. (16).

Chen reported that he encountered a patient with a sciatic nerve compressed between the parts of the bipartite piriformis muscle. In this case, the lower part of the piriformis muscle was dissected and thus complete relief was achieved (17).

In conclusion, knowledge of the possible anatomical variations of the nerves and tissues in this area may be helpful for accurate diagnosis.

References

1. Beaton LE, Anson BJ. The relation of the sciatic nerve and of its subdivisions to the piriformis muscle. *Anat. Rec.* 70: 1-5, 1937.
2. Lee C-S, Tsai T-L. The relation of the sciatic nerve to the piriformis muscle. *J. Formosan Med. Assoc.* 73: 75-80, 1974.
3. Hallin RP. Sciatic pain and piriformis muscle. *Postgrad. Med.* 74: 69-7, 1983.
4. Chiba-S. Multiple positional relationships of nerves arising from the sacral plexus to the piriformis muscle in humans. *Acta Anat. Nippon* 67: 691-724, 1992.
5. Parsns FG, Keith A. Sixth annual report of the committee of collective investigation of the Anatomical Society of Great Britain and Ireland. *J Anat and Physiol* 31: 31,1896.
6. Arifoğlu Y, Sürücü HS, Sargon MF, Tanyeli E, Yazar F. Double superior gemellus together with double piriformis and high division of the sciatic nerve. *Surgical Radiologic Anatomy* 19: 407-408, 1997.
7. Hollinshead WH. *Functional Anatomy of the Limbs and Back*, fourth edition. Press of W.B. Saunders Company, pp: 281-9, 1976.
8. Franklin C Wagner, Jr. MD. Compression of the lumbosacral plexus and the sciatic nerve. In: Rober M Szabo, MD (ed.) *Nerve Compression Syndromes Diagonosis and Treatments*. Thorofare, U.S.A., pp: 267, 1989.
9. Moore KL. *Clinically Oriented Anatomy*, third edition. Williams & Wilkins, Baltimore, U.S.A. pp: 412-20, 1992.
10. Lam AW, Thompson JF, McCarthy WH. Unilateral piriformis syndrome in a patient with previous melanoma. *Aust. NZJ Surgery* 63(2): 152-3, 1993.
11. Williams PL, Warwick R, Dyson M, Bannister LH. *Gray's Anatomy*, 38th edition. Churchill livingstone, Edinburgh, pp. 877-8, 1284-87, 1995.

12. Parziale JR, Hudgins TH, Fishman LM. The piriformis syndrome. *American Journal of Orthopedics* 25(12): 819-23, 1996.
13. Papadopoulos SM, McGillicuddy JE, Alberts LW. unusual case of piriformis muscle syndrome. *Arch. Neurologia* 47(10): 1144-6, 1990.
14. Kouvalchouk JF, Bonnet JM, de Mondenard JP. Pyramidal syndrome: apropos of 4 cases treated by surgery and review of the literature. *Service de Chirurgie Orthopedique et Traumatologie du Sport, C.M.C. Foch, Suresnes* 82(7): 647-57, 1996.
15. Beatty RA. The piriformis muscle syndrome: a simple diagnostic maneuver. *neurosurgery* 34 (3): 512-4, 1994.
16. Gabrielli C, Olave E, Sarmento A, mizusaki C, Prates JC. Abnormal extrapelvic course of the inferior gluteal artery. *Surgical radiologic Anatomy* 19: 139-142, 1997.
17. Chen WS. Bipartite piriformis muscle: an unusual cause of sciatic nerve etrapment. *Pain* 58(2): 269-72, 1994.