

1-1-1999

Some Variations in the Formation of the BrachialPlexus in Infants*

AHMET UZUN

SAİT BİLGİÇ

Follow this and additional works at: <https://journals.tubitak.gov.tr/medical>



Part of the [Medical Sciences Commons](#)

Recommended Citation

UZUN, AHMET and BİLGİÇ, SAİT (1999) "Some Variations in the Formation of the BrachialPlexus in Infants*," *Turkish Journal of Medical Sciences*: Vol. 29: No. 5, Article 13. Available at: <https://journals.tubitak.gov.tr/medical/vol29/iss5/13>

This Article is brought to you for free and open access by TÜBİTAK Academic Journals. It has been accepted for inclusion in Turkish Journal of Medical Sciences by an authorized editor of TÜBİTAK Academic Journals. For more information, please contact academic.publications@tubitak.gov.tr.

Ahmet UZUN¹
Sait BİLGİÇ²

Some Variations in the Formation of the Brachial Plexus in Infants*

Received: June 23, 1998

Abstract: The anatomical variations of the brachial plexus in human have clinical significance to surgeons, radiologists and anatomists. We studied some variations in the formation of 130 brachial plexuses in sixty-five infant cadavers (34 males, 31 females; aged 1-7 days). The brachial plexus consisted of the 5th, 6th, 7th, and 8th cervical spinal nerves and 1st thoracic spinal nerve (69.23%). We found that among the 130 plexuses, 30.77% also received a contribution from C4 (Fig.1, A). The variations in the formation of brachial plexuses were classified into three groups. Group 1 had a variation in the formation of the median nerve (10.77%), with fusion of three branches; one each coming from the lateral and medial cords; and one coming

directly from a branch of the anterior division of the middle trunk (Fig.3,A). Group 2 had three anterior division cords: a) the lateral cord formed from anterior division of the upper trunk (Fig.2, A); b) an "intermediate" cord formed from the anterior division of the middle trunk and c) the medial cord formed from the anterior division of the lower trunk (3.07%). In group 3, there was a rare variation of the medial cord (1.54%) which receives an anastomotic branch from the posterior division of the middle trunk (Fig.4, B). The anomalies of the human brachial plexus have clinical importance in diagnosis of injuries of the brachial plexus.

Key Words: Gross anatomy, brachial plexus, variations, infant cadavers

¹Department of Anatomy, Inonu University, School of Medicine, 44100 Malatya-Turkey

²Department of Anatomy, Ondokuz Mayıs University, School of Medicine, 55139 Samsun-Turkey

Introduction

The anatomical variations of the brachial plexus in human have been well described by many authors (1-5). The brachial plexus is a complex of nerves originating in the neck and axilla. It is formed by the union of the ventral rami of the fifth, sixth, seventh, and eighth cervical, and the first thoracic spinal nerves. This nerve plexus can receive small contributing branches from the ventral primary ramus of the fourth cervical (C⁴) or the second thoracic (T²) spinal nerves (2,3,6). The human brachial plexus has three trunks (upper, middle, and lower) and three cords (medial, lateral, and posterior) which divides into nerves of the upper extremities (7-9).

As the embryonic somites migrate to form the extremities, they bring their own nerve supply, so that each dermatome and myotome retains its original segmental innervation. Throughout somite migration, some of the nerves come into close proximity and fuse in a particular pattern, forming a plexus early in fetal life. However, the inclination of the neurovascular bundle

changes with growth and relative elongation of the neck and alterations of the ribs (10-12). Its location and osseous relations make the plexus vulnerable to damage by traction (10,13), especially during routine neck dissection (14), penetrating wounds, compression from cervical ribs, or damage to related vertebrae (15,16).

We have performed 130 anatomic dissections on 65 infants and present some variations of the human brachial plexus. These kinds of variations could be vulnerable to damage in radical neck dissections and in other surgical operations of the axilla.

Material and methods

The study was carried out in 130 brachial plexus of 65 newborn cadavers (34 males, 31 females; aged 1-7 days). All infant cadavers were supplied from the maternity hospital. All infants included in this study were born at term with no obvious external malformations. The cause of death was unknown. They were fixed in 10%

* This study was presented at 3rd. European Congress of Clinical Anatomy, Innsbruck, Austria, 1995

formalin, and the plexus dissections were carefully performed under a 4.8 X stereomicroscope (Carl-Zeiss) or 28 X loop magnification. The formation and course of the plexuses were traced to its branches in the distal arm. The length and diameter measurements of the roots of the brachial plexus were done under a 4.8 x stereomicroscope which has a ruler ranging from 1 to 12. The obtained results, were transformed into millimetric system by the help of micro-optic disc. All photographs of the brachial plexus were taken during the dissection.

Results

One hundred thirty plexuses (65 infants) were dissected, and showed some variations in the formation of the brachial plexus. Ninety brachial plexuses (69.23%) originated from the ventral rami of the fifth, sixth, seventh, and eighth cervical spinal nerves and the first tho-

racic spinal nerve. Cervical spinal nerves C5 and C6 unite to form a common stem, the upper trunk. The eighth cervical and the first thoracic spinal nerves unite to form a lower trunk while the seventh cervical nerve remains independent and forms the middle trunk. In 20 of the 65 infants (30.77%), a variant connection between the fourth cervical and the fifth cervical spinal nerves was demonstrated on the right side and the left sides (Fig. 1). The contribution from C₄ to C₅ was 25 mm long and 0.1 mm in diameter. The diameter of the roots measured from, 1.1 to 1.57 mm (C₅ = 1.1, C₆ = 1.45, C₇ = 1.57, C₈ = 1.27, T₁ = 1.1 mm). The length of the roots ranged from 5.53 to 10.52 mm (C₅ = 10.52, C₆ = 8.19, C₇ = 6.77, C₈ = 6.21, T₁ = 5.53 mm). In this study, no contribution was observed connecting the second thoracic spinal nerve to the brachial plexus. In 126 plexuses (96.93%), the lateral cord was formed by a union of the ventral divisions of the upper and middle trunks.




Figure 1. Anatomic preparation of the left brachial plexus of a newborn cadaver with a contribution from C₄ to C₅ (A); PN, phrenic nerve; UT, Upper trunk; MT, middle trunk; LT, lower trunk; SN, suprascapular nerve; MC, medial cord; PC, posterior cord; LC, lateral cord; AN, axillary nerve; RN, radial nerve; MCN, musculocutaneous nerve; LR, lateral root of the median nerve; MR, medial root of the median nerve; MN, median nerve; UN, ulnar nerve

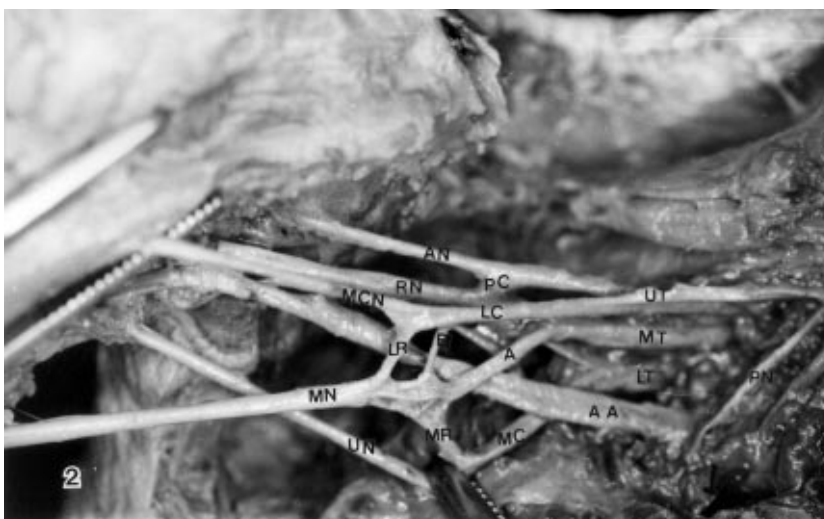

Figure 2. The right brachial plexus of a newborn cadaver showing a variation in the formation of the median nerve. A, the anterior division of the middle trunk contributes to the formation of the median nerve; B, proximal part of the lateral root of the median nerve. AA, axillary artery; UT, upper trunk; MT, middle trunk; LT, lower trunk; MC, medial cord; PC, posterior cord; LC, lateral cord; AN, axillary nerve; RN, radial nerve; MCN, musculocutaneous nerve; LR, lateral root of the median nerve; MR, medial root of the median nerve; MN, median nerve; UN, ulnar nerve

In four plexuses (3.07% on the right side), the lateral cord was only formed from the ventral division of the upper trunk. In these four plexuses we observed a variation in the formation of the median nerve. The median nerve was formed by fusion of three branches; one coming from two lateral radix branches of the lateral cord; one intermediate radix directly from the middle trunk; and the normal medial radix from the medial cord (Fig. 2). These findings were symmetrical in the two cadavers. In 14 of the 130 plexuses (10.77%), there was a con-

nection between the medial radix of the median nerve and the ventral division of the middle trunk (Fig. 3). Two of the plexuses (1.54% on the left side) had a branch which arose from the posterior division of the middle trunk and connected to the medial cord (Fig. 4). The distribution as to sex and side of the body of the observed variations are summarized in table 1. These results suggest that variations in the formation of the brachial plexus are not influenced either by sex or body side.

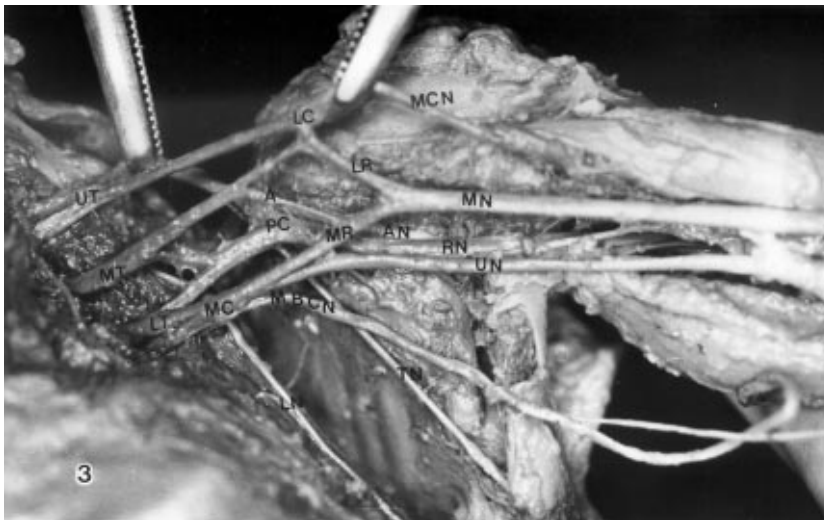

Figure 3. An anastomoses between the anterior division of the middle trunk and the medial root of the median nerve (A); UT, upper trunk; MT, middle trunk; LT, lower trunk; MC, medial cord; PC, posterior cord; LC, lateral cord; AN, axillary nerve; RN, radial nerve; MCN, musculocutaneous nerve; LR, lateral root of the median nerve; MR, medial root of the median nerve; MN, median nerve; UN, ulnar nerve; MBCN, medial cutaneous nerve of the arm; LN, long thoracic nerve; TN, thoracodorsal nerve

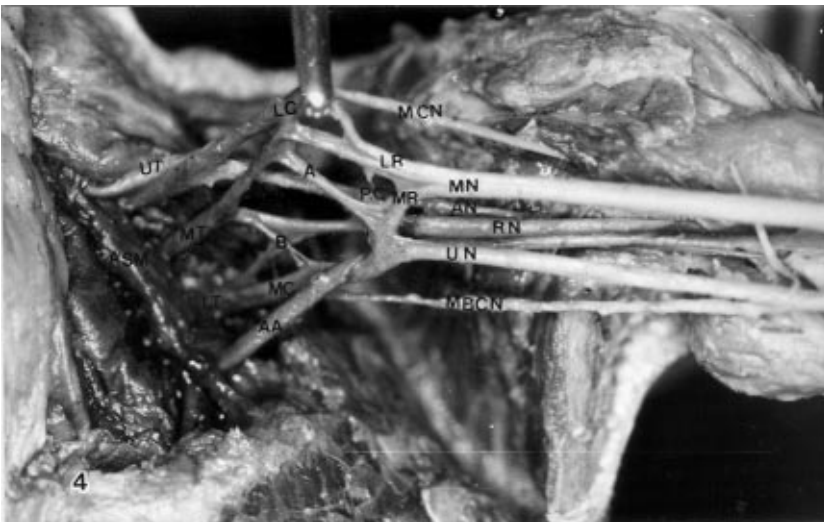


Figure 4. A connecting branch emerging from the anterior division of the middle trunk and joining to the medial cord (A); B, an abnormal communicating branch between the posterior division of the middle trunk and the medial cord. AA, axillary artery; ASM, anterior scalenus muscle; UT, upper trunk; MT, middle trunk; LT, lower trunk; MC, medial cord; PC, posterior cord; LC, lateral cord; AN, axillary nerve; RN, radial nerve; MCN, musculocutaneous nerve; LR, lateral root of the median nerve; MR, medial root of the median nerve; MN, median nerve; UN, ulnar nerve; MBCN, Medial cutaneous nerve of the arm.

	Male	Female	Male and Female		Number	Percent(%)
	Number	Percent(%)	Number	Percent(%)		
Right	16	27	14	23	30	50
Left	12	20	18	30	30	50
Total	28	47	32	53	60	100

Table 1. The distribution of plexuses according to sex and the side of the body

Discussion

The brachial plexus is a large and very important plexus that is situated partly in the neck and in the axilla (10). Although the plexus is normally formed from ventral rami C_5 to C_8 and T_1 , small contributions may come from the ventral rami of C_4 or T_2 (2,4,6). Variations in the pattern of the plexus can be due to abnormal formation in the development of the trunks, divisions, or cords (3). The more common variations in the brachial plexus are in its gross form at the level of the junction or separation of its component parts. Aside from improper distribution of cords which often introduce no change in the segmental origin of the branches (11). Walsh (5) was the first, who described anatomical variations in the formation of the brachial plexus in man. He reported an abnormal brachial plexus in 2 of the 350 plexuses. Kerr (2) reported that among 175 plexuses studied, 62% received nerve fibers from C_4 to C_5 . Cunningham (17) found fibers of the second thoracic spinal nerve joining to the first in 27 out of 37 cases. Harman (18) also found similar connections in 7 out of 12 dissections, and Paterson (19) reported the same distribution in 11 out of 33 cases. Harris (6) stated that only in the postfixed types (the postfixed plexus only forms from the 5th, 6th, 7th, 8th, T_1 and T_2) it might be expected that the second thoracic spinal nerve would join to the first and contribute to the plexus. In his report, the prefixed plexus (which forms from 4th, 5th, 6th, 7th, 8th, and T_1) was noted in about one fifth (21.5%) of instances and the postfixed plexus was found in only one instance. Lee et al. (20) studied variations of the ventral rami of the brachial plexus in 77 Korean adults and found that of 152 brachial plexuses only 21.7% received a fiber from C_4 to C_5 . In addition, of 117 plexuses only one case received a fiber from T_2 .

In 40 of the 130 plexuses in the present study, we observed connections from C_4 to C_5 (30.77%). These were all in the prefixed plexuses. We did not observe any connections from T_2 to T_1 . Kerr (2) also noted an anomaly in the formation of the cords of the plexus. The lateral cord apparently contained fibers from the 4th, 5th, 6th, and 7th cervical spinal nerves. In 3 of 175 cases, the lateral cord also received a contribution from the lower elements (one case from the lower trunk, and 2 from the eighth cervical spinal nerve). In our study, the lateral cord was often formed by the 4th, 5th, 6th, and 7th cervical spinal nerves (30.77%). However, in 86 plexuses, the lateral cord contained fibers from the 5th, 6th, 7th cervical spinal nerves and in 4 plexuses, the lateral cord only contained the anterior divisions of C_5 and C_6 of the upper trunk (3.07%). According to Hollinshead (11),

the medial cord of the brachial plexus typically represents only the continuation of the anterior division of the lower trunk, which contains only the eighth cervical and first thoracic fibers. Kerr (2) also reported this to be the usual origin in 94.58% of his specimens but in 5 cases the medial cord received a contribution from the seventh cervical spinal nerve. In the present study, the medial cord was mainly formed by the anterior division of the lower trunk (99.46%). In 2 cases (1.54%), the medial cord received fibers from the posterior division of the middle trunk. The median nerve usually has two roots, one of them from the lateral and the other one from the medial cords. Some variations in the formation of the median nerve have been described in textbooks of anatomy and surgery (7,8,11,21,22). In four of our 130 plexuses, the median nerve was formed by the union of three branches; two of them coming from the normal medial and lateral cords and one from the branch of the anterior division of the middle trunk.

Variations of the brachial plexus are often accompanied by abnormalities of vessels. This type of variation in the formation of the brachial plexus have been described by many authors (11,23,24,25). The upper extremity in the human is supplied by the axillary artery, and has an association to the division of the cords (25). During development, this artery derives from the 7th segmental artery and normally passes between the medial and lateral cords (26). However, if it originates from the 9th segmental artery, it can pass inferior to the medial cord (27,28). Thus, if the axillary artery had abnormal relations to the brachial plexus, the division of the cords would be modified by the presence of the abnormally placed artery. In our study, no apparent vascular varieties were demonstrated in the path of the axillary artery.

It can be said that anomalies of the brachial plexus can be found with vascular anomalies. As a conclusion, the anatomical variations of the human brachial plexus are very important to note during neck dissections where these unusual distributions can be prone to damage. They may also have clinical importance in diagnosis of injuries of the plexus.

Correspondence to:

Ahmet UZUN

Assistant Professor

Inonu University, School of Medicine

Department of Anatomy

44100-Kampus / Malatya, Turkey

References

1. Harris W. The true form of the plexus , and its motor distribution. *J Anat Physiol* 38: 399-442, 1904.
2. Kerr AT. The brachial plexus of nerves in man the variations its formation and branches. *Am J Anat* 23: 285-395, 1918.
3. Miller RA. Comparative studies upon the morfology and distribution of the brachial plexus. *Am J. Anat* 54: 143-175, 1934.
4. Miller RA, Detwiller SR. Comparative studies upon the origin and development of the brachial plexus. *Anat Rec* 3: 273-292, 1936.
5. Walsh JF. The anatomy of the brachial plexus. *Am J M Sci* 74:387-428, 1877.
6. Harris W. Prefixed and postfixed types of brachial plexus. *Brain* 26: 613-615, 1903.
7. Brash JC. Cunningham's tex-book of anatomy. 9th ed, Oxford University Press, London 1953, pp 1067-1085.
8. Clemente CD. Anatomy of the human body. 30th ed. Lea & Febiger, Philadelphia 1985, pp 1205-1207.
9. Groot J, Chusid JG. Correlative neuroanatomy. Prentice Hall Iternational Inc, New York 1985, pp 282-286.
10. Hershman EB. Brachial plexus injuries. *Clin Sports Med* 9: 311-319, 1990.
11. Hollinshead WH. Anatomy for surgeons. Vol 3.The back and limbs. 3rd ed, Haper & Low, Philadelphia 1982, pp 220 -223.
12. Sadler TW. Langman's medical embryology. 6th ed, Williams & Wilkins, Baltimore 1990, pp 203-225.
13. Abrams IF, Rosen BA. Neurologic trauma in newborn infants. *Seminars in Neurology* 3: 100-103, 1993.
14. Gacek RR. Neck dissection injury of a brachial plexus anatomical variant. *Arch Otolaryngol Head Neck Surg* 116: 356-358,1990.
15. Gao-meng Z, Yu-dong G. Root avulsion of brachial plexus in infants and children. *Chinese Medical Journal* 3: 424-427, 1990.
16. Hentz VR, Meyer RB. Brachial plexus microsurgery in children. *Microsurgery* 12:175-195, 1991.
17. Cunningham DJ. Note on a connecting twig between the anterior divisions of the first and second dorsal nerves. *J Anat Physiol* 11: 63-90, 1877.
18. Harman B. The anterior limit of the cervicothoracic visceral efferent nerves in man. *J Anat Physiol* 34: 357-380, 1900.
19. Paterson AM. A discussion of some points of the distribution of the spinal nerves. *J Anat Physiol*, 30: 350-358, 1896.
20. Lee HY, Chung H, Seok W, Kang S. Variations of the ventral rami of the brachial plexus. *J Korean Med Sci* 7 (1): 19-25, 1992.
21. April EW. Anatomy. Harwal Publishing Company, Toronto 1984, pp 68-73.
22. Moore KL. Clinically oriented anatomy. Williams & Wilkins, Baltimore 1980, pp 693-710.
23. Adachi B. Das arterien-system der Japoner. Bd1,Maruzen Company, Kyoto 1928, pp 197-372
24. Miller RA. Observations upon the arrangement of the axillary artery and brachial plexus. *Am J Anat* 64: 143-164, 1939.
25. Nakatani T, Tanaka S, Mizukami S. Superficial brachial arteries observed in bilateral arms. *Acta Anat Nippon* 71: 308-312, 1996.
26. Poynter WL. Congenital anomalies of the arteries and veins of the human body. *Univ Nebr* 22:1-105, 1920.
27. Tountas CB, Bergman RA. Anatomic variations of the upper extremity. Churchill Livingstone, New York 1993,pp 195-203.
28. Trotter M, Henderson JL,Grass H. The origins of branches of the axillary artery in whites and American negroes. *Anat Rec* 46:133-137, 1930.