

1-1-1999

Osteopoikilosis: Report of a Familial Case

ERCAN TUNÇ

SERPİL SAVAŞ

Follow this and additional works at: <https://journals.tubitak.gov.tr/medical>



Part of the [Medical Sciences Commons](#)

Recommended Citation

TUNÇ, ERCAN and SAVAŞ, SERPİL (1999) "Osteopoikilosis: Report of a Familial Case," *Turkish Journal of Medical Sciences*: Vol. 29: No. 6, Article 20. Available at: <https://journals.tubitak.gov.tr/medical/vol29/iss6/20>

This Article is brought to you for free and open access by TÜBİTAK Academic Journals. It has been accepted for inclusion in Turkish Journal of Medical Sciences by an authorized editor of TÜBİTAK Academic Journals. For more information, please contact academic.publications@tubitak.gov.tr.

Ercan TUNÇ¹
Serpil SAVAŞ²

Osteopoikilosis: Report of a Familial Case

Departments of ¹Internal Medicine and
²Physical Medicine and Rehabilitation, Faculty
of Medicine, Süleyman Demirel University,
Isparta-Turkey

Received: October 26, 1999

Key Words: Osteopoikilosis

Osteopoikilosis (osteopathia condensans disseminata, spotted bones) is an asymptomatic osteosclerotic dysplasia initially described by Albers-Schönberg in 1915 (1). This rare hereditary condition is usually noticed radiologically as an incidental finding of diagnostic sclerotic lesions. These lesions are symmetric, numerous, small, well-defined, homogeneous and circular or ovoid (2). The most frequently involved sites are the epiphyses and metaphyses of long tubular bones and the carpi, tarsi, pelvis and scapulae (1). Studies of familial occurrence indicate an autosomal dominant pattern of genetic transmission (3, 4, 5). Sporadic forms are also presented (6, 7). This disorder may resemble osteoblastic metastases, mastocytosis and tuberous sclerosis (1).

In this study we report a 30-year-old male with osteopoikilosis that has a mother with similar involvement.

A 30-year-old man was seen in the orthopedic outpatient clinic with the complaint of low back pain. Numerous symmetric, small, well defined, circular sclerotic bone lesions were found on the X-rays of the lumbar spine and pelvis (Figure 1). Osteoblastic bone metastases were suspected and the patient underwent a detailed radiographic examination. The same lesions were also found in his hands and feet (Figure 2). He was then sent to the department of internal medicine for a detailed examination. Physical examination was normal. Laboratory examinations including biochemistry,

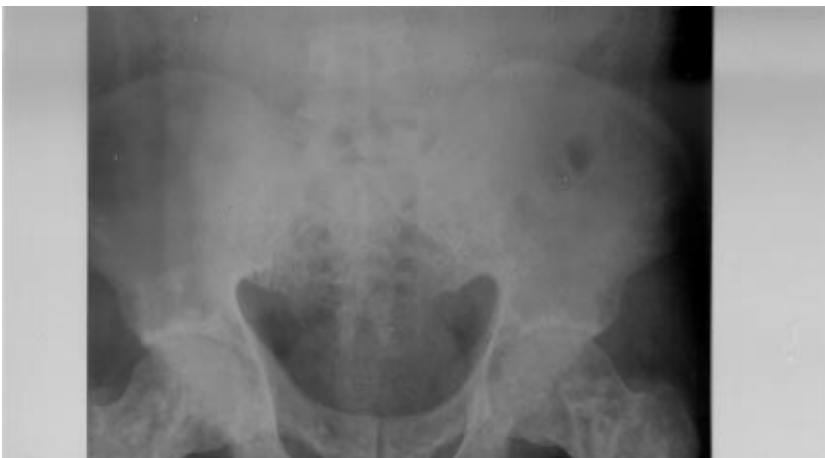

Figure 1. Osteopoikilotic lesions on lumbo-sacral roentgenogram of the patient

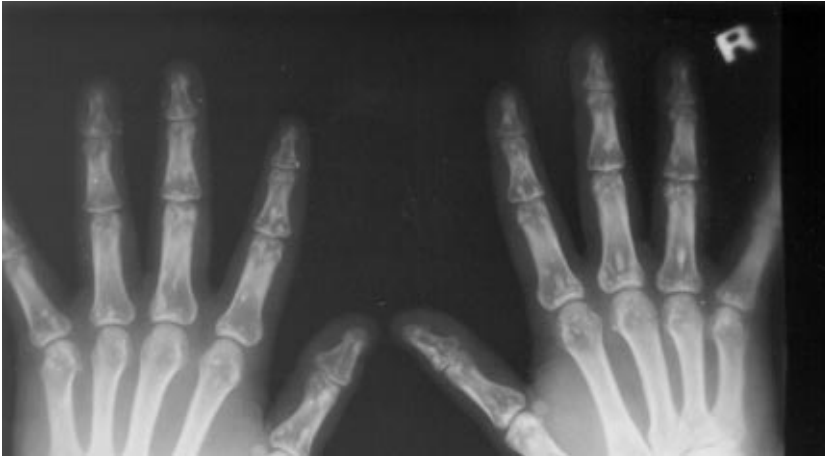

Figure 2. Osteopoikilotic lesions on hand roentgenogram of the patient.

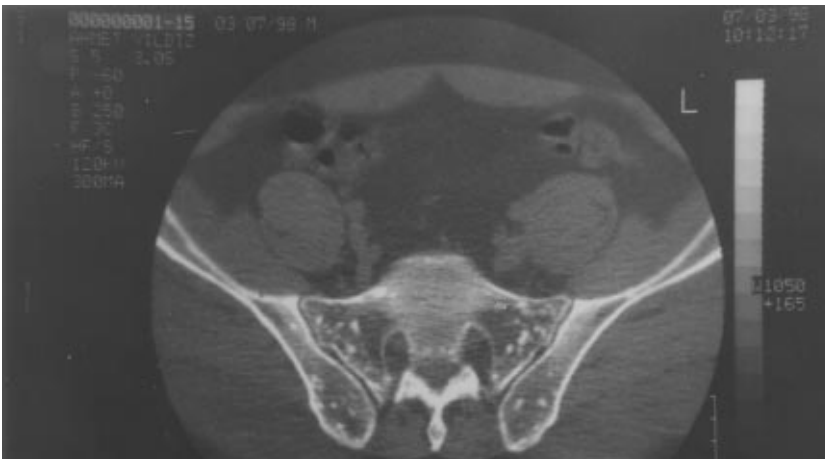

Figure 3. Computed tomography imaging showing numerous, symmetric, small, well-defined, circular sclerotic bone lesions characteristic for osteopoikilosis.

erythrocyte sedimentation rate and protein electrophoresis were normal. Bence Jones protein and tumor markers were negative. Urologic examination showed no abnormality. Bone scintigraphy and abdominal ultrasonography were also normal. No oncological disease was found. Computed tomography imaging was taken, and it showed right posterolateral disc herniation and numerous symmetric, small, well-defined, circular sclerotic bone lesions (Figure 3). With these characteristic lesions, the diagnosis of osteopoikilosis was made. Because of the familial nature of the disease, his family members were also evaluated. His mother was found to have the same lesions without any symptoms while his father and one of his brothers were lesion free (Figure 4). His other brother refused examination. The patient and his family were told about the nature of osteopoikilosis. The patient and his mother have been under observation since May 1998.

Osteopoikilosis is usually asymptomatic but in 15-20% of patients there may be slight articular pain and joint effusions (1). Our patient had right posterolateral disc herniation and these osteopoikilotic lesions were noticed incidentally. The cause and the pathogenesis of osteopoikilosis are not known. In an anatomico-pathological study of two cases with osteopoikilosis, Lagier et al. documented that the radiological appearance of rounded and linear densities corresponded to old and inactive remodeling of spongy trabeculae in epiphyseal and metaphyseal locations (8). On histological examination, these lesions were found to be composed of lamellar osseous tissue containing haversian systems. It was suggested that the lesions were not probably formed through enchondral ossification of cartilage rests.

A hereditary failure to form normal trabeculae along lines of stress is blamed in the pathogenesis (8). Furthermore, an altered osteogenesis may be responsible for the lesions (6). In the same report, the existence of

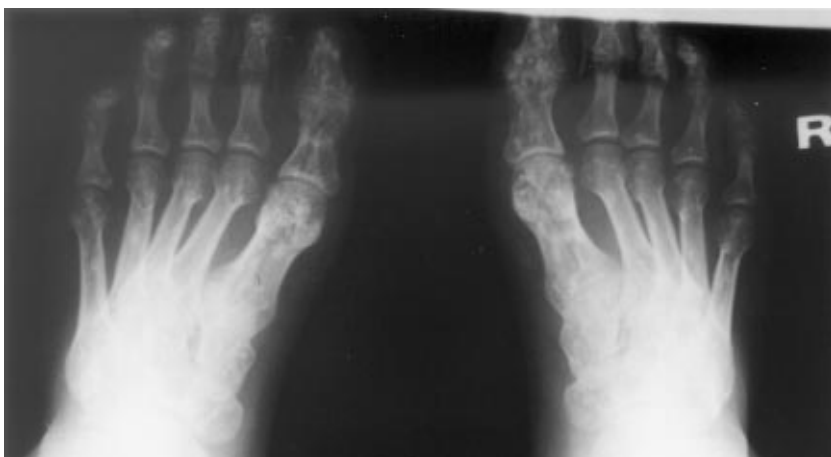


Figure 4. Osteopoikilotic lesions on feet roentgenogram of the patient's mother.

osteosarcoma and osteopoikilosis is reported. It has been suggested that osteosarcoma in this case may be related to active osteogenesis in osteopoikilosis. For this reason, early recognition and follow-up of osteopoikilotic patients is essential.

Osteopoikilosis is usually an asymptomatic condition and it is usually found radiologically as an incidental finding, as in our patient. Günel et al. have reported five members of a family with dacryocystitis with osteopoikilosis (3). They suggest that osteopoikilosis should not be considered a coincidental radiographic finding, but rather part of a systemic disorder. In approximately in 25% of cases, whitish fibrocollagenous infiltrations (Buschke-Ollendorf Syndrome) are found (9). There is also a predilection to keloid formation and scleroderma-like lesions (1). Spinal stenosis, dwarfizm, dystocia and mild articular pain with or without joint effusion have been reported in patients with osteopoikilosis (1, 10).

This disorder may resemble osteoblastic metastases, mastocytosis and tuberous sclerosis (1). Our patient was first diagnosed as having osteoblastic metastases, in which lesions are asymmetric and varied in size. And also a predilection for axial skeleton, osseous destruction and

positive scintigraphic findings differentiates osteoblastic metastases from osteopoikilosis. In patients with a known or suspected primary malignancy, radionuclide bone scan has a critical role in distinguishing osteopoikilosis from osteoblastic bone metastases. However, Mungovan et al. suggest that an abnormal bone scan does not exclude the diagnosis of osteopoikilosis in a young patient if the roentgenographic findings are characteristic of that entity (11). In both mastocytosis and tuberous sclerosis, symmetry, metaphyseal and epiphyseal preference, and uniform, well-defined foci are less striking than in osteopoikilosis (1).

In conclusion, when uniform multiple radiodens lesions are found on radiographic examination, osteopoikilosis must be in the differential diagnosis before invasive diagnostic procedures and dangerous and unnecessary treatments are planned.

Correspondence author:

Serpil SAVAŞ

İstiklal Mah. Namık Kemal Cad.4/9

32300, Isparta-Turkey

References

1. Reznick D, Niwayama G. Enostris, hyperostosis and periostitis. Reznick D, Niwayama G. *Diagnosis of Bone and Joint Disorders*. W.B Saunders Company Philadelphia 1988. pp. 4084-4088.
2. Young LW, Gersman I, Simon PR. Radiological case of the month. Osteopoikilosis: familial documentation. *Am J Dis Child* 134(4):415-6, 1980.
3. Günel I, Seber S, Balaran N, et al. Dacryocystitis associated with osteopoikilosis. *Clin Genet* 44(4):211-213, 1993.

4. Benli IT, Akalyn S, Baysan E et al. Epidemiological and radiological aspects of osteopoikilosis. *J Bone Joint Surg Br* 74(4):504-6, 1992.
5. Sarralde A, Garcia CD, Nazara Z. Osteopoikilosis: report of a familial case. *Genet Couns* 5(4):373-5, 1994.
6. Mindell ER, Northup CS, Gouglass HO Jr. Osteosarcoma associated with osteopoikilosis. Case report. *J Bone Joint Surg [Am]* 60:406-408, 1978.
7. Agostinelli JR. Osteopoikilosis. A case report. *J Am Podiatry Assoc* 73(10):529-31, 1983.
8. Lagier R, Mbakop A, Bigler A. Osteopoikilosis: a radiological and pathological study. *Skeletal Radiol* 11(3):161-8, 1984.
9. Roberts NM, Langtry JA, Branfoot AC. Case report: Osteopoikilosis and the Buschke-Ollendorff syndrome. *Br J Radiol* 66(785):468-70, 1993.
10. Weisz GM. Lumbar spinal canal stenosis in osteopoikilosis. *Clin Orthop* 166:89-92, 1982.
11. Mungavan JA, Tung GA, Lambiase RE et al. Tc-99m MDP uptake in osteopoikilosis. *Clin Nucl Med* 19(1):6-8, 1994.