

1-1-2000

A Criterion in the Differential Diagnosis of Aneurysms of the Superficial Veins of the Lower Extremity From Other Cystic Lesions of the Soft Tissues-the "Apostrophe" Sign

İLGİNÇ YORULMAZ

EGEMEN TÜZÜN

Follow this and additional works at: <https://journals.tubitak.gov.tr/medical>



Part of the [Medical Sciences Commons](#)

Recommended Citation

YORULMAZ, İLGİNÇ and TÜZÜN, EGEMEN (2000) "A Criterion in the Differential Diagnosis of Aneurysms of the Superficial Veins of the Lower Extremity From Other Cystic Lesions of the Soft Tissues-the "Apostrophe" Sign," *Turkish Journal of Medical Sciences*: Vol. 30: No. 1, Article 16. Available at: <https://journals.tubitak.gov.tr/medical/vol30/iss1/16>

This Article is brought to you for free and open access by TÜBİTAK Academic Journals. It has been accepted for inclusion in Turkish Journal of Medical Sciences by an authorized editor of TÜBİTAK Academic Journals. For more information, please contact academic.publications@tubitak.gov.tr.

İlginç YORULMAZ¹
Egemen TÜZÜN²

A Criterion in the Differential Diagnosis of Aneurysms of the Superficial Veins of the Lower Extremity From Other Cystic Lesions of the Soft Tissues-the “Apostrophe” Sign

School of Medicine, Departments of¹ Radiology and ²Cardiovascular Surgery, Celal Bayar University, Manisa-Turkey

Received: April 13, 1999

Long-standing or extensive varices of the lower extremity can occasionally take focal forms of marked vascular dilatation similar to a venous aneurysm. Those aneurysms originating from the lesser saphenous vein system can dangerously mimic cystic lesions of soft tissues in the popliteal fossa mostly Baker's cysts, which are simply sinovial lined cysts secondary to degenerative or chronic arthritides of the knee joint (1). In cases of misdiagnosis, patients may undergo unnecessary orthopedic operations for the so-called Baker's cysts of the popliteal fossa (2) and face tragic complications. Because the age groups of the two pathologic conditions do not differ from each other considerably and varices

and Baker's cysts may coexist in many patients, the authors propose a criterion in the differential diagnosis of aneurysms of the superficial veins of the lower extremity from other cystic lesions of the soft tissues: the “apostrophe” sign.

A 54-year-old female patient who had suffered from extensive varices of both of the lower extremities for about twenty-five years was referred for color Doppler ultrasonographic examination. During this examination, a cystic lesion of 3 X 1.5 cm in diameter was detected in the left popliteal fossa (Figure 1). At first glance this cyst could easily have been mistaken for a Baker's cyst, however, scrutinization of the lesion revealed a “whirling”

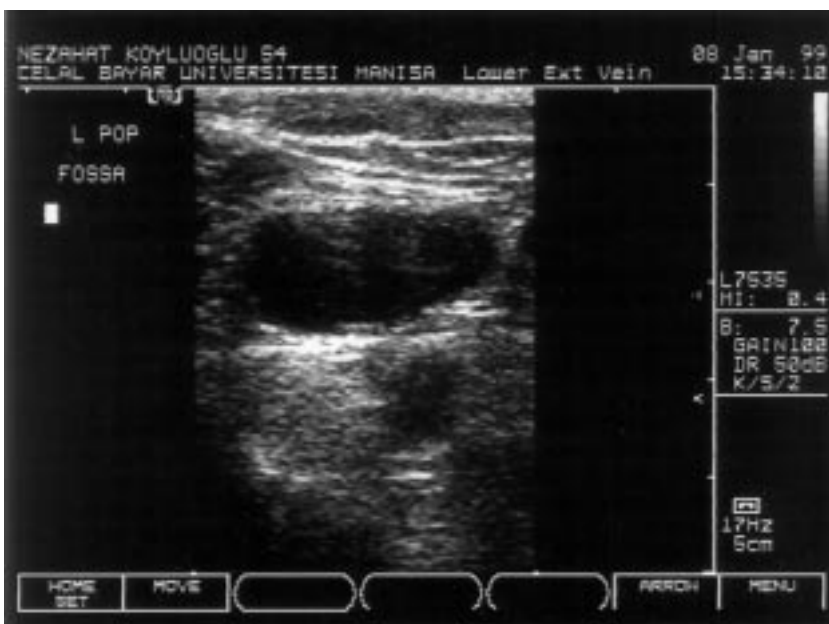

Figure 1. A “cystic” lesion of 3 X 1.5 cm is detected in the left popliteal fossa, which, at first glance, could easily have been mistaken for a Baker's cyst, in a 54-year-old female patient who suffered from extensive varices of both of the lower extremities for about twenty-five years.

motion within the cyst and a connection with the lesser saphenous vein resembling the "apostrophe" (Figure 2). Color-coded ultrasonography demonstrated venous flow within the cyst and within the connection, the apostrophe. The lesion was interpreted to be a venous aneurysm, a marked focal dilatation of the superficial veins. A smaller venous aneurysm was present in the right popliteal fossa, also related to the lesser saphenous vein. The patient had bilateral marked reflux of saphenofemoral and saphenopopliteal junctions and simple ligation and excision of the lesions were recommended. She did not give consent for the operation and was scheduled for follow-up for the theoretical risk of pulmonary embolism (3, 4).

"Aneurysms" of the lesser saphenous vein are rare lesions. Although color Doppler ultrasonography is the definitive non-invasive modality for the demonstration of flow within the lesion confirming its vascular nature, there are some aneurysms that are totally thrombosed. Furthermore, color coded ultrasonography is not available in all the centers dealing with soft tissue sonography, and there is always a potential risk of misdiagnosis because complicated Baker's cysts can occasionally mimic the symptoms of deep vein thrombosis (5). In those cases the presence of a connection resembling an apostrophe, of the lesion with the lesser saphenous vein system may be a crucial clue for diagnosis.

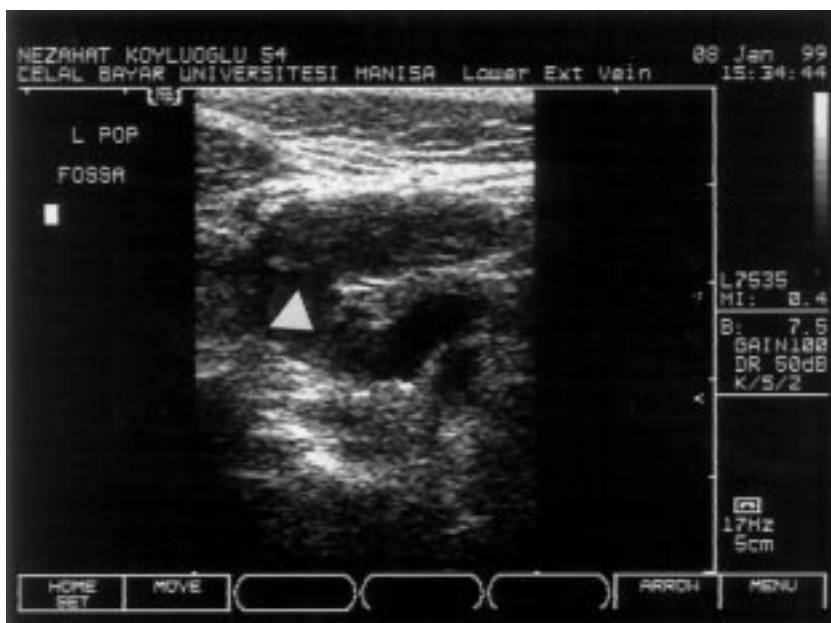


Figure 2. The lesion demonstrates communication with the lesser saphenous vein in the shape of an apostrophe, the "apostrophe" sign, confirming its vascular nature (▲). Note also the echogenicities within the lesion which are secondary to flow motion and partial thrombosis.

References

1. Braunstein EM, Silver TM, Martel W, Jaffe M. Ultrasonographic diagnosis of extremity masses. *Skeletal Radiol* 6: 157-163, 1981.
2. Okçu G, Tüzün E, Öziç U, Özmen M. Short saphenous vein aneurysm mimicking ruptured Baker's cyst: case report. *Tr J Thoracic Cardiovasc Surg* 6:160-2, 1998.
3. Ramadan F, Johnson G. Primary lesser saphenous vein aneurysm in a child. *J Ped Surg* 26:738-40, 1991.
4. Sarap MD, Wheeler WE. Venous aneurysms. *J Vasc Surg* 8:182-3, 1988.
5. Langsfeld M, Matteson B, Johnson W, Wascher D, Goodnough J, Wrinstein E. Baker's cysts mimicking the symptoms of deep vein thrombosis: diagnosis with venous duplex scanning. *J Vasc Surg* 25:658-62, 1997.