

1-1-2000

MRI in Joubert Syndrome

NAİL BULAKBAŞI

TANER ÜÇÖZ

CEM TAYFUN

YÜKSEL PABUŞÇU

ALPER ALEMDAROĞLU

Follow this and additional works at: <https://journals.tubitak.gov.tr/medical>



Part of the [Medical Sciences Commons](#)

Recommended Citation

BULAKBAŞI, NAİL; ÜÇÖZ, TANER; TAYFUN, CEM; PABUŞÇU, YÜKSEL; and ALEMDAROĞLU, ALPER (2000) "MRI in Joubert Syndrome," *Turkish Journal of Medical Sciences*: Vol. 30: No. 2, Article 21. Available at: <https://journals.tubitak.gov.tr/medical/vol30/iss2/21>

This Article is brought to you for free and open access by TÜBİTAK Academic Journals. It has been accepted for inclusion in Turkish Journal of Medical Sciences by an authorized editor of TÜBİTAK Academic Journals. For more information, please contact academic.publications@tubitak.gov.tr.

Nail BULAKBAŞI
Taner ÜÇÖZ
Cem TAYFUN
Yüksel PABUŞÇU
Alper ALEMDAROĞLU

MRI in Joubert Syndrome

Department of Radiology, Gülhane Military
Medical Academy, Ankara-Turkey

Received: September 18, 1998

Key Words: MRI, Joubert, Syndrome.

The patient was an 8-month-old boy who was the product of a full-term and uncomplicated pregnancy. He had a remarkable family history with the presence of the same clinical course in a cousin, who was not clearly diagnosed as having Joubert Syndrome. He had apnea episodes, truncal ataxia, pendular nystagmus and mental-motor developmental delay. He had a normal vestibulo-ocular reflex based on head thrust, but had absent-to-poor ability to cancel the vestibulo-ocular reflex horizontally and vertically.

CT findings were less prominent than MRI findings because of the Hounsfield artefacts seen in the imaging of the posterior fossa. This case was misdiagnosed as the Dandy-Walker Variant as a result of CT findings.

In axial, sagittal and coronal T1-weighted and axial proton density (PD) and T2-weighted spin echo images, cerebellar vermis was not imaged at the normal anatomical localisation (Figure 1). The fourth ventricle was wider than normal, appearing in the shape of a bat's wing in axial images. Because of the vermian dysplasia, there was elongation and stretching in nearly horizontal superior cerebellar peduncles, which were surrounded by CSF, and widening of the foramen of Magendie. The cerebellar hemispheres apposed one another in midline. This caused a "molar tooth" appearance on the axial images. Supratentorial structures were normal except for hypoplasia of the corpus callosum, which appeared to be thin on T1 weighted images. He was also clinically diagnosed as having Joubert Syndrome.

Discussion

Joubert Syndrome is a rare autosomal recessive disease and its incidence has not yet been accurately established. The biochemical basis of Joubert Syndrome is unknown. The WNT1 gene has been cited as its cause, but this has not been proved in humans (9). A link between the CHARGE association (Coloboma of the eye, Heart defect, Atresia of the choana, Retarded growth and development, Genital hypoplasia, and Ear anomalies or deafness) and Joubert Syndrome has been reported (10).

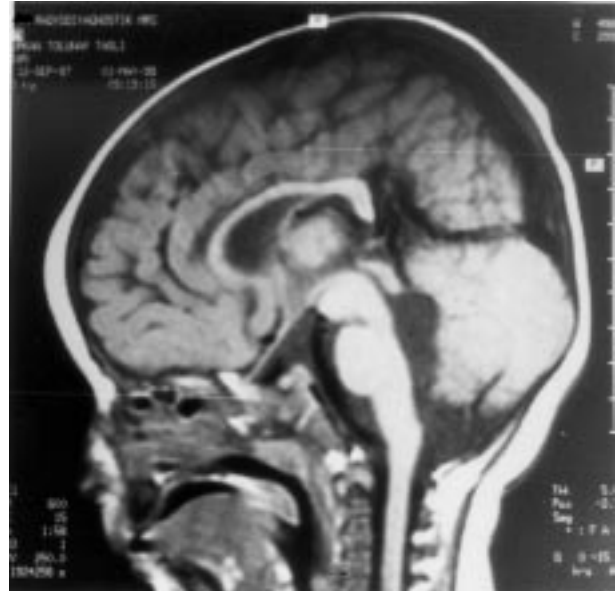

Figure 1a

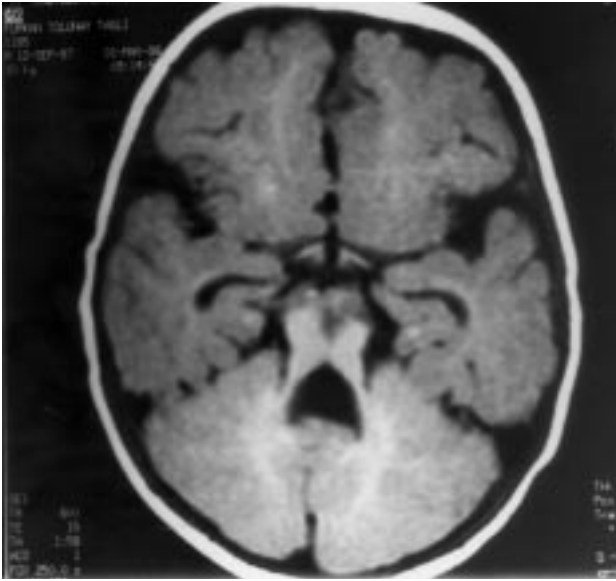


Figure 1b. a-b) MRI at 8 months. A. Mid-sagittal T1-weighted image shows vermian dysplasia and large fourth ventricle. B. Axial T1-weighted image through the cerebellar peduncles also shows typical Joubert Syndrome including a "molar tooth" appearance, deformed fourth ventricle in the shape of a bat's wing, hypoplastic cerebellar peduncles, which were surrounded by CSF, and apposition of cerebellar hemispheres to each other.

Cerebellar hypoplasia may present with a wide variety of neurological and systemic features, ranging from aplasia causing neonatal death to mild hypoplasia in an asymptomatic adult. Joubert Syndrome should be suspected in children in whom dysgenesis of the cerebellar vermis and hypoplasia of the brainstem are shown on CT or MRI. MRI clearly documents the size of the cerebellum and any associated abnormalities and is more effective in the demonstration of posterior fossa changes than CT (8). High-resolution multiplanar MRI provides good anatomical detail, with excellent distinction between grey and white matter. This technique allows improved detection of many classes of abnormalities of brain formation, some of which were previously detectable only at autopsy (7).

Prenatal diagnosis of Joubert Syndrome can be achieved by the detection of vermian hypoplasia and enlargement of the fourth ventricle in about the 20th week of gestation. However, Reynders et al. reported isolated localized fetal nuchal lucency (3 mm or greater) in 9-to-14-week fetuses without any additional sonographic abnormalities, in Joubert Syndrome (11). It is advisable to evaluate fetuses exhibiting isolated localized fetal nuchal lucency for Joubert Syndrome in later examinations (11).

In Joubert Syndrome, congenital hepatic fibrosis and congenital medullary cystic disease of the kidneys have been reported. It appears to be one of a spectrum of congenital malformation syndromes involving the central nervous system, eye, liver and kidneys (12,13). Associated anomalies in Joubert Syndrome are uncommon, but cerebral cortical dysplasia, dysgenesis of the corpus callosum, grey matter heterotopia, anomalous inferior olivary nuclei and brain stem tracts, encephalomeningocele, and complete lack of pyramidal decussation have been reported (4,5,6,8)

Considering the clinical course, episodic apnea, developmental delay, hypotonia, truncal ataxia, and ophthalmological abnormalities, this case could be regarded as Joubert Syndrome. The patient was not diagnosed prenatally. In our case there was a subtotal aplasia of the vermis, but there may be complete lack of the vermis in some patients (3,7,8). T1-weighted images showed characteristic MRI features of Joubert Syndrome, including dilatation of the fourth ventricle with some appearing to have the shape of a bat's wing, elongation and stretching of the superior cerebellar peduncles, dysplasia of the vermis, and widening of the foramen of Magendie. As a result of midbrain, vermian, and superior cerebellar peduncle abnormalities, axial neuroimaging showed a unique "molar tooth" appearance of these structures. This was a pathognomonic sign on MRI (3). Abdominal organs were evaluated as normal with sonographic examination.

Although the genetic and clinical features are different, there are significant anatomic resemblances with the Dandy-Walker Syndrome. Joubert Syndrome can be distinguished from Dandy-Walker malformation by the absence of cystic dilatation of the posterior fossa, hydrocephalus, the high position of the tentorium and hypoplasia of the cerebellar hemispheres.

Children with Joubert Syndrome usually die before 3 years of age, showing marked breathing problems and minimal mental development. Surviving children show variable motor development: walking is typically achieved between 2 and 10 years. Cognitive development is extremely disturbed with a development quotient of 30 or less. Siblings do not show similar development, and sex does not predict outcome. Ophthalmological and renal involvement may change or develop over the years and should be followed carefully (14).

In conclusion, Joubert Syndrome is an unusual congenital anomaly, occurring mainly with vermian dysplasia. It must be distinguished from other

malformations of the cerebellum like Dandy-Walker malformation, rhombencephalosynapsis and other cerebellar migration anomalies. MRI is the most effective method for accurate documentation of Joubert Syndrome and associated anomalies.

Correspondence author:
Nail BULAKBAŞI
Gülhane Askeri Tıp Akademisi
Radyodiagnostik ABD.
Etlik 06018 Ankara / TURKEY

References

1. Joubert M, Eisenring JJ, Robb JP, Andermann F. Familial agenesis of the cerebellar vermis. A syndrome of episodic hyperpnea, abnormal eye movements, ataxia and retardation. *Neurology* 19: 813-5, 1969.
2. Shen WC, Shian WJ, Chen CC, Chi CS, Lee SK, Lee KR. MRI of Joubert's syndrome. *Eur J Radiol* 18: 30-3, 1994.
3. Maria BL, Hoang KB, Tusa RJ, Mancuso AA, Hamed LM, Quisling RGI, Hove MT, Fennell EB. "Joubert syndrome" revisited: key ocular motor signs with magnetic resonance imaging correlation. *J Child Neurol* 12: 423-30, 1997.
4. Kendall B, Kingsley D, Lambert SR, Taylor D, Finn P. Joubert syndrome: a clinico-radiological study. *Neuroradiology* 31: 502-6, 1990.
5. Suzuki T, Hakozaki M, Kubo N, Kuroda K, Ogawa A. A case of cranial meningocele associated with Joubert syndrome. *Childs Nerv Syst*, 12: 280-2, 1996.
6. Friede RL, Boltshauser E. Uncommon syndromes of cerebellar aplasia. I. Joubert syndrome. *Dev Med Child Neurol* 20:758-63, 1978.
7. Barkovich AJ, Maroldo TV. Magnetic resonance imaging of normal and abnormal brain development. *Top Magn Reson Imaging* 5: 96-122, 1993.
8. deSouza N, Chaudhuri R, Bingham J, Cox T. MRI in cerebellar hypoplasia. *Neuroradiology* 36: 148-51, 1994.
9. Pellegrino JE, Lensch MW, Muenke M, Chance PF. Clinical and molecular analysis in Joubert syndrome. *Am J Med Genet*, 72: 59-62, 1997.
10. Menenzes M, Coker SB. CHARGE and Joubert syndromes: are they a single disorder? [see comments] *Pediatr Neurol*, 6:428-30, 1990.
11. Reynders CS, Pauker SP, Benacerraf BR. First trimester isolated fetal nuchal lucency: significance and outcome. *J Ultrasound Med*, 16:101-5, 1997.
12. Lewis SM, Roberts EA, Marcon MA, Harvey E, Phillips MJ, Chuang SA, Buncic JR, Clarke JT. Joubert syndrome with congenital hepatic fibrosis: an entity in the spectrum of oculo-encephalo-hepato-renal disorders. *Am J Med Genet*, 52: 419-26, 1994.
13. Silverstein DM, Zacharowicz L, Edelman M, Lee SC, Greifer I, Rapin I. Joubert syndrome associated with multicystic kidney disease and hepatic fibrosis. *Pediatr Nephrol*, 11: 746-9, 1997.
14. Steinlin M, Schmid M, Landau K, Boltshauser E. Follow-up in children with Joubert syndrome. *Neuropediatrics*, 28:204-11, 1997.