

1-1-2000

Klippel-Trenaunay Syndrome

PINAR POLAT

BEŐİR ERDOĐMUŐ

SUAT EREN

SELAMİ SUMA

ABDUL MECİT KANTARCI

Follow this and additional works at: <https://journals.tubitak.gov.tr/medical>



Part of the [Medical Sciences Commons](#)

Recommended Citation

POLAT, PINAR; ERDOĐMUŐ, BEŐİR; EREN, SUAT; SUMA, SELAMİ; and KANTARCI, ABDUL MECİT (2000) "Klippel-Trenaunay Syndrome," *Turkish Journal of Medical Sciences*: Vol. 30: No. 3, Article 17. Available at: <https://journals.tubitak.gov.tr/medical/vol30/iss3/17>

This Article is brought to you for free and open access by TÜBİTAK Academic Journals. It has been accepted for inclusion in Turkish Journal of Medical Sciences by an authorized editor of TÜBİTAK Academic Journals. For more information, please contact academic.publications@tubitak.gov.tr.

Pınar POLAT
Beşir ERDOĞMUŞ
Suat EREN
Selami SUMA
Mecit KANTARCI

Klippel-Trenaunay Syndrome

Department of Radiology, Faculty of Medicine,
Atatürk University, Erzurum-TURKEY

Received: September 03, 1999

Key Words: Klippel-Trenaunay Syndrome,
Plain radiography, Magnetic resonance
imaging.

Klippel-Trenaunay Syndrome (KTS) was first described by Klippel and Trenaunay in 1900. It is common in children and young adults and is characterized by soft tissue and bony hypertrophy, varicose venous structures and skin nevus which are unilateral and almost exclusively involve lower extremities. It is rarely bilaterally and involves upper extremities (1-4).

In this paper we present the radiologic findings of KTS in the light of previous findings.

A 30-month-old boy was brought in with the complaint of gradually increased size of his right lower extremity from birth. Soft tissue hypertrophy was detected in his right thigh, right dorsal region and scrotum. On the right leg, the skin had bluish discoloration. The leg was swollen and edematous. On plain radiography, we detected soft tissue hypertrophy, and there was length discrepancy between the right and left legs. The right femur was longer than the left (Figure 1). In color Doppler imaging, deep venous system was absent, multiple varicose veins were demonstrated under subcutaneous fatty tissue at the thigh, near and below the knee. The thickness of subcutaneous fatty tissue was also increased. No arterio-venous fistula was detected. In magnetic resonance imaging, subcutaneous fatty tissue at the dorsal region (Figure 2), and right leg was detected as increased thickness with the equal intensity of fatty tissue on T1 and T2-weighted sequences. Venous varicosities were demonstrated as a signal void on T1-weighted spin-echo sequences (Figure 3) and a bright signal on T2-weighted gradient-echo sequence (Figure 4).

The classic triad of KTS was venous abnormalities, cutaneous hemangiomas and hypertrophy at the involved

extremity. In addition to these findings, syndactyly, polydactyly and congenital hip dislocation can be seen as a part of this syndrome (2). The syndrome usually affects the unilateral and lower extremities but occasionally may be bilateral and involve the upper extremities. There is no sex preponderance or familial pattern. There may be hypoplasia, atresia or agenesis of the deep venous system at the involved extremity. So the venous return is provided via the superficial venous system. The superficial venous system becomes dilated and tortuous. The deep venous system is not normal in any case (4,5). In the study of Serville, fibrous cord and aberrant artery compressing the deep venous system was described (6). Parker and Weber described arterio-venous fistula in addition to classic triad and named it Parker-Weber syndrome (7). The hypertrophy of the involved extremity, the important clinic manifestation of the syndrome, is due to increased arterial flow caused by venous stasis and hemangiomas. The involved extremity is usually larger and longer than normal. Less frequently, intermittent claudication, varicose ulcers, increased skin temperature, hair loss, and dyskeratosis are seen (4,8).

Plain radiography gives useful information about the limb hypertrophy which is the cardinal manifestation of KTS. It is manifested as extremity length discrepancy. Other osseous anomalies such as syndactyly and polydactyly can be seen. The phleboliths shows the venous malformation and prior intralesional hemorrhage and thrombus.

Color Doppler imaging may be used to identify the deep venous system and tortuous and dilate superficial venous system. Arterio-venous fistula can be detected by its characteristic spectral analysis.

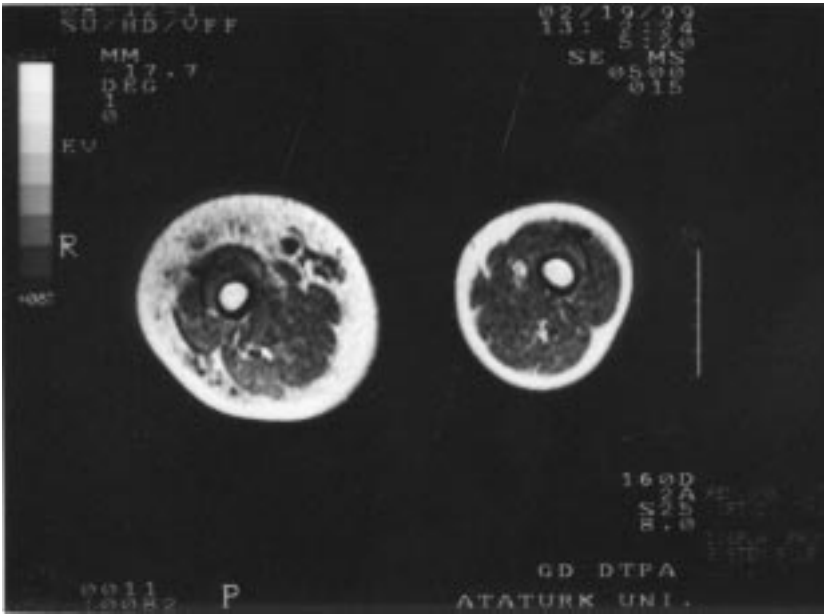


Figure 3. On spin-echo T1-weighted axial MR section, varicose venous dilatations are seen as a signal void, tubular structures under subcutaneous tissue, and there is also marked hypertrophy at subcutaneous fatty tissue.

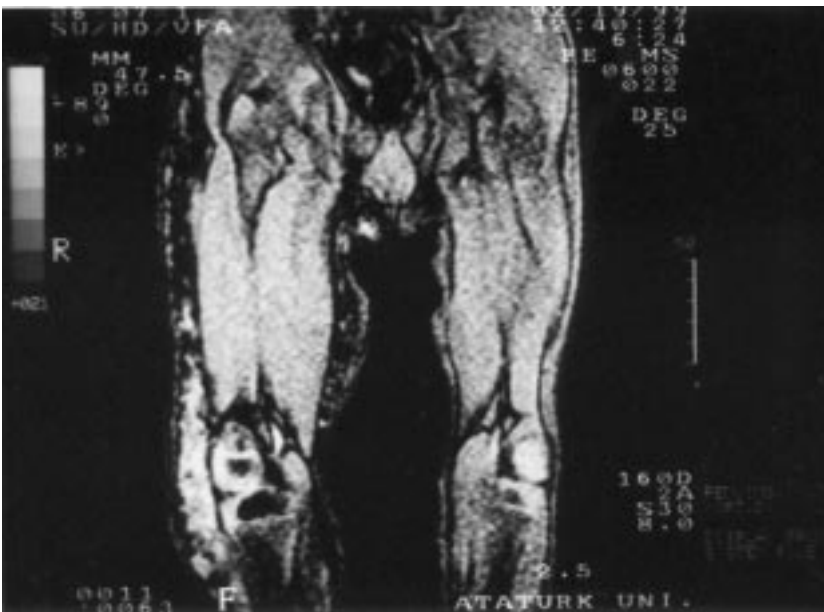

Figure 4. Varicose venous dilatations are well seen as bright signals on gradient-echo T2-weighted MR image.

Venography and arteriography is performed for treatment planning. Arterio-venous fistula associated with Parker-Weber syndrome can be detected by arteriography .

Magnetic resonance imaging can detect the soft tissue and bony extension of venous malformation. This information is important in surgical planning. Leg discrepancy is also detected by MR imaging. The signal intensity of vascular channels may vary depending on the

imaging parameters and flow velocities. Vascular channels are demonstrated as a signal void on spin-echo T1-weighted images and bright signal intensities on gradient echo T2-weighted images.

Correspondence author:
Pınar POLAT
İstasyon mah. Kombina cad.
Armağan Apt. 4/7 ERZURUM

References

1. Klippel M, Trenaunay P. Du noevus variqueux osteo-hipertrophique. Arch Gen Med 185: 641-672, 1900.
2. Kanterman RY, Witt PDT, Hsieh PS, Picus D. Klippel-Trenaunay syndrome: imaging findings and percutaneous intervention. AJR 167: 989-995, 1996.
3. Cihangirođlu M, Serhatliođlu S, Akfirat M, Murat A, Özdemir H., Üst ekstremitede geliřen Klippel-Trenaunay sendromu. TRD 33: 349-352, 1998.
4. Philips GN, Gordon DH, Martin EC et al. Klippel-Trenaunay Syndrome: Clinic and Radiological Aspects. Radiology, 28: 429- 434, 1978.
5. Lindenauer SM. The Klippel-Trenaunay Syndrome: varicosity, hypertrophy and hemangioma with no arteriovenous fistula. Ann Surg 162: 303- 314, 1965.
6. Servelle M. Lesions des varssequeux lympheticqus dans les malformations congenitales des veins profondes. Press Med. 65: 531, 1957.
7. Lindenauer SM. Congenital arteriovenous fistula and the Klippel-Trenaunay syndrome. Ann Surg, 174: 248- 263, 1971.
8. Belovic B, Nethercott J, Donsky HJ. An unusual variant of Klippel-Trenaunay-Weber. Can Med Assoc, 3: 439-444, 1974.