

1-1-2001

## Unusual Presentation of a Chondromyxoid Fibroma of the Temporal Bone

ASUMAN NİHAN HABERAL

BANU BİLEZİKÇİ

MEHMET COŞKUN

NUR ALTINÖRS

BEYHAN DEMİRHAN

Follow this and additional works at: <https://journals.tubitak.gov.tr/medical>

 Part of the [Medical Sciences Commons](#)

---

### Recommended Citation

HABERAL, ASUMAN NİHAN; BİLEZİKÇİ, BANU; COŞKUN, MEHMET; ALTINÖRS, NUR; and DEMİRHAN, BEYHAN (2001) "Unusual Presentation of a Chondromyxoid Fibroma of the Temporal Bone," *Turkish Journal of Medical Sciences*: Vol. 31: No. 1, Article 15. Available at: <https://journals.tubitak.gov.tr/medical/vol31/iss1/15>

This Article is brought to you for free and open access by TÜBİTAK Academic Journals. It has been accepted for inclusion in Turkish Journal of Medical Sciences by an authorized editor of TÜBİTAK Academic Journals. For more information, please contact [academic.publications@tubitak.gov.tr](mailto:academic.publications@tubitak.gov.tr).

Asuman Nihan HABERAL<sup>1</sup>  
Banu BİLEZİKÇİ<sup>1</sup>  
Mehmet COŞKUN<sup>2</sup>  
Nur ALTINÖRS<sup>3</sup>  
Beyhan DEMİRHAN<sup>1</sup>

## Unusual Presentation of a Chondromyxoid Fibroma of the Temporal Bone

Departments of <sup>1</sup>Pathology, <sup>2</sup>Radiology, and  
<sup>3</sup>Neurosurgery Faculty of Medicine, Başkent  
University, Ankara - TURKEY

Received: December 01, 1999

Chondromyxoid fibroma (CF) is an uncommon benign primary bone tumor that was first described by Jaffe and Lichtenstein in 1948 (1). CF usually originates from the long bones of young adults, but has been reported to occur in the small bones of the hands, feet, pelvis, vertebrae, and ribs (2). There is a slight gender bias in those affected, with 55% of patients being male and 45% being female (3). Most lesions occur in patients younger than 35 years, with a peak incidence of 36% in individuals 10 to 20 years of age (4). Our patient was a 45-year-old woman whose lesion was localized to the temporal bone. Interestingly, her radiology was not typical of CF. We report this case of CF because of the patient's age and the uncommon tumor location. We also examine it in the context of other similar cases that have been reported.

### Clinical History

A 45-year-old Turkish woman presented with complaints of 2.5 years' of pain on the left side of her face, and intermittent numbness. She had a history of trauma to the same site 5 years earlier. The patient's physical examination and laboratory values were normal. We used cranial computed tomography (CT) to investigate the cause of the pain. This revealed a lesion of 2.5x2.5x1.5 cm in the anterior portion of the tympanic region of the left temporal bone. The mass extended into the basis cranii and fossa cranii media posteroinferiorly. It

appeared to be invasive, and lytic changes scattering in the mass were visible. Some areas of the bone cortex had been eroded, and the lesion was thought to have originated in bone tissue. Hyperdense areas within the lesion were thought to represent calcification and ossification. The lesion had eroded the anterior temporal bone cortex, and had then invaded the bones of the middle ear. We noted that the mass was located very close to the left geniculate ganglion and left temporomandibular joint. In addition, chronic mastoiditis was determined bilaterally (Figure 1). The patient was referred to the Neurosurgery Clinic at our hospital and the lesion was excised macroscopically.

### Pathological Findings

Macroscopically, the material was 3x1.5x1 cm in size, yellowish to white-brown, and contained soft and hard components. After decalcification, paraffin sections of the mass were stained with hematoxylin-eosin for histological examination. Microscopically, we observed hypocellular lobules that had a myxochondroid appearance. The lobules were separated by intersecting bands of highly cellular tissue composed of fibroblast-like spindle cells and osteoclast-like giant cells. No mitotic figures were present (Figure 2). Based on these histologic findings, we diagnosed chondromyxoid fibroma. For confirmation, we stained the material with toluidine blue and analyzed for immunohistochemical reactivity with S-100 protein.

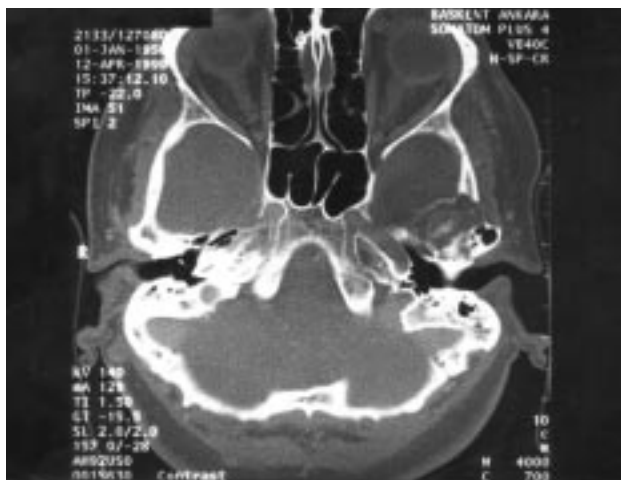


Figure 1. On CT, the anterior part of the tympanic portion of the temporal bone contains an invasive lesion with evidence of lysis. The lesion has eroded the bone cortex and calcification can be seen in the matrix.

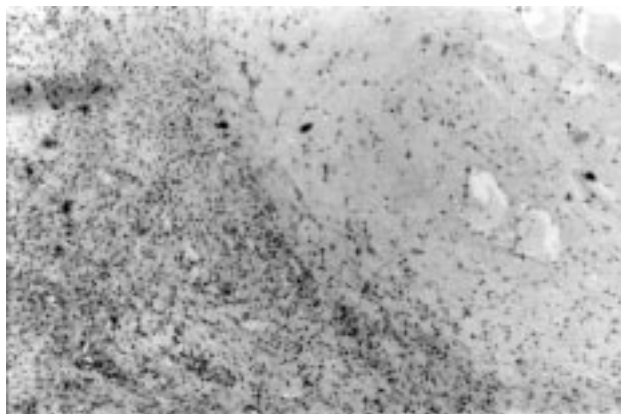


Figure 2. Elongated and stellate cells are present in the myxoid matrix. Hematoxylin and Eosin x 115.

There was a positive reaction to S-100, and toluidine blue staining showed metachromasia of the tumor matrix.

Chondromyxoid fibroma is a rare benign neoplasm that represents 0.4% to 0.5% of all primary bone tumors, and is a form of tumor that rarely affects the skull. The fact that cranial bones develop from endochondral tissue has led to the belief that CF arises from cartilage or embryonic rests of cartilage, which can be found in areas of synchondrosis at the base of the skull and at suture sites. Due to the slow growth of the tumor, symptoms are few and tend to be of long duration. Typically, the pain is mild and intermittent, with

the onset sometimes related to trauma. More superficial and expanded forms of the disease may involve mild swelling that progresses very gradually. When the cranial bones are affected, neurologic deficits are uncommon, but problems may arise as the tumor expands to involve adjacent structures, such as cranial nerves (5). In all locations, lesions tend to be well circumscribed radiographically, and often exhibit a sclerotic margin. They range in size from 2 to 10 cm maximal dimension (4). When the long bones are involved, typically, there is an area of metaphyseal osteolysis that is distinctly eccentric and superficial. This entire region is radiolucent, moderate in size, and is globose or more often oval, with its major axis parallel to the length of the diaphysis (6). An important radiographic feature of CF is the rarity of intralesional calcification.

CF has distinctive histologic features. Elongated or stellate cells are present in an abundant extracellular chondroid matrix. Two important features seen on low-power examination are a lobular growth pattern and sharp demarcation of the lesion from the surrounding bone. Cellularity is variable, but each lobule tends to be more cellular at the periphery. The peripheral cells are more spindle-shaped and appear to separate the lobules by fibrous bands. These bands contain blood vessels, and often osteoclast-like giant cells. No mature hyaline cartilage is present. Depending on the amount of proteoglycan secreted, the matrix may be myxoid or may have a bluish chondroid hue. Mitotic figures are extremely rare in CF. Immunohistochemical reactivity for S-100 protein is the rule, in keeping with the presumed cartilaginous origin of the tumor tissue (7). In our patient's lesion, the lobular pattern and osteoclast-like giant cells were not major features. It was thought that the poorly developed lobular pattern we observed was a result of the surgical procedure.

The differential diagnosis for CF that involves cranial bones includes chondrosarcoma, chondroblastoma and chordoma. Under light microscopy, CF is distinguished from chondrosarcoma by its lack of an invasive growth pattern, and the observation of tumor tissue encasing preexisting bony trabeculae. Other important features are the presence of a well-formed hyaline matrix and the absence of a fibrous component in chondrosarcoma. Immunocytochemistry is not helpful in distinguishing CF from chondrosarcoma because both tumors express S-100 protein (8).

Chondroblastoma is a rare benign neoplasm of fetal-type cartilage differentiation. Histologically, chondroblastoma is composed of sheets of stromal cells, scattered multinucleated giant cells, and varying amounts of eosinophilic chondroid matrix. The stromal cells, which resemble fetal chondroblasts, are distinctive. They are round, contain abundant cytoplasm, and they usually have distinct cytoplasmic membranes. The nuclei are also round and are located in the center of the cytoplasm, imparting a "fried egg" appearance to the cells. In most chondroblastomas, these stromal cells stain positive for S-100 immunohistochemically (4). Its age and site predilections also differ from CF (2, 4).

CF can be distinguished from chordoma by the chordoma's infiltrative margin and tissue containing large epithelial cells with eosinophilic or vacuolated cytoplasm. Chordoma cells are typically arranged in cohesive nests and cords. These tumors usually express epithelial

antigens, such as keratin and epithelial membrane antigens, but CF tissue does not stain with antibodies to these proteins (7).

For CF patients, wide excision of the tumor, taking care to include a rim of normal bone, is the treatment of choice when feasible.

This case was particularly interesting with regard to the greater age of the patient and the fact that the tumor affected the skull. The clinical and histological features of this neoplasm, and consideration of these with regard to differential diagnosis, led to our diagnosis of CF.

One year after the surgical procedure in April 1999, the patient complained of severe headaches. Follow-up CT showed a recurrent tumor. The histology of the resected tumor in April 2000 was similar to that recorded in April 1999. Two months later, the patient reported that her symptoms had lessened.

## References

1. Jaffe H, Lichtenstein L. Chondromyxoid fibroma of bone: a distinctive benign tumor likely to be mistaken, especially for chondrosarcoma. *Arch Pathol* 45: 541-551, 1998.
2. Rosai J. Bone and joints. Ackerman's surgical pathology (Ed. J Rosai). Mosby, United States of America 1996, pp: 1949-1952.
3. Anderson WJ, Bowers WH. Chondromyxoid fibroma of the proximal phalanx. A tumor that may be confused with chondrosarcoma. *J Hand Surg* 11 (1): 144-146, 1986.
4. McCarthy EF, Frassica FJ. Primary bone tumors. Pathology of bone and joint disorders with clinical and radiographic correlation (Eds. EF Mc Carthy, FJ Frassica). W.B. Saunders Company, United States of America 1998, pp: 221-227.
5. LeMay DR, Sun JK, Mendel E, Hinton DR, Giannotta SL. Chondromyxoid fibroma of the temporal bone. *Surg Neurol* 48:148-152, 1997.
6. Campanacci M. Chondromyxoid fibroma. Bone and soft tissue tumors (Ed. M Campanacci). Litosei. Italy: Bologna; 1990, pp: 253-264.
7. Bleiweiss IJ, Klein MJ. Chondromyxoid fibroma. Report of six cases with immunohistochemical studies. *Mod Pathol* 3: 664-666, 1990.
8. Keel SB, Bhan AK, Liebsch NJ, Rosenberg AE. Chondromyxoid fibroma of the skull base: a tumor which may be confused with chordoma and chondrosarcoma. *Am J Surg Pathol* 21 (5): 577-582, 1997.