

1-1-2001

Effects of Experimental Diabetes and Insulin Treatment on Rabbit Renal Morphology: A Quantitative and Qualitative Study

HÜSEYİN ERAY BULUT

BİLGE ONARLIOĞLU

CELAL KALOĞLU

ÖZTÜRK ÖZDEMİR

SEMİH AYAN

Follow this and additional works at: <https://journals.tubitak.gov.tr/medical>



Part of the [Medical Sciences Commons](#)

Recommended Citation

BULUT, HÜSEYİN ERAY; ONARLIOĞLU, BİLGE; KALOĞLU, CELAL; ÖZDEMİR, ÖZTÜRK; and AYAN, SEMİH (2001) "Effects of Experimental Diabetes and Insulin Treatment on Rabbit Renal Morphology: A Quantitative and Qualitative Study," *Turkish Journal of Medical Sciences*: Vol. 31: No. 3, Article 6. Available at: <https://journals.tubitak.gov.tr/medical/vol31/iss3/6>

This Article is brought to you for free and open access by TÜBİTAK Academic Journals. It has been accepted for inclusion in Turkish Journal of Medical Sciences by an authorized editor of TÜBİTAK Academic Journals. For more information, please contact academic.publications@tubitak.gov.tr.

Hüseyin Eray BULUT¹
Bilge ONARLIOĞLU¹
Celal KALOĞLU¹
Öztürk ÖZDEMİR²
Semih AYAN³

Effects of Experimental Diabetes and Insulin Treatment on Rabbit Renal Morphology: A Quantitative and Qualitative Study

Received: January 01, 2000

Abstract: Diabetes causes metabolic defects and related vascular alterations such as atherosclerosis. These vascular alterations may also reflect the renal structural degeneration under the influence of diabetes. Therefore, the aim of the present study was to determine qualitatively and quantitatively the effect of experimental diabetes on rabbit renal cortical structure, and also to evaluate the reversal rate of the renal structural alterations by daily insulin treatment.

Eighteen rabbits, bred and fed in standard laboratory conditions, were divided into 3 groups each containing 6 animals. While control group animals received no treatment, the rest were injected with a single dose of intravenous 100 mg/kg alloxan. Four days after injection, blood glucose levels were determined and diabetes was confirmed for each animal. Half of the animals were spared for the experimental diabetes group whereas the remaining half received daily intramuscular 1.5 I.U/kg injections of insulin (insulin therapy group) for 2 months. At the end of the experimental period, all of the animals were killed and the kidneys were obtained. Following the mean kidney weight and volume measurements, tissues were processed for light and electron microscopy. Renal features were evaluated quantitatively using appropriate stereological methods, whereas qualitative observations were

carried out under a Jenamed 2 light microscope and a Jeol 100C electron microscope. The quantitative data were compared statistically between the groups using Student's t-test.

The mean kidney weight and volume were significantly higher in the experimental diabetes group than in the control and insulin therapy groups. The volume fractions of renal corpuscle occupied by glomerulus and the cortex occupied by proximal tubulus were significantly higher in the experimental diabetes group than in the control and the insulin therapy groups, which was consistent with the qualitative observations. The increased glomerular and proximal tubular volume fractions were consistent with the increased mean kidney volume.

In conclusion, the qualitative findings of the present study were supported by quantitative evaluations such as the volume fractions and the mean kidney weight and volume. Therefore, it could be suggested that short-term experimental diabetes causes glomerular and tubular alterations, and those alterations might be reversed by daily insulin therapy.

Key Words: Experimental diabetes, insulin therapy, morphology, kidney, rabbit, stereology

Departments of Histology - Embryology¹,
Medical Biology and Genetics², Urology³.
Faculty of Medicine, Cumhuriyet University,
Sivas - TURKEY

Introduction

Diabetes, still a significant metabolic disease, is characterised by hyperglycaemia, glucosuria, polyuria and so on. Changes in carbohydrate and lipid metabolisms under the effect of diabetes result in atherosclerosis. Therefore, renal lesions are seen commonly in diabetic patients (1). The development of glomerulopathy in diabetic patients has always been an important field of research. To work on animal models could be useful in order to find answers to these questions.

Previous studies on the short-term effects of diabetes on kidney morphology have suggested cortical hypertrophy accompanied by glomerular mesangial hypertrophy (2,3,4), whereas long-term diabetes caused increased glomerular basement membrane thickness (4).

Another question arising is whether the adverse renal alterations caused by experimental diabetes could be prevented by daily insulin treatment. Several investigators have suggested the prevention of some metabolic changes following experimental diabetes, although it does not

have an effect on atherosclerosis accompanied by high serum insulin levels and hyperglycemia together (2,5).

The present study was designed to determine the effect of experimental diabetes on renal morphology in an animal model and to determine the prevention and/or reversibility of the potential effects of diabetes with daily insulin treatment using qualitative and quantitative morphological techniques.

Materials and Methods

Animals and Experimental Design

Eighteen rabbits were obtained from The Experimental Animal Laboratory, Cumhuriyet University, Sivas. They were divided into three groups, each containing 6 animals. While the control group animals received no treatment, the rest received only a single dose of intravenous 100 mg/kg alloxan. Four days after injection, blood samples were collected from the animals, blood glucose levels were determined, and diabetes was confirmed for each animal. Half of the animals were spared for the experimental diabetes group, whereas the remaining half received daily intramuscular 1.5 I.U/kg injections of insulin (insulin therapy group) for 2 months. Following the 2 months of the experimental period, diabetes was again confirmed by determining the blood glucose levels for each animal. All the animals were killed and the kidneys were collected. Renal cortical tissues were divided into pieces and processed for light and electron microscopy. Renal cortical tissue collection was carried out with standard tissue sampling techniques for morphometric analysis (6).

Microscopy

Light microscopy: Renal cortical tissue samples were fixed in Bouin's fixative, dehydrated through increasing concentrations of ethanol and embedded in paraffin. Then 4-5 μm thick tissue sections were stained with haematoxyline-eosin and periodic acid-Schiff (PAS) techniques. Appropriate fields of view from the renal cortex were evaluated under a Jenamed 2 light microscope.

Electron microscopy: Tissue samples obtained for electron microscopy were fixed with 3% glutaraldehyde in phosphate buffer, and then post-fixed in 1% aqueous osmium tetroxide. Following dehydration in increasing concentrations of ethanol, tissues were embedded in

Epon resin. While semi-thin tissue sections were stained with toluidin blue, ultra-thin sections were double stained with uranyl acetate saturated in 70% ethanol and lead citrate respectively. The ultrathin sections were evaluated under a Jeol 100C electron microscope.

Morphometry

Total kidney weights were measured, and the mean weights were calculated. Total kidney volumes were also measured by the fluid replacement technique (6), and the mean volumes were determined.

In order to obtain a descriptive morphology of rabbit renal cortex following experimental diabetes and insulin therapy, a wide range of cortical features were evaluated using appropriate stereological methods (6) at the light microscopical level. The sampling regime of the present study was the 'systematic uniform random sampling method', which was performed in all steps of the study such as the animals, blocks, sections, fields of view and so on. The numbers of animals, blocks, sections and fields of view were determined by a pilot study that was performed prior to the morphometrical analysis. Volume fractions of several cortical features such as glomerulus, renal corpuscle, interstitium, proximal and distal tubuli were measured by the point counting method using a 1 cm square grid, 10 μm on the tissue.

Statistics

Means and standard errors were calculated for each group and data were analysed using Student's t-test. The conventional level of 5% was taken as the level of significance.

Results

Morphometry

Six animals died during the experimental process. Thus 12 animals were used for morphometric analysis. While the control group contained 5 animals, the experimental diabetes and the insulin therapy groups consisted of 4 and 3 animals respectively.

Mean kidney weights and volumes are given in Table 1. There was a significant ($p < 0.05$) increase in the mean kidney weight of the experimental diabetes group (9.09 ± 0.66 g) when compared to the control group (7.57 ± 0.31 g). Mean kidney weight was 8.12 ± 0.12 g in the insulin therapy group, which did not show significant

Table 1. The comparison of the mean kidney weights and volumes between the groups.

	Control Group (n=5)	Experimental Diabetes Group (n=4)	Insulin Therapy Group (n=3)
Mean Kidney Weight (g)	7.57 ± 0.31* (CV = 15.4)	9.09 ± 0.66* (CV = 1.05)	8.12 ± 0.12 CV = 2.9)
Mean Kidney Volume (mm ³)	7.02 ± 0.38* (CV = 11.9)	9.02 ± 0.51* (CV = 11.3)	7.13 ± 0.13* (CV = 3.2)

Results are mean ± standard error

* p < 0.05 (Student's t-test)

CV: coefficient of variation

difference from the control and experimental diabetes groups (Table 1).

Mean kidney volume measurements and their statistical analysis revealed that the experimental diabetes group rabbit mean kidney volume (9.02±0.51 mm³) increased significantly (p<0.05) when compared to the control group (7.02±0.38 mm³). On the other hand, it decreased in the insulin therapy group (7.13±0.13 mm³), which was again significantly (p<0.05) different from the experimental diabetes group (Table 1).

Table 2 shows the results of morphometric evaluations of the groups at the light microscopical level. While the volume fractions of renal corpuscle to cortex, distal tubulus to cortex, interstitium to cortex and

interstitial capillaries to cortex were not significantly different between groups, the volume fractions of glomerulus to cortex and proximal tubulus to cortex were significantly (p<0.05) different between the groups. The volume fraction of glomerulus to cortex was significantly higher (0.984±0.003) in the experimental diabetes group than in the control group (0.877±0.033). On the other hand, there was no significant difference between the control and the insulin therapy groups in terms of this feature, indicating the reversing effect of insulin on diabetes. Similarly, the volume fraction of proximal tubulus to cortex was significantly higher in the experimental diabetes group (0.420±0.020) than in the control group (0.347±0.024) and the insulin therapy group (0.378±0.010) (Table 2).

Table 2. The comparison of the volume fractions of several renal cortical features between the groups.

	Control Group (n=5)	Experimental Diabetes Group (n=4)	Insulin Therapy Group (n=3)
Renal Corpuscle / Cortex	0.058 ± 0.013 (CV = 27.6)	0.076 ± 0.008 (CV = 12.4)	0.094 ± 0.042 (CV = 32.1)
Glomerul / Renal Corpuscle	0.877 ± 0.033* (CV = 5.4)	0.984 ± 0.003* (CV = 1.3)	0.945 ± 0.026 (CV = 4.8)
Distal Tubulus / Cortex	0.122 ± 0.024 (CV = 23.7)	0.127 ± 0.007 (CV = 11.5)	0.113 ± 0.008 (CV = 8.9)
Proximal Tubulus / Cortex	0.347 ± 0.024* (CV = 9.6)	0.420 ± 0.020* (CV = 8.3)	0.378 ± 0.010 (CV = 4.5)
Interstitium / Cortex	0.462 ± 0.040 (CV = 12.4)	0.370 ± 0.027 (CV = 10.2)	0.427 ± 0.032 (CV = 7.3)
Interstitial Capillaries / Cortex	0.012 ± 0.002 (CV = 21.3)	0.013 ± 0.004 (CV = 29.1)	0.031 ± 0.013 (CV = 30.8)

Results are mean ± standard error

*p < 0.05 (Student's t-test)

CV: coefficient of variation

Histology and Ultrastructure

Qualitative observations of the control group's renal cortical features revealed glomerular capillaries containing endothelial cells, podocytes and mesangial cells. Glomerulus was located regularly in the renal corpuscle leaving a Bowman's space of normal volume at the light microscopical level (Figure 1A). The lower magnification of this group showed the cells of macula densa in the vessel pole of the renal corpuscle along with proximal and distal tubuli and an artery in the surrounding tissue (Figure 1B).

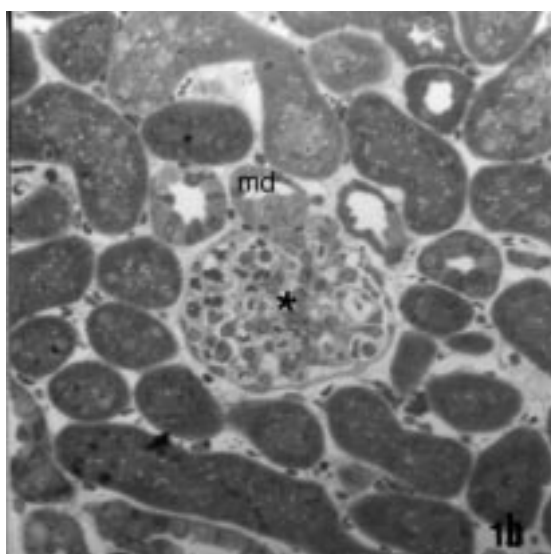
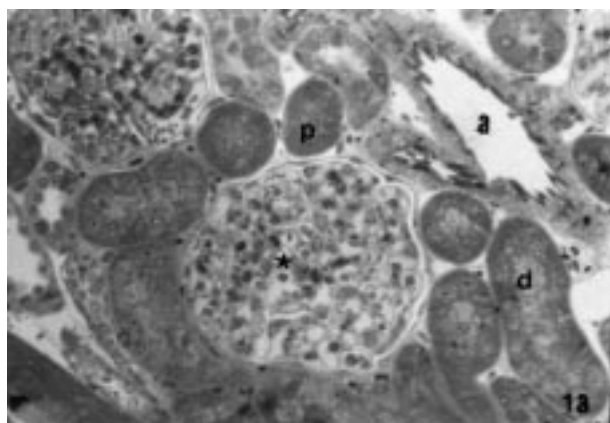


Figure 1. A: Shows the control group renal cortical features including renal corpuscle (★), proximal (p) and distal (d) tubuli. Arteriole (A). X 400. Toluidin blue.
 B: A lower magnification field of view of a renal corpuscle (★), along with a macula densa (md). X 200. Toluidin blue.

The ultrastructural observations of the control group's renal cortex demonstrated glomeruli containing regular endothelial fenestrae, homogenous basement membrane and podocytes located on the glomerular basement membrane with their pedicles (Figure 2). Control group proximal tubular cells had intracytoplasmic foldings, mitochondria and apical microvilli, which are the ultrastructural characteristics of a proximal tubular cell (Figure 3).

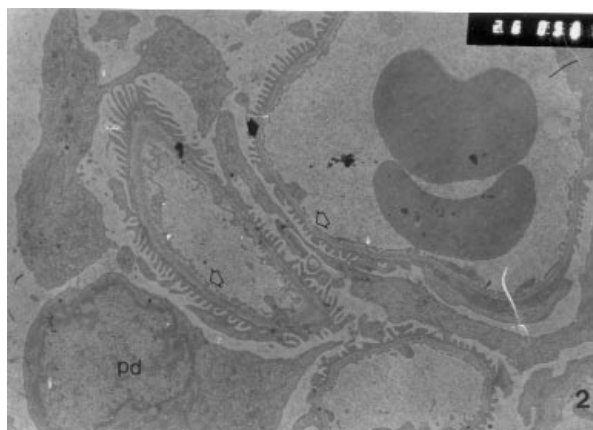


Figure 2. Demonstrates the ultrastructural appearance of the control group glomerular features. Podocytes (pd), basement membrane (black arrow), endothelial cell fenestrae (white arrow). X 7500.

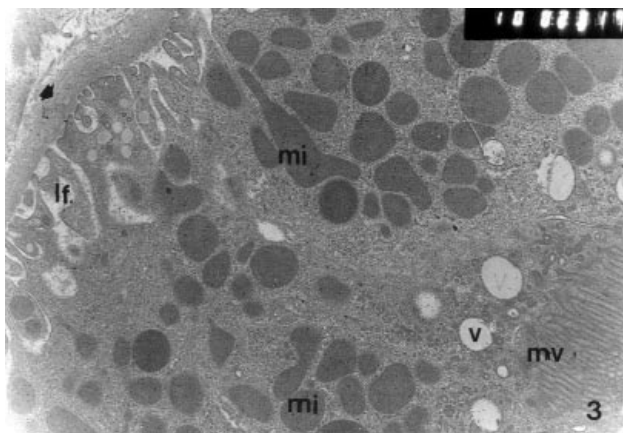


Figure 3. Ultrastructure of the control group proximal tubular features contain basement membrane (black arrow), intracytoplasmic foldings (lf), mitochondria (mi), microvilli (mv), vesicles (v). X 30 000.

The experimental diabetes group's renal cortical histology demonstrated glomerular capillaries entirely filling the renal corpuscle along with mesangial cell proliferation and hypertrophy. The tubular volume, especially the proximal one, seemed increased, resulting

in a decrease in the interstitial tissue (Figure 4). Ultrastructural examination of this group revealed glomerular capillaries containing irregularly arranged basement membrane, and podocytes in their normal structure. Abundant mesangial cells were also present in the glomerulus (Figure 5). On the other hand, proximal tubular cells had apical microvilli and intracytoplasmic foldings similar to those seen in the control group. However, there was a distinct cytoplasmic loss and an increased number of lysosomal structures in these cells (Figure 6).

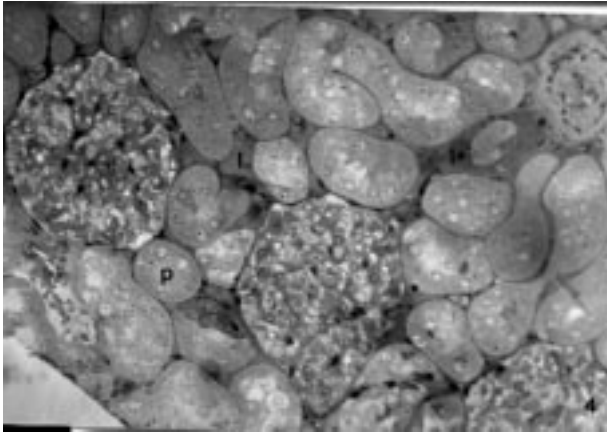


Figure 4. The experimental diabetes group's renal cortical features reveal glomerular mesangial cell hypertrophy and proliferation. In addition, an increase in especially proximal tubular (p) volume accompanied by a decrease in interstitial (I) amount is also evident. X 400, Toluidin blue.

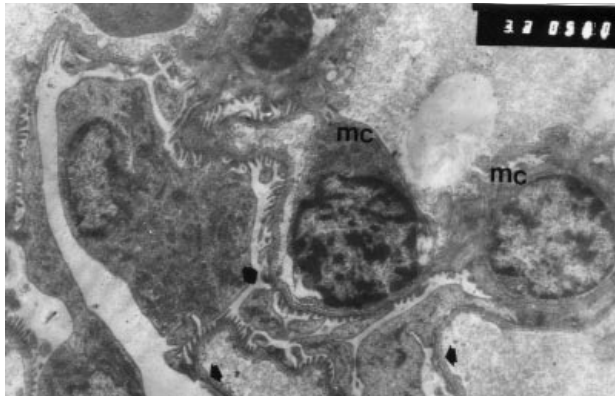


Figure 5. The glomerular ultrastructure of the experimental diabetes group shows irregularly arranged basement membrane (◆) and mesangial cell (mc) proliferation (>). X 10 000.

Both the glomerular and tubular features in the insulin therapy group were similar to those in the control

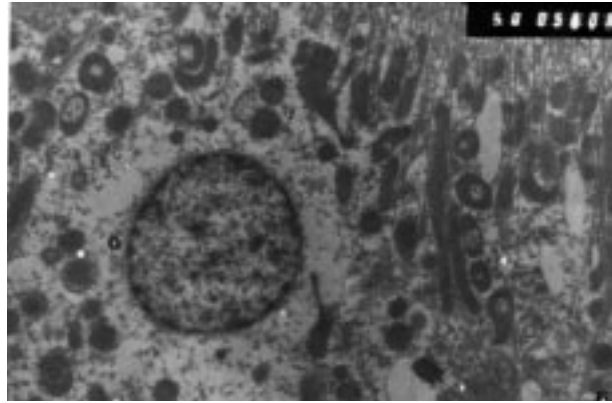


Figure 6. Proximal tubular cell features belonging to the diabetic group reveal a distinct cytoplasmic loss (>) and increased lysosomal structures (ly). X 15 000.

group, despite an increase in capillaries in the interstitium (Figure 7). Ultrastructural examination of this group's renal cortex supported the light microscopical findings that the glomerular capillaries, their basement membrane and cellular characteristics were similar in structure to the control group's features (Figure 8). In addition, tubular features was also in their normal structure as revealed by electron microscopy (Figure 9).

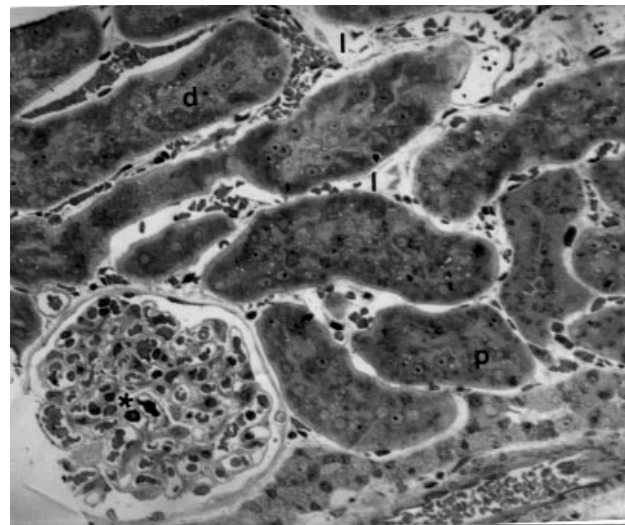


Figure 7. The renal cortex contains features in the insulin therapy group similar to those seen in the control group such as renal corpuscle (★) and tubular structures (p;d) in their normal appearance. On the other hand, interstitial tissue seems to be reversed to its normal volume; however, capillaries (cap) are increased in number. X 400, Toluidin blue.

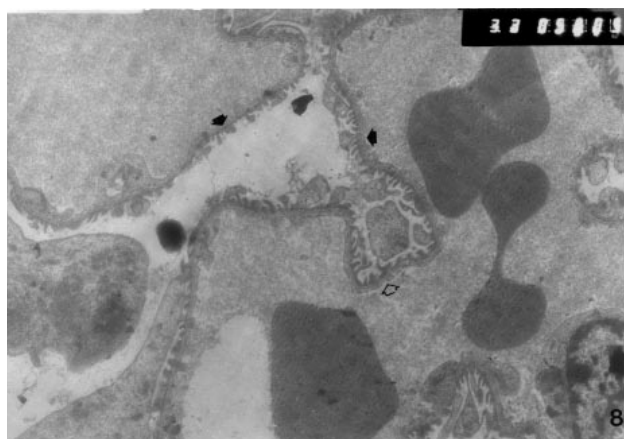


Figure 8. Glomerular ultrastructure seems to be reversed by insulin treatment. Basement membrane (●), endothelial fenestrae (⇨). X 10 000.

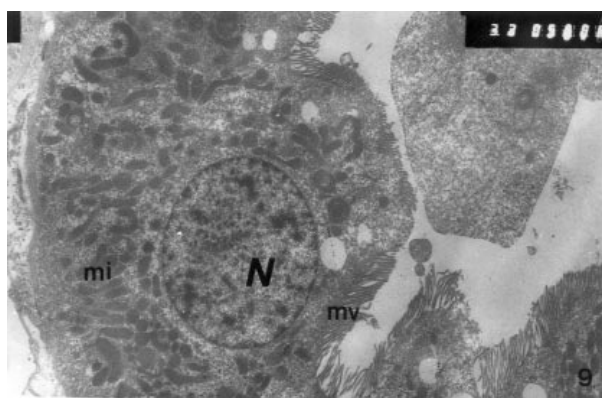


Figure 9. Insulin therapy group's proximal tubular features are also similar to the control group's features. Nucleus (N), mitochondria (mi), microvilli (mv). X 10 000.

Discussion

The most common features of vascular lesions in diabetic patients are renal glomerular degeneration. Previous studies on the long-term effects of diabetes in experimental animals showed that the effects were not only on the peripheral capillaries but they also induced the glomerular nephropathy along with tubular and interstitial abnormalities (4,7). Glomerular basement membrane thickening, an indicator of diabetic microangiopathy, may be seen in patients with a 2 year history of diabetes, whereas it increases by 30% after 5 years of diabetes (8,9). The short-term effects of diabetes have been suggested to be the increased number of glomerular mesangial cells and interstitial alterations (3) other than the increased basement membrane

thickness, which are the indicators of the long-term effects of diabetes (10,11,12).

It is well established that alloxan causes irreversible degenerations in beta cells of the endocrine pancreas. Therefore, the present study investigated the effects of diabetes exogenously induced by alloxan, and also the effects of insulin treatment in the renal morphology of rabbits. Six animals died during the experimental process and thus the experiment was completed with 12 animals. The short-term morphological effects of experimental diabetes and the insulin treatment were determined qualitatively and quantitatively. The insulin therapy was performed to determine whether the morphological degeneration caused by diabetes could be reversed.

Morphometric analysis of rabbit renal cortical features revealed significant effects of experimental diabetes which seemed to be prevented by insulin therapy. The volume fraction of renal corpuscle occupied by glomerular capillaries was significantly higher in the experimental diabetes group and became normal following daily intramuscular insulin injections. A similar finding was also observed in the volume fraction of the renal cortex occupied by proximal tubulus, where it was found to be significantly higher in the experimental diabetes group than in the control and insulin therapy groups. These findings may indicate proliferation and hypertrophy in the glomerular and tubular regions of the renal cortex caused by experimental diabetes and may also indicate the reversing effect of the insulin therapy. Similar suggestions have been made by several previous studies, namely that short-term diabetes might induce proliferation or hypertrophy in renal cortical structures especially in the glomerular mesangium (3,4,10,13). The volume fraction results of the renal cortical features indicating hypertrophy and proliferation were supported by the mean kidney volume measurements, which significantly increased in the experimental diabetes group but dropped to normal levels in the insulin therapy group. Similar findings on kidney weight and volume following experimental diabetes have also been suggested by previous studies: they indicated an increased kidney weight and volume caused by experimental diabetes (14,15). These increased kidney weight and volume values in diabetes could be described only by increased mesangial and tubular cell hypertrophy.

It has been shown that the absolute glomerular and mesangial volumes increased following short-term

experimental diabetes, whereas the glomerular basement membrane thickened only after long-term experimental diabetes (4). Previous qualitative and quantitative studies also indicated an increased glomerular basement membrane thickness 24-36 months after experimental diabetes (16,17). Therefore, the present study eliminated the glomerular basement membrane thickness measurements at the electron microscopical level since the aim was to determine the short-term effects of experimental diabetes.

Those morphometric findings were also supported by qualitative observations at the light and electron microscopical levels. Light microscopical examination of the renal cortex revealed an increased number of mesangial cell nuclei indicating proliferation in the glomerular capillaries. Therefore, the glomerular capillaries filled the urinary space of the renal corpuscle, which was also consistent with the increased volume fraction of renal corpuscle occupied by glomerular capillaries revealed by morphometry. Light microscopical examination of the insulin therapy group's renal cortical morphology demonstrated glomerular features similar to those seen in the control group, which was consistent with the quantitative evaluations that the glomerular volume fraction value dropped to its normal level following 2 months of daily insulin treatment.

Similar to the increased volume fraction of glomerulus, the proximal tubular volume fraction was also significantly higher in the experimental diabetes group than in the control and insulin therapy group as

determined by morphometry. These quantitative tubular alterations were also supported by qualitative observations that tubular cells became larger and degenerated following two months of experimental diabetes narrowing the interstitial area, which was also suggested by previous studies (13). Although the volume fraction of cortex occupied by interstitium was not significantly different between the control and experimental diabetes groups, there was a tendency for this feature to increase following the diabetes period, where it dropped to the control levels in the insulin therapy group. These degenerative alterations in the proximal tubular cells consisted of increased cytoplasmic volume accompanied by increased lysosomal number in the basal region as observed at the electron microscopical level.

In conclusion, the qualitative findings of the present study were almost consistent with the quantitative findings and also with the mean kidney weight and volume measurements. It could be suggested that while short-term experimental diabetes caused glomerular and tubular alterations in the rabbit renal cortex, those alterations might be prevented by daily insulin treatment.

Correspondence author:

H. Eray BULUT

Department of Histology-Embryology,

Faculty of Medicine, Cumhuriyet University,

58140 Sivas - TURKEY

References

1. Agodoa L.; Eknoyan G.; Ingelfinger J.; Keane W.; Mauer M.; Mitch W.; Striker G.; Wilcox C. Assessment of structure and function in progressive renal disease. *Kidney Int. (suppl.)*, 63: 144 - 150, 1997.
2. Rasch R. Prevention of diabetic glomerulopathy in streptozotocin diabetic rats by insulin treatment. The mesangial regions. *Diabetologia*, 17: 243 - 248, 1979a.
3. Seyer-Hansen K.; Hansen J.; Gundersen H.J.G. Renal hypertrophy in experimental diabetes. *Diabetologia*, 18: 501 - 505, 1980.
4. Hirose K.; Østerby R.; Nozawa M.; Gundersen H.J.G. Development of glomerular lesions in experimental long-term diabetes in the rat. *Kidney Int.*, 21: 689 - 695, 1982.
5. Rasch R. Prevention of diabetic glomerulopathy in streptozotocin diabetic rats by insulin treatment. Glomerular basement membrane thickness. *Diabetologia*, 16: 319 - 324, 1979b.
6. Weibel E.R. *Stereological Methods*. Vol. 1. *Practical Methods for Biological Morphometry*. Academic Press, London, 415 pages, 1979.
7. Gambaro G.; Venturini A.P.; Noonan D.M.; Fries W.; Re G.; Garbisa S.; Milanesi C. Treatment with glycosaminoglycan formulation ameliorates experimental diabetic nephropathy. *Kidney Int.*, 46: 797 - 806, 1994.
8. Østerby R. Early phases in the development of diabetic glomerulopathy. A quantitative electron microscopic study. *Acta Med. Scand. (Suppl.)* 574: 1 - 82, 1975.
9. Østerby R.; Gundersen H.J.G. Glomerular basement membrane thickening in streptozotocin diabetic rats despite treatment with an aldose reductase inhibitor. *J Diabet Complications*, 3: 149 - 153, 1989.

10. Østerby R.; Gundersen H.J.G. The glomerular basement membrane in early diabetes. *Front. Matrix Biol.*, 7: 72 - 77, 1979.
11. Ina K.; Kitamura H.; Nakamura M.M.; Ono j.; Takaki R. Ultrastructure and immunohistochemical similarities between glomerular arteriolar and mesangial lesions in experimental diabetes. *Diabetes Res. Clin. Pract.*, 16: 27 - 35, 1992.
12. Hajinazarian M.; Cosio F.G.; Nahman N.S. Jr; Mahan J.O. Angiotensin-converting enzyme inhibition partially prevents diabetic organomegaly. *Am. J Kidney Dis.*, 23: 105 - 117, 1994.
13. Onarlioğlu B.; Gürsoy E. Renal ultrastructure in experimental diabetes mellitus Doga - Tr. *J. Med. Sci.*, 14: 409 - 415, 1990.
14. Shankland S.J.; Scholey C.W.; Ly H.; Thai K. Expression of transforming growth factor - beta 1 during diabetic renal hypertrophy. *Kidney Int.*, 46: 434 - 442, 1994.
15. Schaefer L.; Schaefer R.M.; Ling H.; Teschner M.; Heidland A. Renal proteinases and kidney hypertrophy in experimental diabetes. *Diabetologia*, 37: 567 - 571, 1994.
16. Makino H.; Yamasaki Y.; Hironaka K.; Ota S. Glomerular extracellular matrices in rat diabetic glomerulopathy by scanning electron microscopy. *Virchows Arch. B Cell Pathol.*, 62: 19 - 24, 1992.
17. Berg T.J.; Bangstad H.J.; Torjesen P.A.; Østerby R.; Bucala R.; Hanssen K.F. Advanced glycation end-products in serum predict changes in the kidney morphology of patients with insulin-dependent diabetes mellitus. *Metabolism*, 46: 661 - 665, 1997.