

1-1-2001

Lateral Periodontal Cyst

IŞIL SAYGUN

ATILLA ÖZDEMİR

MÜKERREM SAFALI

Follow this and additional works at: <https://journals.tubitak.gov.tr/medical>



Part of the [Medical Sciences Commons](#)

Recommended Citation

SAYGUN, IŞIL; ÖZDEMİR, ATILLA; and SAFALI, MÜKERREM (2001) "Lateral Periodontal Cyst," *Turkish Journal of Medical Sciences*: Vol. 31: No. 4, Article 15. Available at: <https://journals.tubitak.gov.tr/medical/vol31/iss4/15>

This Article is brought to you for free and open access by TÜBİTAK Academic Journals. It has been accepted for inclusion in Turkish Journal of Medical Sciences by an authorized editor of TÜBİTAK Academic Journals. For more information, please contact academic.publications@tubitak.gov.tr.

Işıl SAYGUN¹
Atilla ÖZDEMİR¹
Mükerrem SAFALI²

Lateral Periodontal Cyst

¹Department of Periodontology, Dental Sciences Center, ²Department of Pathology Gülhane Military Medical Academy, Ankara - TURKEY

Received: March 08, 2000

Key Words: Periodontal cyst

The lateral periodontal cyst is an uncommon but well-recognized type of developmental odontogenic cyst. This lesion is more common in adults (1,2). Cohen et al. (2) reported an equal sex distribution, but other studies have reported a male preponderance (3,4). Differential diagnosis between lateral periodontal cyst and collateral keratocyst must be done by evaluating the clinical and histological data. It is also difficult to distinguish lateral periodontal cyst from gingival cyst in adults since they have many similarities. Radiolucent odontogenic tumors and benign mesenchymal tumors should also to be considered for differential diagnosis (2).

The pathogenesis of the lateral periodontal cyst is not fully known. There seem to be three possibilities: reduced enamel epithelium, remnants of dental lamina and cell rests of Malassez (3).

The most frequently reported location of a lateral periodontal cyst is the mandibular premolar area, followed by the anterior region of the maxilla (3,5). Often the lateral periodontal cyst does not present distinctive clinical symptoms; the associated teeth were vital, unless secondarily infected (5). Since pain or other clinical symptoms have seldom been reported, the lesion is often discovered on routine radiographic examination. Radiographs of the lateral periodontal cyst show a well-circumscribed round or ovoid radiolucent area, usually with a sclerotic margin. Most of them are less than 1cm in diameter and are located on the cervical margin of the tooth (2,6).

Histologically, the lateral periodontal cyst is a distinct type of developmental cyst characterized by a thin, non-keratinized epithelium usually 1 to 5 cell layers thick, which resembles the reduced enamel epithelium. The

epithelial lining exhibits focal thickenings or plaques, in which clear glycogen-containing epithelial cells have often been found. The connective tissue subjacent to the epithelium exhibits a zone of hyalinization (3,4).

The purpose of this paper is to report a case of a lateral periodontal cyst and to describe its clinical, radiographic and histologic features. Also, emphasis is placed on distinguishing the lateral periodontal cyst from other laterally positioned cysts.

Case report

A 55-year-old woman with an asymptomatic, nodular swelling located on the attached gingiva between the mandibular right first and second premolars was referred to the Department of Periodontology in Gülhane Military Medical Academy. The duration of this lesion was one year. She had noticed that the swelling was growing slowly.

Clinical examination revealed a round swelling, almost 1 cm in diameter, fluctuant to palpation, and located on the attached gingiva between the mandibular right premolars (Figure 1). The lesion was asymptomatic. The mandibular right first and second premolars were found to be vital to electric pulp testing. A radiograph of the site was taken, and it showed a round radiolucency with a radiopaque margin located between the roots of the first and second premolars (Figure 2).

A clinical diagnosis of a lateral periodontal cyst of developmental origin was made. Local anesthesia was used and full-thickness mucoperiosteal flaps were elevated. The lesion was completely removed using a surgical curette.

Histologically, the lesion was unicystic and the lining epithelium consisted of non-keratinized squamous epithelium, interspread with a few glycogen-rich clear cells. Separation of the epithelium from the connective tissue was observed. This is an artifact but indicates a weakness in the epithelial connective tissue interface. The presence of mild chronic inflammation observed in the connective tissue which was far from the epithelial side is probably a result of secondary involvement from the neighboring inflamed gingiva (Figure 3). The histological findings supported the diagnosis of lateral periodontal cyst of developmental origin.

Lateral periodontal cyst is a uncommon lesion of the oral cavity. It is a intraosseous (central) cyst, associated with the root of a vital tooth. The lateral periodontal cyst occurs particularly between the 5th through 7th decades, with an average of 54 years (3,7). Clinically it presents no signs or symptoms but occasionally a small swelling of the gingiva or alveolar mucosa may be seen (6,8). In our patient the swelling of the gingiva was 1 cm in diameter.

Differential diagnosis is of paramount importance, since misdiagnosis may lead to extraction of teeth or unnecessary periodontal treatment (5). In some instances, odontogenic keratocysts are grouped with the lateral periodontal cyst. It is important that the clinician be aware that odontogenic keratocysts frequently occupy a lateral periodontal position. Keratocysts must be differentiated from the lateral

periodontal cysts because of their aggressiveness and high potential for recurrence following surgical removal. In addition, odontogenic keratocysts may be associated with the basal cell nevus syndrome. In other instances, laterally occurring cysts may be associated with an accessory lateral canal in a pulpally involved or nonvital tooth (2).

The histopathological features of the lateral periodontal cysts have been extensively studied by many researchers (3,5,6). The epithelium consisted of 3 to 6 cell layers thick, non-keratinized squamous epithelial cells and occasionally interspread glycogen-rich clear cells. The histological characteristics of the present case are similar to those reported previously.

Other histological features of the lateral periodontal cyst include the absence of inflammation in the connective tissue, the artifactual separation of the lining epithelium from the underlying connective tissue, and the hyalinization of connective tissue immediately beneath the epithelium (2,3,4). Our case showed a typical epithelial appearance of lateral periodontal cyst, and the presence of mild chronic inflammation observed in the connective tissue is probably a result of secondary involvement from the neighboring inflamed gingiva. Angelopoulou et al. (5) also reported the presence of mild chronic inflammation in the connective tissue, but Cohen et al. (2) observed that the connective tissue in all cases was remarkably free of inflammation. Similar to previous

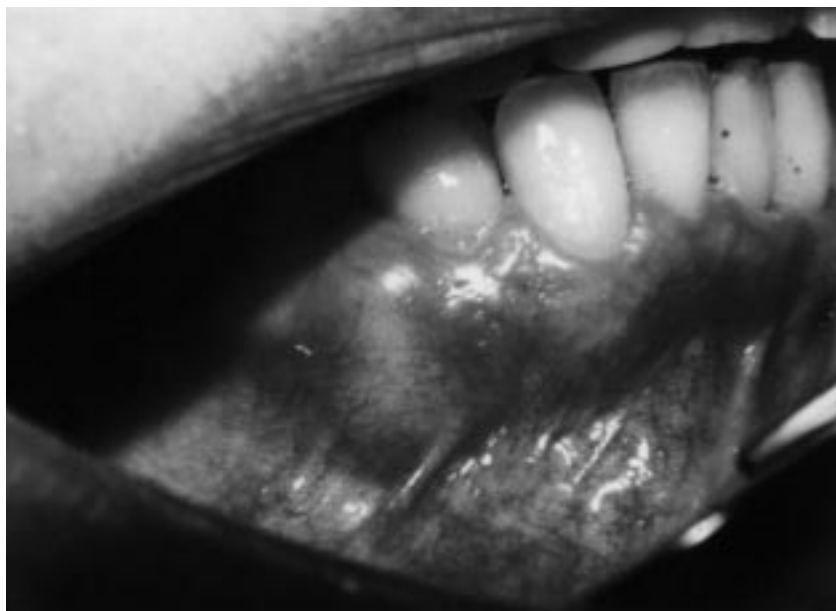

Figure 1. Clinical appearance of the lesion.

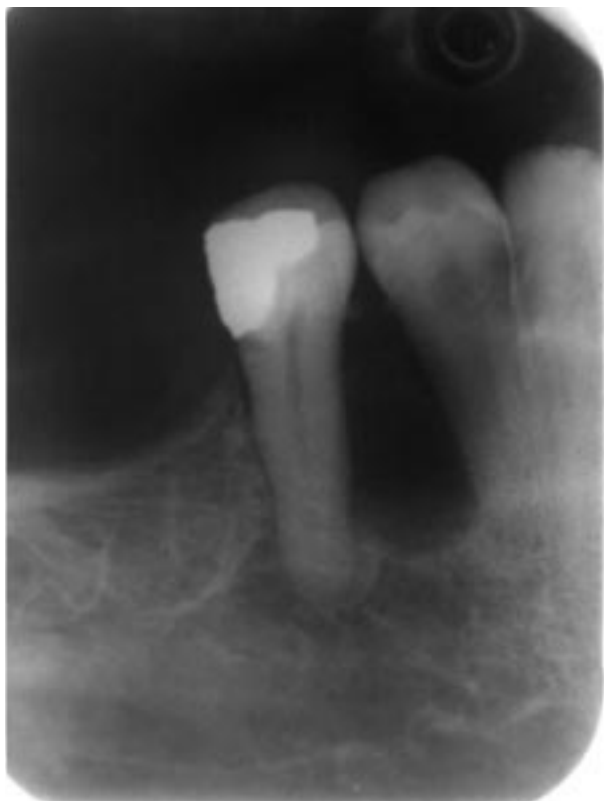

Figure 2. Radiographic appearance of the lesion.

reports separation of the epithelium from the connective tissue was present in our patient.

Our study has shown that glycogen is by no means consistently shown in the clear cells and is not confined to them. Altini and Shear (3) suggested that epithelial plaques did not comprise clear cells de novo but start rather as fusiform cells with scanty cytoplasm arising from localized proliferation of basal cells.

The pathogenesis of the lateral periodontal cyst is not fully known. Angelopoulou and Angelopoulos (5) present three possible origins:

1. The reduced enamel epithelium of an erupting tooth; there is a morphologic similarity between the cyst lining and reduced enamel epithelium.
2. Rest of the dental lamina.
3. Rests of Malassez. These structures are characteristically present in the periodontal ligament.

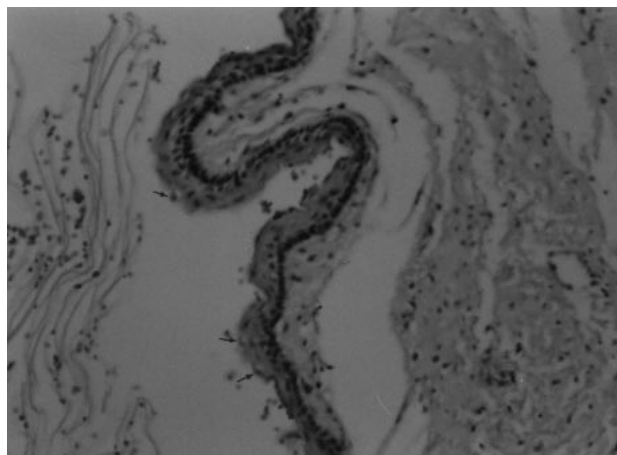


Figure 3. Histological appearance of the lesion, occasional clear cells in basal layer (arrow) (Hematoxylin and Eosin; original magnification x 200).

Another concept of the pathogenesis of lateral periodontal cyst is the possible origin as a primordial cyst of a supernumerary tooth germ. This possibility is supported by the high incidence of supernumerary teeth in the mandibular bicuspid region which corresponds well with the predilection of the lateral periodontal cyst in the same area (1).

As this case has shown, the clinical impression and radiographic picture are not distinctive enough to be used as the sole criterion for rendering a diagnosis of lateral periodontal cyst. Cysts occurring in a lateral periodontal location may have a variety of etiologies, and final diagnosis of these lesions should be made with a histopathologic assessment.

Correspondence author:

Işıl SAYGUN

60. Sokok 16/3

Emek - ANKARA

References

1. Shafer WG, Hine MK, Levy BM. A Textbook of oral pathology. 4th ed. Philadelphia: W.B. Saunders Company, 265-268, 1983.
2. Cohen DA, Neville BW, Damm DD and White DK. The lateral periodontal cyst. A report of 37 Cases. J Periodontol 54, 230-234, 1983.
3. Altini M, Shear M. The lateral periodontal cyst: an update. J Oral Pathol Med 21: 245-250, 1992.
4. Rasmusson LG, Magnusson BC, Borrmann H. The lateral periodontal cyst. A histopathological and radiographic study of 32 cases. British Journal of Oral and Maxillofacial Surgery 29:54-57, 1991.
5. Angeloupoulou E, Angeloupoulos AP. Lateral periodontal cyst. Review of the literature and report of cases. J Periodontol 61: 126-131, 1990.
6. Carter LC, Carney YL, Perez-Pudlewski. Lateral periodontal cyst. Multifactorial analysis of a previously unreported series. Oral Surg Oral Med Oral Pathol 81: 210-6, 1996.
7. Cawson RA, Odell EW. Essentials of oral pathology and oral medicine 6th ed. Churchill Livingstone, Edinburgh, London, New York, Philadelphia, Sydney, Toronto, 110, 1998.
8. Lehrhaupt NB, Brownstein CN, Deasy MJ. Osseous repair of a lateral periodontal cyst. J Periodontol 68: 608-611, 1997.
9. Meltzer JA. Lateral periodontal cyst: Report of a case with 1-year reentry. Int J Periodontics Restorative Dent 19:299-303, 1999.