

1-1-2001

A Rare Cause of Upper Gastrointestinal System Bleeding: Pancreatic Endocrine Neoplasm

ORAL SAYGUN

FATİH MEHMET AVŞAR

İ. HAKAN ÖZEL

SÜLEYMAN HENGİRMEN

LEVENT ALBAYRAK

See next page for additional authors

Follow this and additional works at: <https://journals.tubitak.gov.tr/medical>

 Part of the [Medical Sciences Commons](#)

Recommended Citation

SAYGUN, ORAL; AVŞAR, FATİH MEHMET; ÖZEL, İ. HAKAN; HENGİRMEN, SÜLEYMAN; ALBAYRAK, LEVENT; and HÜCÜMENOĞLU, SEMA (2001) "A Rare Cause of Upper Gastrointestinal System Bleeding: Pancreatic Endocrine Neoplasm," *Turkish Journal of Medical Sciences*: Vol. 31: No. 4, Article 14. Available at: <https://journals.tubitak.gov.tr/medical/vol31/iss4/14>

This Article is brought to you for free and open access by TÜBİTAK Academic Journals. It has been accepted for inclusion in Turkish Journal of Medical Sciences by an authorized editor of TÜBİTAK Academic Journals. For more information, please contact academic.publications@tubitak.gov.tr.

A Rare Cause of Upper Gastrointestinal System Bleeding: Pancreatic Endocrine Neoplasm

Authors

ORAL SAYGUN, FATİH MEHMET AVŞAR, İ. HAKAN ÖZEL, SÜLEYMAN HENGİRMEN, LEVENT ALBAYRAK,
and SEMA HÜCÜMENOĞLU

Oral SAYGUN¹
Fatih Mehmet AVŞAR¹
İ. Hakan ÖZEL¹
Süleyman HENGİRMEN¹
Levent ALBAYRAK²
Sema HÜCÜMENOĞLU³

A Rare Cause of Upper Gastrointestinal System Bleeding: Pancreatic Endocrine Neoplasm

Departments of 1. General Surgery¹ and Pathology², Ankara Numune Education & Research Hospital, Ankara-Turkey

³Department of Pathology, Ankara SSK Education & Research Hospital, Ankara-Turkey

Received: January 01, 2001

Key Words: Upper gastrointestinal system bleeding, pancreatic endocrine neoplasm, gastrinoma, Whipple procedure

Case

A 51-year-old male patient was admitted to the emergency room with the complaint of vomiting blood. There was no history of peptic ulcer and anticoagulant therapy or therapy with drugs irritating to the mucosa. He defined an abdominal pain that had spread to the back during the previous week. On physical examination he was pale, blood pressure was 90/50 mmHg, pulse rate was 100/min, and respiratory rate was 25/min. He was conscious and orientation was impaired slightly. Hematemesis and melena were determined by nasogastric intubation and rectal examination.

Laboratory findings were as follows: Hemoglobin concentration = 7.8g/dl, RBC = 2.2 million/ml, WBC = 6.750/ml, thrombocyte concentration = 222.000/ml., serum glucose = 110 mg/dl., BUN = 63 mg/ml.

In endoscopic examination, a large bleeding bulbar ulceration suspected of malignancy was detected and sclerotherapy was performed but it was not possible to perform a biopsy because of massive bleeding. Proper medical treatment was started immediately but 8 hours after endoscopic sclerotherapy, the bleeding occurred again. Surgical intervention was decided on, and the patient underwent urgent surgery after a short preparation. A mid-line incision was made. During the mobilization of the duodenum a mass 5 cm in diameter was noticed on the head of pancreas. In addition, multiple lymph nodes were present around the duodenum. It was

difficult to determine whether this mass lesion was due to an ulcer penetration or a primary tumor. There was no evidence of malignancy in the excised lymph nodes on frozen section examination. It was decided to perform the Whipple procedure because of the high malignancy risk of pancreatic masses, in spite of the inappropriate hemodynamic condition.

The patient was removed from mechanical ventilation support on the 3rd postoperative day, transported from the intensive care unit to the ward on the 18th postoperative day and discharged from the hospital on the 26th postoperative day. The histopathological diagnosis was reported to be pancreatic endocrine neoplasm, chronic pancreatitis, and reactive lymph nodes.

Figure 1 shows the pancreatic endocrine neoplasm in the structure of chronic pancreatitis.

Gastrin production by the neoplastic cells was shown by immunohistochemistry. The immunoperoxidase technique was performed on the paraffin embedded tumor tissue. Tumor cells exhibited positive immunoreactivity with gastrin (Figures 2, 3).

Upper gastrointestinal system bleeding occurs due to various causes and may be recognized by symptoms such as hematemesis, melena and shock (1-3). Generally, frequent causes of upper gastrointestinal system bleeding may be considered during primary evaluation. However, definite diagnosis requires endoscopic examination (4). In differential diagnosis, Mallory-Weiss syndrome, Deulafoy

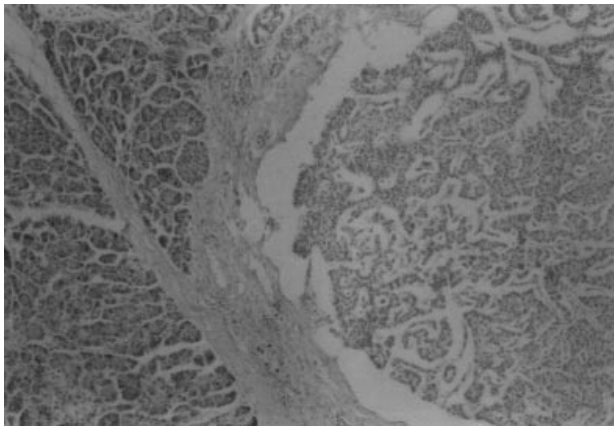


Figure 1. Pancreatic endocrine neoplasm in the center of the structure of chronic pancreatitis. (HE x100).

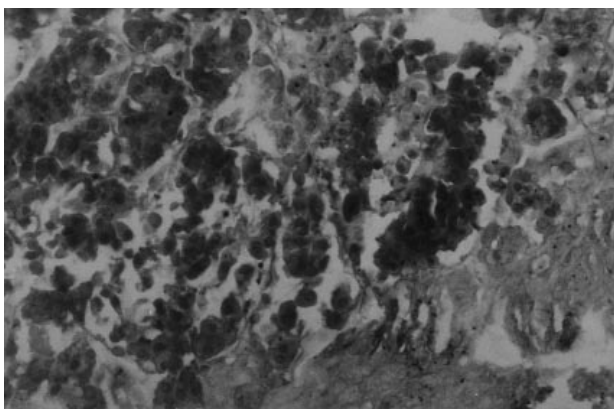


Figure 2. Microscopic view. Gastrinoma stained for gastrin and a group of neoplastic cells show strong positivity. (Gastrin, immunoperoxidase x400).

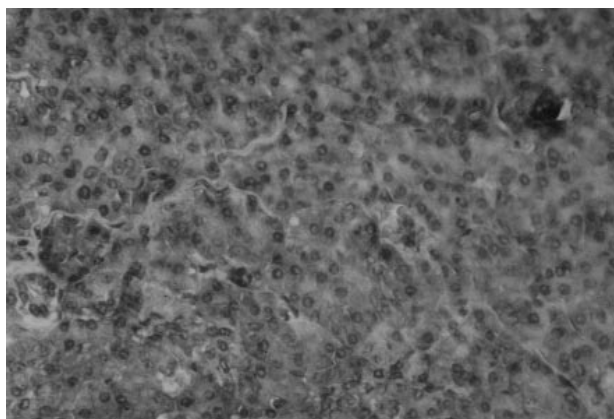


Figure 3. High power view of gastrin staining of pancreatic gastrinoma. There is scattered positivity. A neoplastic cell showing strong gastrin positivity is seen in the upper right corner. (Gastrin, immunoperoxidase x400).

syndrome, vascular malformations, hemobilia, aorto-enteric fistulas, penetration of pancreas pseudocysts, and invasion of secondary tumors should be considered (2, 3). Pancreas tumors can be divided into the two basic groups of endocrine and exocrine tumors. Endocrine tumors are rarely seen (one per million), and the majority of them are functional tumors originating from alpha, beta and delta type islet cells (5, 6). Many of them are benign and recognized by clinical features that are specific to their origin. Also, some of them are diagnosed accidentally during investigations for completely different reasons (6).

It is not usual that a pancreas tumor causes upper gastrointestinal system bleeding or appears with an ulceration other than gastrinoma. In our patient, the cause of bleeding was thought to be the invasion and ulceration of a pancreas tumor or the cause of the mass was thought to be penetration of the gastric ulcer. However, histopathological examination showed a lesion 3 mm in diameter of pancreas endocrine neoplasm in the structure of chronic pancreatitis. Later, immunohistochemical analysis proved that the lesion was a gastrinoma. There was no sign or history of gastrinoma, and tumor was perceptible primarily by bleeding. For this reason, the serum gastrin level was not measured.

An important presenting sign that should suggest ZES is prominent gastric body folds, which were noted on endoscopy in 94% of patients; however, a correct diagnosis of ZES was made by the referring physician initially in only 3% of the patients (7).

The Whipple procedure is superior to other procedures performed for pancreatic malignant lesions, and may be preferable for disease located primarily in the head of the gland (6, 8). A marked reduction in the morbidity and mortality rates after the Whipple procedure has been reported and it has been used to resect pancreatic endocrine neoplasms successfully (9). Surgery represents the only way to cure these lesions (10).

This patient was evaluated as having upper gastrointestinal system bleeding and we decided to operate for this reason. In the course of the operation we could not be sure of the origin of the mass, although the frozen section examination result was negative for malignancy. We accepted the risk of the Whipple procedure in such inappropriate metabolic and

hemodynamic condition. Determination of endocrine neoplasm at postoperative histopathologic examination verified that the early intervention was accurate because there was no local lymphatic invasion or distant organ metastases.

In conclusion, when patients with upper gastrointestinal system bleeding are evaluated the possibility of a pancreatic tumor must be considered, and

if such a condition is observed peroperatively, we believe more extensive surgical procedure, must be considered.

Correspondence author:

Fatih Mehmet AVŞAR

Meşrutiyet Cad. No: 28/6

06640 Kocatepe, Ankara - TURKEY

References

1. Pappas TN. Peptic Ulcer Disease. In David J. Sabiston Ed: Textbook of Surgery. Philadelphia, WB Saunders, P:847-867, 1997
2. Stabile BE, Stamos MJ. Gastrointestinal Bleeding. In Zinner MJ Ed: Maingot's Abdominal Operations. Connecticut, Appleton & Lange, 1997. P: 289-314.
3. Johnston D, Martin I. Duodenal Ulcer and Peptic Ulceration. In Zinner MJ Ed: Maingot's Abdominal Operations. Connecticut, Appleton & Lange, 1997. P:941-970.
4. Fink AS. Endoscopy. In Zinner MJ Ed: Maingot's Abdominal Operations. Connecticut, Appleton & Lange, 1997. P: 189-238.
5. Beauchamp RD, Thompson JC. Endocrine Tumors of the Pancreas. In Zinner MJ Ed: Maingot's Abdominal Operations. Connecticut, Appleton & Lange, 1997. P: 1961-1976.
6. Yeo CJ, Cameron JL. Pancreas. In David J. Sabiston Ed: Textbook of Surgery. Philadelphia, WB Saunders, 1997. P: 1152-1186.
7. Roy PK, Venzon DJ, Shojamanesh H, Abou-Saif A, Peghini P, Doppman JL, Gibril F, Jensen RT. Zollinger-Ellison syndrome. Clinical presentation in 261 patients. Medicine (Baltimore) 2000 Nov; 79 (6): 379-411
8. Stone WM, Sarr MG, Nagorney DM, McIlrath DC. Chronic pancreatitis. Results of Whipple's resection and total pancreatectomy. Arch Surg 1988 Jul; 123 (7): 815-9.
9. Udelsman R, Yeo CJ, Hruban RH, Pitt HA et al. Pancreaticoduodenectomy for selected pancreatic endocrine tumors. Surg Gynecol Obstet 1993 Sep; 177 (3): 269-78.
10. Broughan TA, Leslie JD, Soto JM, Hermann RE. Pancreatic islet cell tumors. Surgery 1986 Jun; 99 (6): 671-8.