

1-1-2001

Isolated Caudate Nucleus Hemorrhage during the Acute Period of Stroke

SELÇUK ÇOMOĞLU

ŞENAY ÖZBAKIR

Follow this and additional works at: <https://journals.tubitak.gov.tr/medical>



Part of the [Medical Sciences Commons](#)

Recommended Citation

ÇOMOĞLU, SELÇUK and ÖZBAKIR, ŞENAY (2001) "Isolated Caudate Nucleus Hemorrhage during the Acute Period of Stroke," *Turkish Journal of Medical Sciences*: Vol. 31: No. 4, Article 11. Available at: <https://journals.tubitak.gov.tr/medical/vol31/iss4/11>

This Article is brought to you for free and open access by TÜBİTAK Academic Journals. It has been accepted for inclusion in Turkish Journal of Medical Sciences by an authorized editor of TÜBİTAK Academic Journals. For more information, please contact academic.publications@tubitak.gov.tr.

Isolated Caudate Nucleus Hemorrhage during the Acute Period of Stroke

Received: October 13, 2000

Department of Neurology, Ankara Numune Training and Research Hospital, Ankara - TURKEY

Abstract: Caudate hemorrhage is a rare stroke syndrome that accounts for only 3-7% of all primary intracerebral hematomas. In this study, we evaluated eight patients with isolated caudate nucleus hemorrhage for their clinical presentation and neurological findings. **Material and methods:** Eight patients, who were admitted to our department with isolated caudate nucleus hemorrhage, were evaluated for their clinical presentation and present risk factor findings on neurological examination and prognosis. **Results:** The most common symptoms on admission were headache and vomiting (five patients),

whereas the most common findings on neurological examination were unconsciousness and neck stiffness (four patients). Two patients who were unconscious were lost during the course of the disease, whereas the others recovered completely or partially. **Conclusions:** Although isolated caudate nucleus hemorrhage shares common initial symptoms and clinical findings with subarachnoid hemorrhage, it has a better clinical prognosis.

Key Words: Stroke, caudate hemorrhagias, neurologic findings

Introduction

Fifteen percent of all stroke cases result from non-traumatic intracerebral hemorrhages. These hemorrhages most commonly occur in the putaminal and thalamic regions. Intracerebral hemorrhage of the caudate nucleus is quite rare (1-10). Although the putamen and caudate nucleus are both supplied by the deep lenticulostriate artery, it is not known why the incidence of bleeding is higher in the the putamen (2,3,5). Initial complaints and neurological findings mimic subarachnoid hemorrhage, which is characterized by headache and vomiting, accompanied by neck stiffness and alterations in consciousness (1,2,4,5,7,9,10). In this study, we evaluated the clinical presentation, neurological findings and prognosis of isolated caudate nucleus hemorrhagias.

Materials and methods

Eight patients, admitted to our department due to isolated caudate hemorrhage, were included in the study and were evaluated for their clinical presentation, existing risk factors, neurological findings and prognosis. All patients were evaluated with computerized tomography

(CT). In two normotensive patients, digital subtraction angiography was also utilized. All patients received antiedema and other supportive therapies.

Results

There were 5 male and 3 female patients. The average age for the onset of stroke was 58 years (40-70 years). In the medical histories of the patients, three had hypertension, one cardiac disease, one diabetes mellitus and hypercholesterolemia, one diabetes mellitus and hypertension, and one hypertension and cardiac disease. The neurological and radiological findings of the patients are summarized in the Table. Five patients had right-sided and three patients had left sided caudate hemorrhage. Six patients also had open ventricular bleeding (Fig. 1). The most prominent initial neurological complaints were headache and vomiting (seen in five patients). On neurological examination, the most frequently encountered findings were neck stiffness and loss of consciousness (seen in four patients). Antiedema therapy was immediately initiated in all patients. Six patients recovered partially or completely. Two patients died during the course of the disease.

Table 1. The sex, age, risk factors, clinical and features prognosis eight caudate nucleus hemorrhage patients.
 NH: Neurologic history, NF: Neurologic findings, OVB: Open ventricular bleeding, P: Prognosis, LS: Lesion side.

Sex	Age	Risk Factor	NH	NF	OVB	LS	P
F	60	HT	Headache+vomiting	Neck stiffness+unconsciousness	(+)	R	Complete recovery
M	54	Normal	Speech disorder+leftside weakness	Left hemiparesia+dysarthria+Horner's syndrome	(+)	L	Slight recovery
F	40	DM+hypercholesterolemia	Agitation+vomiting	Unconsciousness+neck stiffness+conjugate gaze paralysis	(+)	L	Exitus
F	66	HT+ DM	Convulsion+headache+	Abulia+left sixth nerve palsy	(-)	R	Partial recovery
F	70	HT	Confusion+right side weakness	Verbal amnesia+right hemiparesis+Horner's syndrome	(+)	L	Partial recovery
M	46	HT	Headache+vomiting	Unconsciousness+neck stiffness+anisocoria	(+)	R	Exitus
M	58	HT+Cardiac disease	Headache+vomiting	Neck stiffness+left hemisensory losses	(+)	R	Slight recovery
F	70	Cardiac disease	Headache+incontinence	Unconsciousness+dysarthria+bilateral Babinski sign	(-)	R	Partial recovery

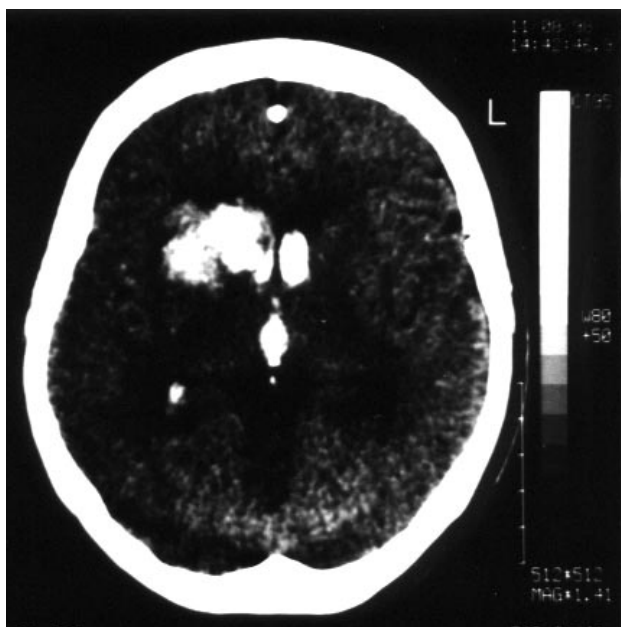


Figure Caudate hemorrhage associated with open ventricular bleeding in axial section of CT.

Discussion

The blood supply of the caudate nucleus comes primarily from the deep penetrating branches of the lenticulostriate artery and from the branches of the Heubner artery, which originates from the anterior cerebral artery to a lesser degree (1,2,4,6-8). Hypertension, which results in sclerotic changes in blood vessels, accounts for most intracerebral hemorrhages. Systemic diseases such as hypertension, diabetes mellitus, hyperlipidemia and cardiac failure are the major risk factors for caudate hemorrhages as they are responsible for other stroke syndromes (2,3,5,7,10). When the medical histories of the patients were reviewed, hypertension was found in three patients, cardiac failure in one patient, DM and hypertension in one patient, hypertension and heart disease in one patient and DM and hypercholesterolemia in one patient. In general, the neurological findings of caudate hemorrhage differ from those of other intracerebral hemorrhages. Headache and neck stiffness, which are present in most patients, can

mimic subarachnoidal hemorrhage. Other neurological findings that are encountered less frequently include motor weakness, epilepsy, apraxia, visual disturbances, motor and sensory aphasias, and behavioral changes in the acute phase of the disease. In our patients, headache and vomiting were the most common initial complaints and loss of consciousness and neck stiffness were the most frequently encountered neurological findings. Loss of cognitive function and behavioral changes are usually seen during the chronic phase of the disease, but as we evaluated the patients only during the acute phase of the disease and only encountered one patient with abulia and another one with verbal amnesia, it is not possible to comment on this issue. Clinical diagnosis was confirmed by CT or MR. As patients tolerate CT more easily and it is more sensitive in the diagnosis of hemorrhages, we preferred CT examination for most of the cases. Cerebral angiography was only performed in two normotensive patients and proved to be normal. Open ventricular system hemorrhage and isolated parenchymal hemorrhage did not differ in prognosis; however, it is not

possible to draw a statistical conclusion due to the limited number of patients. Antiedema and supportive treatments were initiated in all patients. Four patients completely recovered, two recovered partially and two died during the course of the disease.

In conclusion, although the initial symptoms and neurological findings of isolated caudate nucleus lesions and subarachnoidal hemorrhages are very similar, caudate nucleus lesions have a much better prognosis. Our results correlate with the findings in the literature. In order to evaluate the acute and chronic phases of the disease from a broader perspective, multicenter studies should be carried out in an attempt to accumulate more data.

Correspondence author:

Selçuk ÇOMOĞLU

Birlik Mahallesi, 20. Sokak, 14/4

Gaziosmanpaşa, Ankara, TURKEY

References

1. Steinke W, Tatemichi TK, Mohr JP, Massora A, Prohovnik I, Solomon RA. Caudate hemorrhage with moyamoya-like vasculopathy from atherosclerotic disease. *Stroke* 23: 1360-63, 1992.
2. Weisberg LA. Caudate hemorrhage. *Arch Neurol* 41: 971-974, 1984.
3. Budak F, Irtman G. Caudate hemorrhages. *Izmir State Hospital* 2: 299-301, 1992.
4. Waga S, Fujimoto K, Okada M, Miyazaki M, Tanaka Y. Caudate hemorrhage. *Neurosurgery* 18: 445-449, 1986.
5. Mendez MF, Adams NL, Lewandowski S. Neurobehavioral changes associated with caudate lesions. *Neurology* 39: 349-354, 1989.
6. Fernandez Pardal MM, Micheli F, Asconape J, Paradiso G. Neurobehavioral symptoms in caudate hemorrhage: two cases. *Neurology* 35: 1806-1807, 1985.
7. Stein RW, Kase CS, Hier DB, Caplan LR, Mohr JP, Hemmati M, Henderson K. Caudate hemorrhage. *Neurology* 34: 1549-1554, 1984.
8. Kumral E, Eyyapan D, Balkir K. Acute caudate vascular lesions. *Stroke* 30: 100-108, 1999.
9. Damasio AR, Damasio H, Rizzo M, Varney N, Gersh F. Aphasia with nonhemorrhagic lesions in the basal ganglia and internal capsule. *Arch Neurol* 39: 2-14, 1982.
10. Bokura H, Robinson RG. Long-term cognitive impairment associated with caudate stroke. *Stroke* 28: 970-975, 1997.