

1-1-2001

Comparative Histological Analysis of Hepatitis C Virus with Hepatitis B

GÜLEN AKYOL

ÖZLEM SÜER

CEM SEZER

Follow this and additional works at: <https://journals.tubitak.gov.tr/medical>



Part of the [Medical Sciences Commons](#)

Recommended Citation

AKYOL, GÜLEN; SÜER, ÖZLEM; and SEZER, CEM (2001) "Comparative Histological Analysis of Hepatitis C Virus with Hepatitis B," *Turkish Journal of Medical Sciences*: Vol. 31: No. 5, Article 6. Available at: <https://journals.tubitak.gov.tr/medical/vol31/iss5/6>

This Article is brought to you for free and open access by TÜBİTAK Academic Journals. It has been accepted for inclusion in Turkish Journal of Medical Sciences by an authorized editor of TÜBİTAK Academic Journals. For more information, please contact academic.publications@tubitak.gov.tr.

Comparative Histological Analysis of Hepatitis C Virus with Hepatitis B

Received: June 08, 2000

Abstract: Aims: Rates of certain histopathologic features were evaluated in hepatitis C and in hepatitis B materials and analyzed statistically in a Turkish population.

Method: The presence of lymphoid aggregate, steatosis, ductal lesions, sinusoidal inflammation and portal iron deposition were investigated in 80 hepatitis C and 104 hepatitis B specimens and evaluated using the chi-square test and Fisher's exact test. Pan B and T cell markers were used for lymphoid aggregate analysis. P53 and PCNA were applied for the possible impact of steatosis on cell biology.

Results: All mentioned parameters excluding sinusoidal inflammation were found to be

higher in hepatitis C samples. The co-presence of lymphoid aggregate and ductal lesions was found to be significant in hepatitis C. The distribution of T and B cells was similar in both groups. P53 and PCNA expressions were found to be non-significant in both groups.

Conclusion: Our results except sinusoidal inflammation were thought to be in correlation with the reports in the literature. Lower rates of iron deposition might be related to geographic differences that could be observed as a feature of the C virus.

Key Words: Hepatit B virus, Hepatit C virus, histopathology, P53, PCNA

Department of Pathology, Faculty of Medicine,
Gazi University, Ankara - TURKEY

Introduction

Chronic hepatitis is not a single disease, but rather a clinical and pathological syndrome, which has several causes (1). Liver biopsy is of major importance in the evaluation of patients with chronic hepatitis. The histological features of chronic hepatitis have been studied extensively and certain characteristic morphological features have been ascribed to chronic hepatitis of differing origins.

Histopathological changes in chronic hepatitis C have been described in previous reports (2,3). A histologic pattern of mild chronic hepatitis with portal lymphoid aggregate and/or follicles, varying degrees of bile duct damage, lymphocytic infiltration of sinusoids and steatosis was found to be more frequent than other chronic hepatitis. However, in some chronic hepatitis B cases, similar histologic findings are seen (4).

In the present study, our aim was to determine the rate and significance of these features in hepatitis C by comparing their presence in hepatitis B. The intraportal lymphoid cell population in both groups was analyzed.

The presence of viral markers of each type were investigated immunohistochemically in order to determine their significance and reliability in the diagnosis. The samples with steatosis were stained with anti-PCNA and anti-P53 for their possible relation with carcinogenesis (5).

Materials and Methods

Needle biopsy samples fixed in 10% neutral formalin belonging to 80 hepatitis C and 104 hepatitis B cases were included. The patients in the first group were all seropositive for antiHCV, whereas the second group's patients had HBs antigen in their sera. In addition to the routine H&E stain, various other stains like periodic acid Schiff (PAS) with and without diastase digestion for bile duct injury, Masson's trichrome and reticuline for fibroblastic stage and Prussian blue for iron deposition were performed.

Five histological features were defined and evaluated as follows:

1. Lymphoid aggregates/follicles in portal tracts: Follicles consisting of a germinal center with surrounding small lymphocytes or a densely packed collection of small lymphocytes within a portal tract, typically near an interlobular bile duct, were assessed (Figure 1).
2. Bile duct damage (Figure 1): Bile duct damage is characterized by a lymphocytic infiltrate surrounding the interlobular bile ducts. These inflammatory cells may be found between the epithelial cells or migrate through the basement membrane. Beyond this inflammation, loss of polarity, variations in nuclear chromaticity, cytoplasmic vacuolization and mitotic activity in epithelial cells are part of the damage.
3. Fatty change (Figure 2): Large and small droplet vacuoles were defined as absent, mild, moderate and marked.
4. Activation of sinusoidal inflammatory cells (Figure 3): The prominence of lymphocytes and Kupffer cells in sinusoids, in a "beads-on-a-string" pattern, was evaluated as present or absent.
5. Iron deposition (Figure 4): Only portal iron depositions in macrophages and especially in the venous endothelial cells were noted as present or absent.

Immunohistochemical studies.

The presence of viral antigens in the liver was shown

by using antiHBs (Dako-Copenhagen, Denmark), antiHBc (Dako-Copenhagen, Denmark) for the B virus and antiHCV (Signet-Dedham, USA) for the C virus. The phenotype of immunocompetent cells present in and around intraportal lymphoid nodules was analyzed with pan T (CD43-DAKO-Copenhagen, Denmark) and pan B (CD20-DAKO-Copenhagen, Denmark) markers.

Thirty-one hepatitis B and 40 hepatitis C materials having steatosis were stained with antiP53 (DAKO, Copenhagen-Denmark) and antiPCNA (Biogenex-California, USA).

After deparaffinization and hydration steps, 4-micrometer thick sections were stained by the streptavidin-biotin peroxidase indirect technique. Diaminobenzidine (DAB) or AEC was used as the chromogen.

Statistical analysis

The results were evaluated with Chi-square and Fisher's exact tests. Probability values less than 0,05 were considered significant.

Results

The frequencies of each histologic feature in biopsy specimens from HCV and HBV groups are shown in Table 1. Activation of sinusoidal cells, reflecting the lobular inflammatory component of chronic hepatitis, was observed in 18 (22,5%) of 80 HCV cases and 45 (45%) of 104 HBV cases. The higher incidence in B hepatitis was found to be significant ($p < 0,05$).

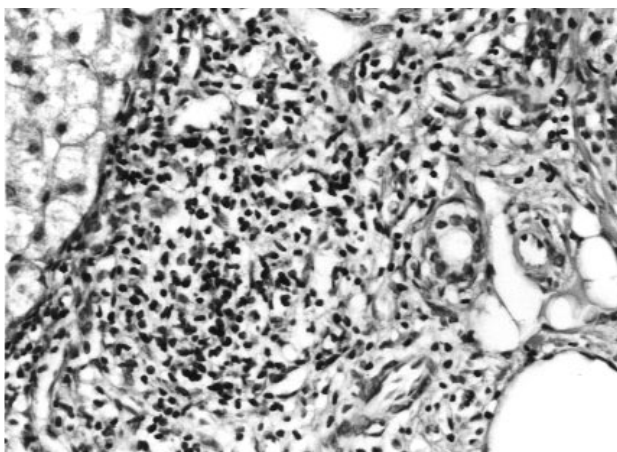


Figure 1. (HE x 200) Lymphoid aggregate close to bile duct.

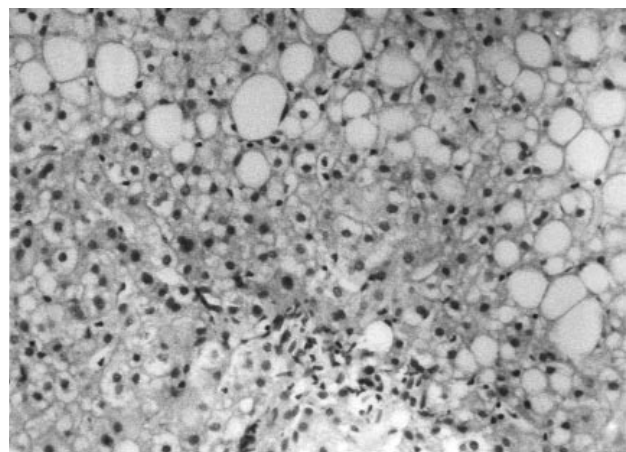


Figure 2. (HE x 200) Large droplet fatty change in hepatocytes.

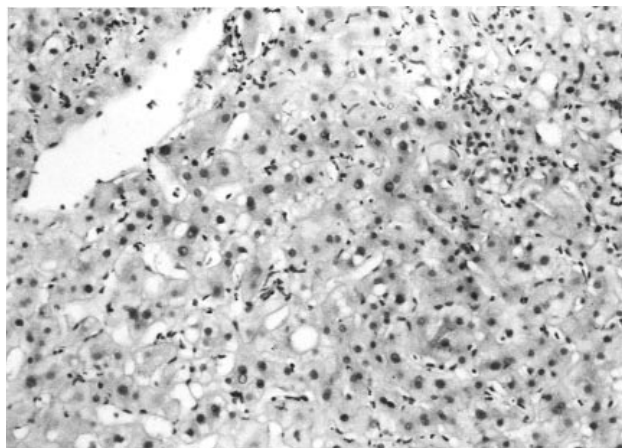


Figure 3. (HE x 200) Sinusoidal inflammation.

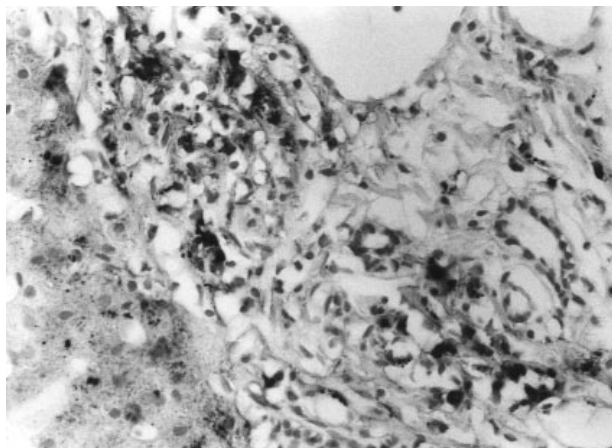


Figure 4. (Prussian blue x 400) Portal iron deposition in macrophages and endothelial cells.

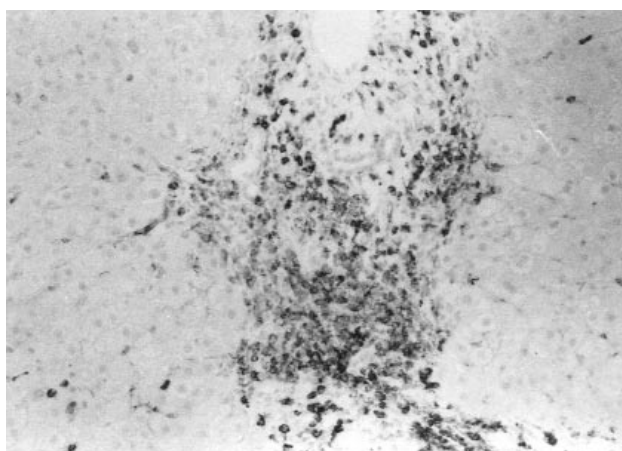


Figure 5. (AEC x 200) CD43 positive cells in the portal-periportal area.

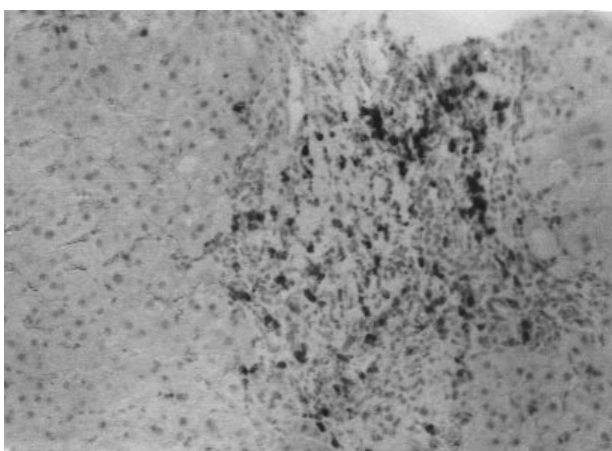


Figure 6. (AEC x 200) CD20 positive cells in the portal-periportal area.

Other histologic features, namely, steatosis, bile duct injury, lymphoid aggregate formation and portal iron deposition in HCV materials were observed at the following rates respectively: 61 (75%), 36 (45%), 46 (60%) and 12 (15%). We observed steatosis in 62 (60%), bile duct injury in 28 (27%), lymphoid aggregate formation in 27 (24%) and portal iron deposition in 7 (5%) of 104 hepatitis B samples.

On statistical analysis, steatosis, bile duct injury and lymphoid aggregate formation were found to be significantly higher in hepatitis C than hepatitis B ($p < 0,05$). Although portal iron deposition was seen more frequently in C cases, the difference was not significant.

Immunohistochemically, lymphoid aggregates showed similar cellular populations in both hepatitis C and B

samples. While portal inflammation and the peripheral zone of lymphoid aggregate were stained with T cell marker prominently, B cell dominancy was observed in the middle of the aggregate (Figures 5 and 6).

Immunohistochemically, the viral markers were shown in 96 (95%) of 104 hepatitis B samples. While all 96 cases were positive with antiHBs, only 44 of 96 were stained with antiHBc. Detection of antiHCV was as low as 22, only 27,5% of all hepatitis C cases (Table 1).

The possible impact of steatosis on molecular carcinogenesis was examined using antiP53 and antiPCNA stains. Forty hepatitis C and 31 hepatitis B samples all having certain amount of steatosis were chosen for this purpose. Only nuclear staining was noted for both antibodies. P53 expression was seen in 4 of (6%) the

	Steatosis	Sinusoidal Inflammation	Bile Duct Lesion	Lymphoid Aggregate	Portal Iron Deposition	Viral Marker Tissue Positivity
HBV	62 (60%)	45 (45%)	28 (27%)	27 (24%)	7 (5%)	96 (95%)
HCV	61 (75%)	18 (22.5%)	36 (45%)	46 (60%)	12 (15%)	22 (27.5%)

Table 1. Histologic features and rates of viral markers.

Table 2. P53/PCNA positivity in materials with steatosis.

	P53		PCNA	
	+	-	+	-
HBV	3	28	6	25
HCV	4	36	17	23

hepatitis C and 104 hepatitis B liver biopsy specimens was examined to determine if any of these features distinguishes HCV from HBV infection.

Although the above-mentioned lesions were observed in both groups, the best set of histological lesions, three features statistically more likely to be associated with hepatitis C, were lymphoid aggregate formation (HCV 60%, HBV 24%), bile duct damage (HCV 45%, HBV 27%) and steatosis (HCV 75%, HBV 60%). These lesions have also been described as histologic markers of chronic hepatitis C in various studies (2-4).

The hepatitis C virus is related to flaviviruses and pestiviruses and cell damage has been attributed to its direct cytopathic effect (6). Fatty change appears to fall into this category, and although it may be present in hepatitis B cases, it seems to be more severe and extensive in hepatitis C materials.

In our previous study, we detected notable rates of P53 overexpression in the materials of steatohepatitis and some nonviral chronic hepatitis materials with steatosis (7). In contrast, in the present study, very few cases of both viral hepatitis groups were stained positively with antiP53 and there were no significant difference between them (Table 2). Steatosis in viral hepatitis may be a different cytological alteration, which does display itself as a mutagenic phenotype but just as an innocent viral effect (8-10). Proliferating cell nuclear antigen (PCNA) expression was higher in hepatitis C materials than in hepatitis B materials. However, the positive cell rate was hardly more than 5% of all hepatocytes and this finding was in the normal ranges of the positivity for PCNA in the liver. Nuclear pleomorphism, which is not very uncommon in liver biopsies, seems to affect the positive staining rates (7,11).

Intraportal lymphoid aggregates and/or follicles are located close to interlobular bile ducts or surround them in both hepatitis C and hepatitis B materials. In the pathogenesis of these lesions, immunologically mediated reactions are suggested (12,13).

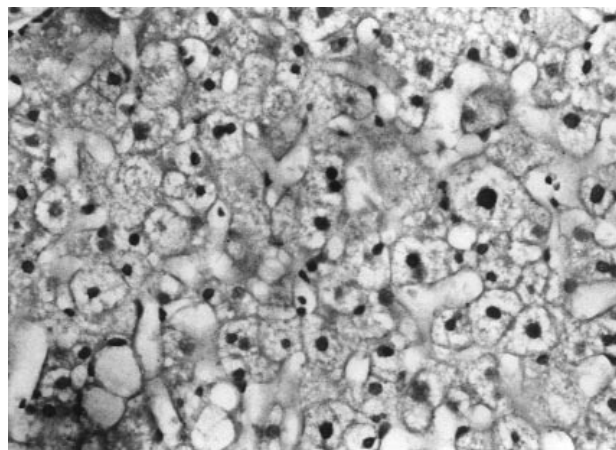


Figure 7. (DAB x 200) Nuclear PCNA positivity.

hepatitis C and 3 of (4%) the hepatitis B cases. PCNA staining (Figure 7) was shown in 6 of (8%) the hepatitis B and 17 (24%) of the hepatitis C cases (Table 2). There was no significant difference between the two groups for P53 and PCNA staining.

Discussion

Some chronic hepatitis types have certain characteristic histologic features (1). Although no pathognomonic cellular marker of HCV infection has been shown to date, a number of histological findings have been cited for their potential diagnostic value, including bile duct damage, lymphoid follicles and/or aggregates within portal tracts, fatty change and sinusoidal reaction. In the present study, the frequency of these lesions in 80

Improvement of these lesions after interferon a treatment has been reported and seems to reflect immune pathogenesis (14). The aggregates showed similar cellular population in both groups and while portal and periportal cells were positive with CD43, B cell dominance was observed in the middle of the aggregates. Our immunophenotyping findings were similar to those in previous studies in which no differences have been reported between chronic hepatitis C or B and autoimmune hepatitis (12-14). In this context, they seem to be true functional lymphoid follicles resembling lymph nodes (14). In a recent study the authors focused on B cell response and extensively analysed B cell activation, proliferation and maturation in the livers of patients with chronic hepatitis C (14). They found similar lymphoid marker expressions with lymph nodes and concluded that the liver is a potential secondary lymphoid organ. The reason why HCV infection preferentially induces the formation of functional B cell response in the liver is currently unclear. However, our results, in accordance with those in the literature, suggest that lymphoid aggregates/follicles are not unique but are a characteristic feature of chronic hepatitis C. Intraportal lymphoid aggregate formations and bile duct injury can be seen in some other nonviral liver diseases like autoimmune hepatitis and primary biliary cirrhosis (15). None of the patients in either group had serologic immune markers, and no histological features of autoimmune hepatitis like plasma cell dominance, periportal liver cell rosettes or severe necroinflammatory reaction were observed.

The duct damage was not severe and did not seem to end with destruction in our materials. Since it is always located close to lymphoid reaction and bile duct epithelium expresses histocompatibility (HLA) antigens, the presence of a lesion appears to be related with immune reaction. Because of the higher frequency of bile duct injury in hepatitis C than in hepatitis B, we assumed that this lesion was another characteristic feature of viral hepatitis C.

During the past few years, there has been much interest in the role of iron in viral hepatitis (16). Iron has long been known to be an essential element for the replication of all organisms, including virulent microorganisms. Stainable iron is found commonly in liver biopsy specimens of patients with acute or chronic

viral hepatitis. Hemosiderin and lipofuchsin were defined in Kupffer cells and this finding was related to repair after injury (17). The implication was that the iron found in the liver in viral hepatitis had been released from hepatocytes damaged by the virus.

Farinati et al. addressed the question of whether HCV may have a direct cytopathic effect on hepatocytes through the activation of iron dependent lipid peroxidation (18). Their results were interpreted as suggesting that mechanisms of hepatocyte damage are different in hepatitis B and C and that the altered iron metabolism and iron accumulation in hepatitis may be related to an effect of the virus itself on hepatocytes or possibly on the immune cells of the liver. In our study, iron deposition was observed more frequently in hepatitis C than hepatitis B but the difference was not statistically significant. The localization of iron deposition was similar but deposition in portal macrophages and venous endothelial cells was noted more in hepatitis C materials. Barton et al. were first to stress the importance of portal distribution of a hepatic iron as a predictor of poor response to IFNa (19). It was speculated that iron in portal endothelial cells could interfere with their functions during the inflammatory process, such as clearance of the virus, or could participate in immune mediated reaction (20). However, they did not detect any significant differences between the cases of hepatitis B, C or autoimmune hepatitis according to iron deposition localization (19).

The number of samples showing iron deposition in our study was not as high as reported in the literature. But there have been some reports about similar observations from Israel (16).

We speculate that this could be due to differences in the type and geographic distribution of the virus, which is a very well known feature of the C virus. Thus further investigations about serum iron and iron binding protein analyses in correlation with different viral genotypes, which are beyond the scope of this study, may be needed.

Correspondence author:

Özlem SÜER

5. Sok. 71/5 06580

Anıttepe, Ankara - TURKEY

References

1. Desmet V, Gerber M, Hoofnagle J, Manns M, Scheuer PJ. Classifications of chronic hepatitis: Diagnosis, grading and staging. *Hepatology* 19: 1513-1520, 1994.
2. Scheuer PJ, Ashrafzadeh P, Sherlock S, Brown D, Dusheiko GM. The pathology of hepatitis C. *Hepatology* 15: 567-571, 1992.
3. The French Metavir cooperative study group. Intraobserver and interobserver variations in liver biopsy interpretation in patients with chronic hepatitis C. *Hepatology* 20: 15-20, 1994.
4. Lefkowitz JH, Schyff ER, Davis GL, Perrillo RP, Lindsay K, Bodenheimer HC, Jr, Balart IA, Ortego TJ, Payne J, Dienstag JL, Gibas A, Jacobson IM, Tamburro CH, Carey W, O'Brien C, Sampliner R, Van Thiel DH, Feit D, Albrecht J, Meschivitz C, Sanghvi B, Vaughan RD. Hepatitis interventional therapy group. Pathological diagnosis of chronic hepatitis C: A multicenter comparative study with chronic hepatitis B. *Gastroenterology* 104: 595-603, 1993.
5. Boisson F, Fremont S, Migeon C, Nodari F, Droesch S, Gerard P, Parache RM, Nicolas JP. Human haptocorrin in hepatocellular carcinoma. *Cancer Detect Prev* 23 (2): 89-96, 1999.
6. Gonzalez – Peralta RP, Davis GL, Lau JYN. Pathogenetic mechanisms of hepatocellular damage in chronic hepatitis C virus infection. *J Hepatol* 21: 255-259, 1994.
7. Akyol G, Dursun A, Poyraz A, Uluoglu O, Ataoglu O, Edaly N, Memiş L. P53 and proliferating cell nuclear antigen (PCNA) expression in non-tumoral liver diseases. *Pathol Int* 49: 214-221, 1999.
8. Pontisso P, Belluco C, Bertorelle R, De Moliner L, Chieco- Bianchi L, Nitti D, Lise M, Alberti A. Hepatitis C virus infection associated with human hepatocellular carcinoma: Lack of correlation with p53 abnormalities in Caucasian patients. *Cancer* 83 (8): 1489-1494, 1998.
9. Kane JM, Shears LL, Hierholzer C, Ambs S, Billier TR, Posner MC. Chronic hepatitis C virus infection in humans: Induction of hepatic nitric oxide synthase and proposed mechanism for carcinogenesis. *J Surg Res* 69 (2): 321-324, 1997.
10. Nagao T, Kondo F, Sato T, Nagato Y, Kondo Y. Immunohistochemical detection of aberrant p53 expression in hepatocellular carcinoma: Correlation with cell proliferative activity indices, including mitotic index and MIB-1 immunostaining. *Hum Pathol* 26: 326-333, 1995.
11. Kawakita N, Seki S, Sakaguchi H, Yanai A, Kuroki T, Mizoguchi Y, Kobayashi K, Monna T. Analysis of proliferating hepatocytes using a monoclonal antibody against proliferating cell nuclear antigen/cyclin in embedded tissues from various liver diseases fixed in formaldehyde. *Am J Pathol* 140: 513-520, 1992.
12. Mosnier JF, Degott C, Marcellin P, Hélin D, Erlinger S, Benhamou JP. The intraportal lymphoid nodule and its environment in chronic active hepatitis C: An immunohistochemical study. *Hepatology* 17: 366-371, 1993.
13. Hino K, Okuda M, Konishi T, Yamashita A, Kayano K, Kubota M, Yasunaga M, Fukumoto Y, Okita K. Analysis of lymphoid follicle in liver of patients with chronic hepatitis C. *Liver* 12: 387-391, 1992.
14. Murakami J, Shimizu Y, Kashii Y, Kato T, Minemura M, Okada K, Nambu S, Takahara T, Higuchi K, Maeda Y, Kumada T, Watanabe A. Functional B-cell response in intrahepatic lymphoid follicles in chronic hepatitis C. *Hepatology* 30: 143-150, 1999.
15. Bach N, Thung SN, Schaffner F. The histological features of chronic hepatitis C and autoimmune chronic hepatitis: A comparative analysis. *Hepatology* 15: 572-577, 1992.
16. Bonkovsky HL, Banner BF, Rothman AL. Iron and chronic viral hepatitis. *Hepatology* 25: 759-768, 1997.
17. Ishak KG. Light microscopic morphology of viral hepatitis. *Am J Clin Pathol* 65: 787-827, 1976.
18. Farinati RF, Cardin R, DeMaria N, Della Libera G, Marafin C, Lecis E, Burra P, Floreani A, Cecchetto A, Naccarato R. Iron storage, lipid peroxidation and glutathione turnover in chronic anti-HCV positive hepatitis. *J Hepatol* 22: 449-456, 1995.
19. Banner BF, Barton AL, Cable EE, Smith L, Bonkovsky HL. A detailed analysis of the Knodell score and other histologic parameters as predictors of response to interferon therapy in chronic hepatitis C. *Mod Pathol* 8: 232-238, 1995.
20. Kaji K, Nakanuma Y, Sasaki M, Unoura M, Kobayashi K, Nonomura A. Hemosiderin deposition in portal endothelial cells: A novel hepatic hemosiderosis frequent in chronic viral hepatitis B and C. *Hum Pathol* 26: 1080-1085, 1995.