

1-1-2001

Adenomyoma of the Stomach Accompanying Gastric Adenocarcinoma

SEMA HÜCÜMENOĞLU

MUSA ZORLU

HAKAN GÜZEL

FATİH MEHMET AVŞAR

Follow this and additional works at: <https://journals.tubitak.gov.tr/medical>



Part of the [Medical Sciences Commons](#)

Recommended Citation

HÜCÜMENOĞLU, SEMA; ZORLU, MUSA; GÜZEL, HAKAN; and AVŞAR, FATİH MEHMET (2001)
"Adenomyoma of the Stomach Accompanying Gastric Adenocarcinoma," *Turkish Journal of Medical Sciences*: Vol. 31: No. 6, Article 21. Available at: <https://journals.tubitak.gov.tr/medical/vol31/iss6/21>

This Article is brought to you for free and open access by TÜBİTAK Academic Journals. It has been accepted for inclusion in Turkish Journal of Medical Sciences by an authorized editor of TÜBİTAK Academic Journals. For more information, please contact academic.publications@tubitak.gov.tr.

Sema HÜCÜMENOĞLU¹
Musa ZORLU²
Hakan GÜZEL²
Fatih Mehmet AVŞAR³

Adenomyoma of the Stomach Accompanying Gastric Adenocarcinoma

Departments of ¹Pathology, ²General Surgery, SSK Ankara Training and Research Hospital, ³Department of General Surgery, Ankara Numune Training and Research Hospital, Ankara - TURKEY

Received: May 9, 2001

Key Words: gastric adenomyoma, gastric adenocarcinoma

Adenomyoma is an uncommon benign gastric lesion characterized by duct-Brunner's gland-like structures embedded within a smooth muscle stroma. This lesion occurs in an intramural extramucosal position, usually in the gastric antrum (85%) or pylorus (15%) (1). It is believed to be developmental in origin and is sometimes categorized as belonging to a subgroup of a heterotopic pancreas (2). The lesions are generally within 4 cm of the pylorus (3).

We report a case of coexistence of gastric adenomyoma and adenocarcinoma rarely described in the literature.

Case Report

A 23-year-old female was admitted to the Department of Gynecology with a 2 month history of abnormal vaginal bleeding and a tumor mass in the lower abdominal region. Physical examination and pre-operative investigations showed that there were bilateral ovarian masses. She underwent laparoscopic resection of the uterus and bilateral salpingo-oophorectomy. The diagnosis of this specimen was bilateral ovarian metastatic carcinoma. To investigate the primary tumor, computed tomography scan procedures demonstrated thickening in the wall of lesser curvature of the stomach (Figure 1). Endoscopic examination of the upper gastrointestinal tract revealed a deep ulcer extending from the cardia through the lesser curvature, 5 cm in diameter and with an irregular border. After examination of the endoscopic biopsy specimen, she was diagnosed with gastric undifferentiated carcinoma and intestinal

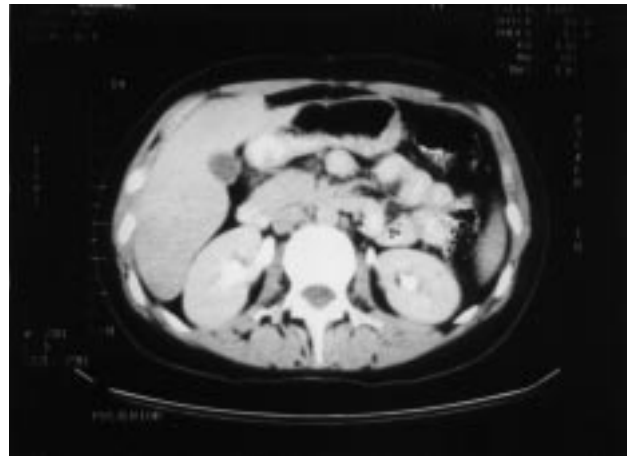


Figure 1. Microphotograph of computed tomography scan. Thickening in the wall of lesser curvature because of the infiltrating gastric adenocarcinoma is seen.

metaplasia. Duodenal mucosa appeared normal. Laboratory findings did not reveal any significant alterations. Carcinoembryonic antigen, alpha-fetoprotein and cancer associated carbohydrates (Ca 19.9, Ca125) were within normal limits.

Under general anesthesia, laparotomy was performed and she was diagnosed with peritonitis carcinomatosa. Therefore she underwent D₂ total gastrectomy, and Roux-en-Y esophagojejunostomy. This surgical specimen, fixed in 10% formalin, was sent to the pathology department and sampled. Samples were embedded in paraffin and sections were stained with hematoxylin and eosin.

Pathologic findings: Macroscopic examination of the surgical specimen revealed the lesser curvature to be

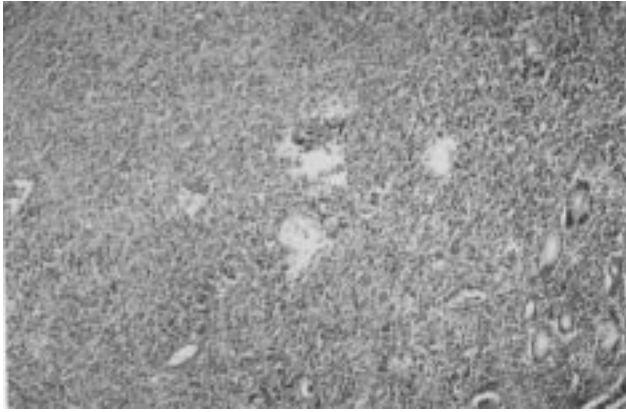


Figure 2. Histological appearance of poorly differentiated adenocarcinoma of diffuse type. (Hematoxylin-eosin x32)

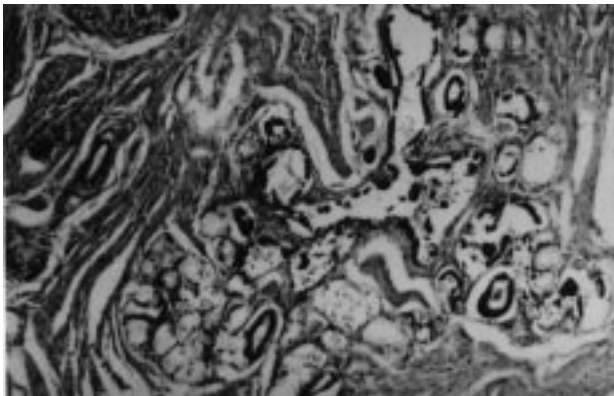


Figure 3. Microscopic view of the gastric adenomyoma located in the muscularis propria. It is characterized by branching, ductular structures embedded in smooth muscle bundles. And Brunner's glands are also present. (Hematoxylin-eosin x100)

diffusely infiltrated by an ulcerated tumor mass 7x6 cm in size. Beneath the tumor there was a spongy area approximately 1.5 cm long, situated within the muscle layer of the stomach. Microscopically, the tumor was a poorly differentiated adenocarcinoma of diffuse type, extending out to the serosa and with spread to lymphatics and regional lymph nodes (Figure 2). Random examination of the gastric mucosa away from the tumor demonstrated areas of intestinal metaplasia; 15 mm away from the tumor in the muscularis propria and extending to the serosa there were glandular, in part branching, ductular structures, lined by a columnar epithelium, surrounded by bundles of smooth muscle tissue (Figure 3). In addition, Brunner's glands were found during microscopic examination. Thus, the final diagnosis of the lesion in the muscularis propria was gastric adenomyoma.

Discussion

Gastric adenomyoma was first described by Magnus-Alsleben in 1903 (1). Approximately 40 cases have been described in the literature (3). Histologically, this lesion is characterized by ductal structures lined by cuboidal to columnar epithelium surrounded by smooth muscle bundles and, occasionally, Brunner's glands and heterotopic pancreas (3, 4). If there is a predominance of pancreatic tissue then the term 'pancreatic heterotopia' or 'pancreatic rest' is more appropriate (1). Ling et al. reported nine cases and Barnert et al. reported one case of gastric adenomyoma (5, 6). Van Der Gaag found an adenomyoma in one clinically healthy dog in his study, which was a survey of the histology of gastric biopsies in 501 dogs, consisting of 19 clinically healthy dogs and 482 vomiting dogs (7). Vandelli reported a case of gastric adenomyoma and reviewed the cases which had been recorded until that time (8).

While adenomyomas of the stomach are very rare, pancreatic heterotopia occurs with an incidence of 0.55-15.7%, most often in antral, pyloric, duodenal or jejunal locations as assessed by autopsy studies (9, 10). The histogenesis of gastric adenomyoma is unknown, although most reports consider them to be of developmental origin (1). It is probably a hamartoma rather than a true neoplasm (4, 11). The age range for reported cases is 8 weeks to 81 years, but the majority of cases occur in the fourth to sixth decades.

Like conventional heterotopic pancreas, gastric adenomyoma has occasionally been found to undergo malignant transformation (4, 12). Gastritis cystica profunda is also considered to be among the lesions of intramural glandular cystic lesions of the stomach. This is a diffuse lesion characterized by submucosal cysts surrounded by smooth muscle, which communicate with the gastric surface mucosa, which is often affected by gastritis, and has a well recognized association with gastric adenocarcinoma (1, 13). But cases of adenomyoma of the stomach in association with gastric adenocarcinoma are reported very rarely. Chapple's case was the first report of adenomyoma of the stomach associated with gastric carcinoma (1). Kanehira described a gastric adenomyoma associated with superficial gastric adenocarcinoma that was found in a 72-year-old male. Although the focus of the carcinoma in his case was located in the center of the adenomyoma, he claimed that this finding could not support the etiology of a gastric

carcinoma originating in an adenomyoma (2). In our case the lesion was located at a distance from the tumor. An unusual coexistence of a malignant Hodgkin gastric lymphoma of the gastric antrum with a gastric adenocarcinoma within an adenomyoma of the cardia is reported by Agresta (14).

In gastric gland heterotopias, lymphoid stroma may be found. Delvaux reported a patient presenting with a lymphoepithelial cyst, a lesion which was not described in the stomach previously (15). Delvaux classified submucosal epithelial lesions as hamartomas, gastric gland heterotopia, duplication, submucosal cystic glands, gastritis cystica profunda and adenomyoma (15).

Treatment of gastric adenomyoma is by resection, and recurrence has not been reported. Laparoscopic resection of the stomach has been reported (3).

We suggest that glandular and cystic intramural lesions of the stomach are a heterogeneous group. Our case is one of a few reports of adenomyoma of stomach accompanying gastric carcinoma.

Correspondence author:

Sema HÜCÜMENOĞLU

Hoşdere C. No: 164/3

Y. Ayrancı, Ankara - TURKEY

References

1. Chapple CR, Muller S, Newman J. Gastric adenocarcinoma associated with adenomyoma of the stomach. *Postgraduate Medical Journal*. 64: 801-3, 1988.
2. Kanehira E, Kawaura Y, Ohta Y, Tanaka I, Kawada N, Nonomura A. Adenomyoma in association with early gastric carcinoma. *Gan No Rinsho*. 36 (14): 2475-9, 1990.
3. Reardon PR, Schwartz MR, Fagan SP, Reardon MJ, Brunicardi FC. Completely laparoscopic resection of a rare pyloric tumor with laparoscopically sutured gastroduodenostomy. *Laparoendosc Adv Surg Tech A*. 9 (2): 147-54, 1999.
4. Rosai J. *Gastrointestinal tract in Ackerman's surgical pathology*, 8th ed. St. Louis: Mosby, 617, 1996.
5. Barnert J. Adenomyoma of the stomach (pancreatic heterotopia)-case report and review of the literature. *Leber Magen Derm*. 115: 152-6, 1985.
6. Ling CH. Gastric adenomyoma with report of 9 cases. *Chung Hua Wai Ko Tsa Chih*. 23: 424-5, 446, 1985.
7. Van Der Gaag I. The histological appearance of peroral gastric biopsies in clinically healthy and vomiting dogs. *Can J Vet Res*. 52: 67-74, 1988.
8. Vandelli A, Cariani G, Bonora G, Padovani F, Saragoni L, Dell'Amore D. Adenomyoma of the stomach: report of a case and review of the literature. *Surg Endosc*. 7: 185-7, 1993.
9. Erberich H, Handt S, Mittermayer C, Tietze L. Simultaneous appearance of an adenomyoma and pancreatic heterotopia of the stomach. *Virchows Arch*. 436: 172-4, 2000.
10. Feldmann MT, Weinberg. Aberrant pancreas: cause of duodenal syndrome. *JAMA*. 148: 893, 1952.
11. Clarke BE. Myoepithelial hamartomata of the gastrointestinal tract. *Arch Pathol*. 30: 143-52, 1940.
12. Kneafsey PD, Demetrick DJ. Malignant transformation in a pyloric adenomyoma: a case report. *Histopathology*. 20: 433-5, 1992.
13. Franzing G, Novelli P. Gastritis cystica profunda. *Histopathology*. 5: 535-47, 1981.
14. Agresta F, Della Libera D. Malign transformation of an adenomyoma of the cardia and malign Hodgkin gastric lymphoma: an unusual coexistence. *Minerva Chir*. 55 (1-2) 49-52, 2000.
15. Delvaux S, Ectors N, Geboes K, Desmet V. Gastric gland heterotopia with extensive lymphoid stroma: a gastric lymphoepithelial cyst. *Am J Gastroenterol*. 91 (3): 599-601, 1996.