

1-1-2003

Paratesticular Solitary Fibrous Tumour: Case Report and Review of the Literature

NUSRET AKPOLAT

ARSLAN ARDIÇOĞLU

SEYFETTİN YAHŞİ

A.RAHMİ ONUR

Follow this and additional works at: <https://journals.tubitak.gov.tr/medical>



Part of the [Medical Sciences Commons](#)

Recommended Citation

AKPOLAT, NUSRET; ARDIÇOĞLU, ARSLAN; YAHŞİ, SEYFETTİN; and ONUR, A.RAHMİ (2003)
"Paratesticular Solitary Fibrous Tumour: Case Report and Review of the Literature," *Turkish Journal of Medical Sciences*: Vol. 33: No. 2, Article 11. Available at: <https://journals.tubitak.gov.tr/medical/vol33/iss2/11>

This Article is brought to you for free and open access by TÜBİTAK Academic Journals. It has been accepted for inclusion in Turkish Journal of Medical Sciences by an authorized editor of TÜBİTAK Academic Journals. For more information, please contact academic.publications@tubitak.gov.tr.

Nusret AKPOLAT¹
Arslan ARDIÇOĞLU²
Seyfettin YAHSI¹
A. Rahmi ONUR²

Paratesticular Solitary Fibrous Tumour: Case Report and Review of the Literature

Departments of ¹Pathology and ²Urology,
Faculty of Medicine, Firat University, Elazığ -
TURKEY

Received: January 29, 2002

Key Words: Paratestis, Solitary Fibrous
tumour

Solitary fibrous tumour (SFT) is a rare neoplasm first described in the pleura, but which may also arise from other serosal surfaces outside the pleura (1). The aetiology of SFT is unknown and usually recognized in the third or fourth decades of life. SFTs of the testis or of paratesticular origin are extremely rare, although they exhibit similar histopathological findings to SFTs which originate at other sites in the body (1,2). In the present case report, we describe an SFT within the scrotum neighbouring the epididymis and discuss the morphological characteristics and differential diagnosis of this paratesticular SFT in respect of previously defined histopathological findings of this tumour that originated at other sites in the body.

Case Report

A 20-year-old man with a 4-year history of left scrotal swelling and pain in the right testis which increased with activity attended the outpatient clinic of the Urology Department of the Firat Medical Centre. Physical examination revealed a left varicocele and a lobulated, firm, tender mass near the right testis, which was not fixed to the surrounding structures. Ultrasonography showed a lobulated mass with diameters of 2 x 1.5 cm and 1 x 0.5 cm. Since the lesion was outside the testis, a scrotal exploration was performed. A firm lobulated mass was detected and consequently excised. The patient also underwent unilateral varicocelectomy for the left-sided varicocele.

Macroscopic examination of the lesion revealed two solid structures 2 x 1.5 x 0.5 cm and 1 x 0.5 x 0.2 cm in size. The masses were yellowish-grey, firm and well circumscribed with the cut surfaces exhibiting a fibrillary

and nodular appearance. Microscopically, there were randomly distributed clusters of fibrous tissue, and multiple prominent vessels were detected within these. Additionally, hyalinization, myxoid degeneration and chronic inflammatory infiltration (predominantly lymphocyte) were determined on microscopic examination averaging (Figures 1 and 2). Mitotic figures were detected 2 per 10 high-power fields (HPF) in the tumour. Immunohistochemically there was negative staining of the tumour with cytokeratin (AE1/AE3), desmin, smooth muscle actin and S-100 protein, whereas a diffuse positive staining by vimentin and focal positive staining by CD34 (Figure 3) were demonstrated.

Clinical characteristics and histopathological findings led to the diagnosis of a SFT of paratesticular origin. No local recurrence or distant metastases were detected at the end of 27 months of follow-up.

SFTs are rare and generally benign neoplasms most often arising from the pleura. However, in the past several years they have been recognized in many extrathoracal sites. Among these, the meninges (3,4), mouth (5), nasal cavity (3,6), mediastinum (3,7), orbita (6,8), pelvis (3), retroperitoneum (3,6), kidney (3,9), vagina (9,10), vulva (11), bladder (12,13), seminal vesicles (12), prostate (12,14-16), testis and paratesticular region (1,2) were the sites most often reported. However, SFTs of testicular or paratesticular origin constitute a minor proportion of these and do not exceed more than a few cases (1,2).

There is still controversy regarding the neoplastic features of fibrous proliferations of testicular or paratesticular origin; several authors consider these tumours to be real neoplasms whereas others classify

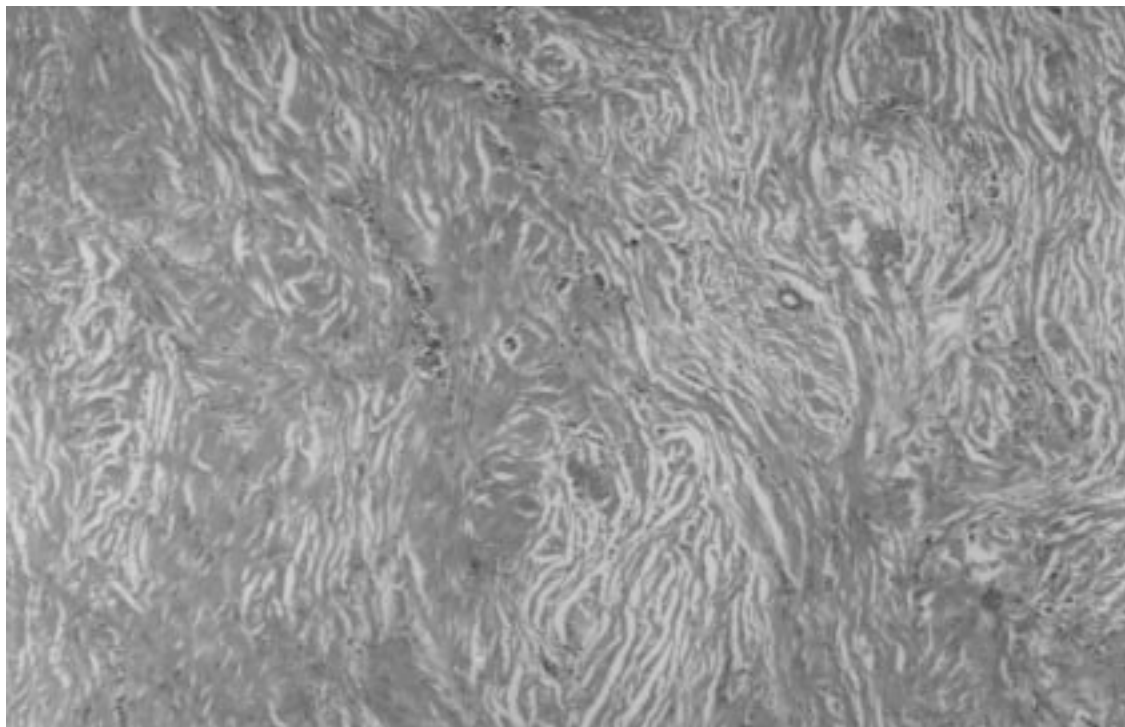


Figure 1. Abundant and hyalinized connective tissue, vessels and perivascular lymphocyte infiltration (H&E, x 40).

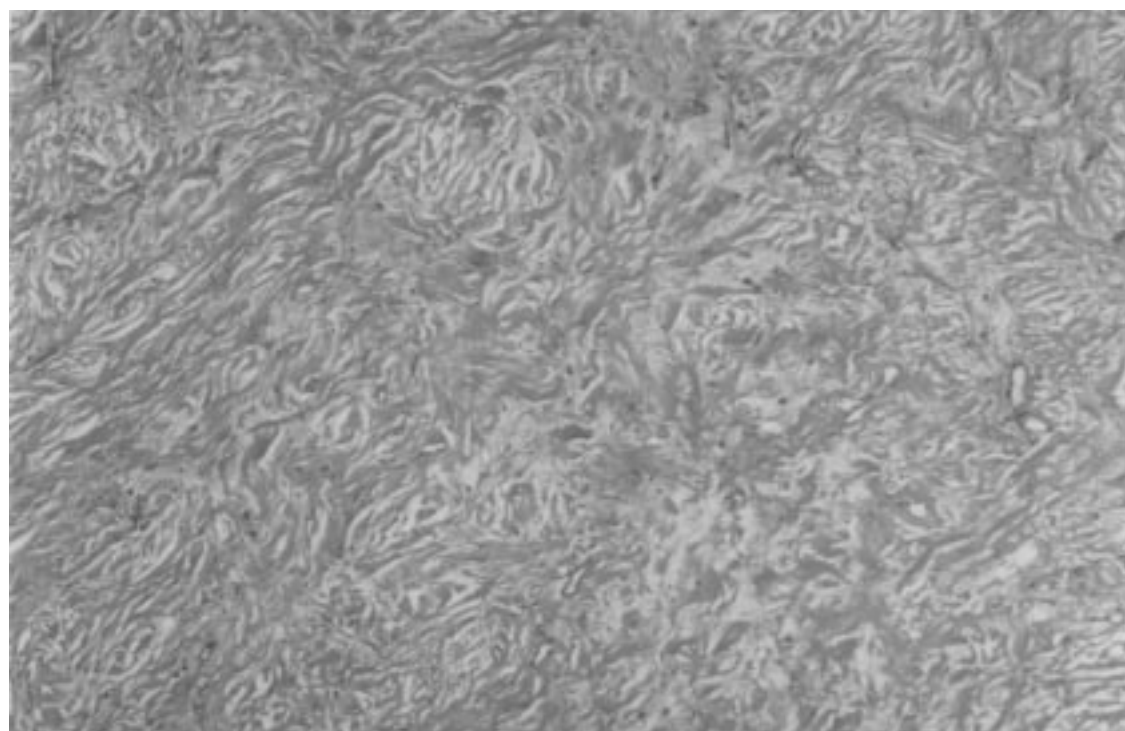


Figure 2. Mixoid degeneration fields in the tumour (H&E, x 40).

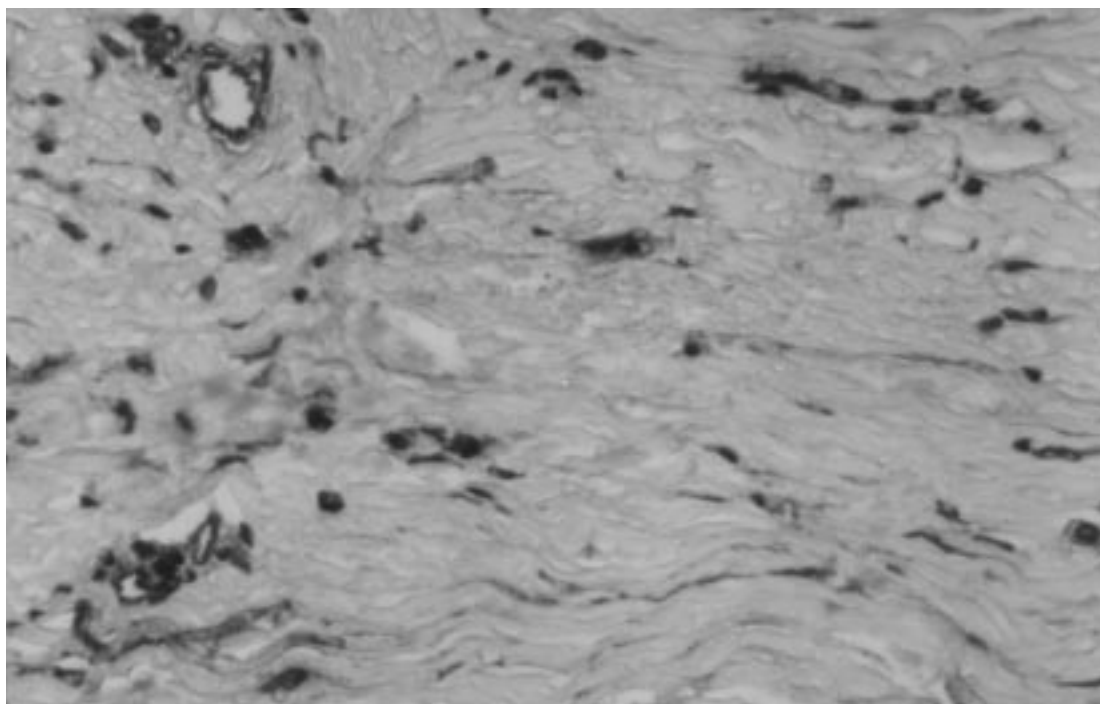


Figure 3. Immunohistochemically, focal staining for CD34 is observed in fibrous tissue (x 100).

them among the pseudotumours (2). SFT of paratesticular origin has been considered a variant of the fibrous pseudotumour and has also been called nodular or diffuse fibrous proliferation, chronic proliferative periorchitis, inflammatory pseudotumour, proliferative funiculitis and fibromatous periorchitis. Some authors included these tumours within the classification of testicular tunic fibroma (2).

SFTs are predominantly diagnosed in women. However, in several studies different gender ratios have been reported (17-19). The tumour is most often detected between the ages of 19 and 85, and the median age of diagnosis is reported to be 50-58 (2,11,17-19).

Macroscopically, SFT are well-circumscribed, pediculated or sessile tumours, elastic in character with a yellowish-white appearance. Their cut surface does not usually involve necrosis or haemorrhagic areas (11,18-20). Microscopic features constitute clusters of bland spindle cells and a storiform pattern in some areas. The tumour is usually hypocellular, but may occasionally exhibit hypercellularity, and there may be areas with hyalinization and myxoid degeneration (2,5,17). Neoplastic cells have a spindle nucleus with scattered

chromatin, and the margins of the cell cannot be clearly identified. Thin and thick-walled vessels of moderate size are found in all parts of the tumour (2,3,17). A mitotic count does not exceed 1 or 2 per 10 high-power fields (2,9,17,20). Chronic inflammatory cell infiltration may occur to various degrees, which are usually composed of lymphocytes and may sometimes be lymphoplasmocytic in character (9,15,18). The microscopic findings in our case were consistent with the literature.

Immunohistochemically, SFTs were strongly positive for vimentin, focally positive for actin in some cases and usually positive for CD34. They were negatively stained for desmin, S-100 and keratin (2,3,5,6,11,15,17,18). In our case, negative staining was observed for pan-cytokeratin (AE1/AE3), desmin, smooth muscle actin and S-100, whereas there was diffuse staining for vimentin and focal positive staining for CD 34. Extracellular collagen and scattered reticulin fibres could be demonstrated by Trichrome and reticulin stains (2). Further examination by electron microscopy revealed these to be myofibroblastic or fibroblastic (1).

Initially, it was hypothesized that SFTs originate from mesothelium, and these tumours were thus called local

mesothelioma (19). However, later studies with electron microscopy and immunohistochemistry revealed that SFTs originate from submesothelial soft tissue. Additionally, diffuse positive staining of SFTs for vimentin and CD34 and negative staining for cytokeratin also proved that they are not mesothelial in origin (21-23).

Although SFTs are usually benign, in a few cases aggressively characterized malignant forms have also been reported. Malignant SFTs exhibit necrosis and high mitosis (> 4 mitosis/10 HPF) and are usually more cellular with atypical cell morphology. They also have a high risk of metastases and recurrence. Malignant SFTs are more widely treated with excision than benign SFTs, and if there is metastasis radiotherapy for metastatic tumour is recommended (18,19).

In the differential diagnosis of SFT, connective tissue tumours such as hemangioperiosteum, sex cord stromal tumours, fibrosarcoma and fibrous pseudotumour should be included. This tumour differs from hemangioperiostoma in lacking a complete vascularized pattern and is also different from fibrosarcoma in lacking a herring-bone pattern. Since SFT may have sex cord components it does not resemble sex cord stromal tumours and may be distinguished from gonadal stromal fibroma by different morphological and

immunohistochemical features (1,2). Patients with SFT have no history of previous trauma, hydrocele or infection, but a history including these pathologies usually is associated with fibrous pseudotumours and helps in the differential diagnosis of these two different entities (2).

The treatment of choice in SFT was reported to be local excision and complete removal of the tumour, which revealed no local recurrence or metastases.

In conclusion, SFT is a real neoplasm that should be distinguished histopathologically from other tumours of the testis. Similarly, it must be considered in the differential diagnosis of patients with intrascrotal masses and should not be confused with malignant neoplasm of the testis. Thus, unnecessary orchidectomies may be avoided in these rare tumours, which can be managed successfully by local excision.

Correspondence author:

Nusret AKPOLAT

Department of Pathology,

Faculty of Medicine, Firat University

23200 Elazığ - TURKEY

References

1. Fisher C, Bisceglia M. Solitary fibrous tumour of the spermatic cord. *British J of Urology* 74: 798-799, 1994
2. Jones MA, Young RH, Scully RE. Benign fibromatous tumors of the testis and paratesticular region: a report of 9 cases with a proposed classification of fibromatous tumors and tumor-like lesions. *Am J Surg Pathol* 21: 296-305, 1997.
3. Morimitsu Y, Nakajima M, Hisaoka M, Hashimoto H. Extrapleural solitary fibrous tumor: clinicopathologic study of 17 cases and molecular analysis of the p53 pathway. *APMIS* 108: 617-25, 2000.
4. Rodriguez L, Lopez J, Marin A, Cardozo D, Molina O, Cardozo J. Solitary fibrous tumor of the meninges. *Clin Neuropathol* 19: 45-8, 2000.
5. Alawi F, Stratton D, Freedman PD. Solitary fibrous tumor of the oral soft tissues: a clinicopathologic and immunohistochemical study of 16 cases. *Am J Surg Pathol* 25: 900-10, 2001.
6. Fukunaga M, Naganuma H, Nikaido T, Harada T, Ushigome S. Extrapleural solitary fibrous tumor: a report of seven cases. *Mod Pathol* 10: 443-50, 1997.
7. Witkin GB, Rosai J. Solitary fibrous tumor of the mediastinum. A report of 14 cases. *Am J Surg Pathol* 13: 547-57, 1989.
8. Havlik DM, Farnath DA, Bocklage T. Solitary fibrous tumor of the orbit with a t(9;22)(q31;p13). *Arch Pathol Lab Med* 124: 756-8, 2000.
9. Akiyama Y, Nabeshima K, Koita H, Yamanaka M, Koono M. Solitary fibrous tumor of the vagina. *Pathol Int* 50: 327-31, 2000.
10. Vadmal MS, Pellegrini AE. Solitary fibrous tumor of the vagina. *Am J Dermatopathol* 22: 83-6, 2000.
11. Nielsen GP, O'Connell JX, Dickersin GR, Rosenberg AE. Solitary fibrous tumor of soft tissue: a report of 15 cases, including 5 malignant examples with light microscopic, immunohistochemical, and ultrastructural data. *Mod Pathol* 10: 1028-37, 1997.
12. Westra WH, Grenko RT, Epstein J. Solitary fibrous tumor of the lower urogenital tract: a report of five cases involving the seminal vesicles, urinary bladder, and prostate *Hum Pathol* 31: 63-8, 2000.

13. Bainbridge TC, Singh RR, Mentzel T, Katenkamp D. Solitary fibrous tumor of urinary bladder: report of two cases. *Hum Pathol* 28: 1204-6, 1997.
14. Sekine H, Ohya K, Kojima S, Mizuguchi K. Solitary fibrous tumor of the prostate. *Int J Urol* 8: 137-8, 2001.
15. Pins MR, Campbell SC, Laskin WB, Steinbronn K, Dalton DP. Solitary fibrous tumor of the prostate: a report of 2 cases and review of the literature. *Arch Pathol Lab Med* 125: 274-7, 2001.
16. Takeshima Y, Yoneda K, Sanda N, Inai K. Solitary fibrous tumor of the prostate. *Pathol Int* 47: 713-7, 1997.
17. Brunnemann RB, Ro JY, Ordonez NG, Mooney J, El-Naggar AK, Ayala AG. Extrapleural solitary fibrous tumor: a clinicopathologic study of 24 cases. *Mod Pathol* 12: 1034-42, 1999.
18. Chang YL, Lee YC, Wu CT. thoracic solitary fibrous tumor: clinical and pathological diversity. *Lung cancer* 23: 53-60, 1999.
19. Cardillo GC, Facciolo F et al. localized (solitary) fibrous tumors of the pleura: an analysis of 55 patients. *Ann thorac surg* 70: 1808-12, 2000.
20. Perrot M, Kurt AM, Robert JH, Borisch B, Spiliopoulos A. clinical behavior of solitary fibrous tumors of the pleura. *Ann. Thorac. surg* 67: 1456-9, 1999.
21. Said JW, Nash G, Banks-Schlegel S, Sassoon AF, Shintaku IP. Localized fibrous mesothelioma: an immunohistochemical and electron microscopic study. *Hum Pathol* 15: 440-3, 1984.
22. Burring KF, Kastendieck H. Ultrastructural observations on the histogenesis of localized fibrous tumours of the pleura (benign mesothelioma). *Virchows Arch A Pathol Anat Histopathol* 403: 413-24, 1984.
23. Dardick I, Srigley JR, McCaughey WT, van Nostrand AW, Ritchie AC. Ultrastructural aspects of the histogenesis of diffuse and localized mesothelioma. *Virchows Arch A Pathol Anat Histopathol* 402: 373-88, 1984.