

1-1-2003

Subtalar Dislocations: a Report of Two Cases

ÖZCAN PEHLİVAN

CAN SOLAKOĞLU

İBRAHİM AKMAZ

Follow this and additional works at: <https://journals.tubitak.gov.tr/medical>



Part of the [Medical Sciences Commons](#)

Recommended Citation

PEHLİVAN, ÖZCAN; SOLAKOĞLU, CAN; and AKMAZ, İBRAHİM (2003) "Subtalar Dislocations: a Report of Two Cases," *Turkish Journal of Medical Sciences*: Vol. 33: No. 2, Article 9. Available at: <https://journals.tubitak.gov.tr/medical/vol33/iss2/9>

This Article is brought to you for free and open access by TÜBİTAK Academic Journals. It has been accepted for inclusion in Turkish Journal of Medical Sciences by an authorized editor of TÜBİTAK Academic Journals. For more information, please contact academic.publications@tubitak.gov.tr.

Özcan PEHLİVAN
Can SOLAKOĞLU
İbrahim AKMAZ

Subtalar Dislocations: a Report of Two Cases

Department of Orthopedics and
Traumatology, Gülhane Military Medical
Academy, Haydarpaşa Training Hospital,
Istanbul - Turkey

Received: October 14, 2002

Key Words: subtalar, dislocation

Subtalar dislocations are not common and account for approximately 1% of all dislocations (1-5). This kind of dislocation is named according to the direction of the foot in relationship to the talus. Medial dislocation is the commonest type (85%) followed by lateral dislocation (15%). Anterior and posterior dislocations can also occur, but in a very small percentage of cases (2,3,6,7). In any types the talonavicular and talocalcaneal joints are involved simultaneously while tibiotalar and calcaneocuboid articulations remain intact (2,5,7). Associated osteochondral fractures are not uncommon (1,5,8).

Case Reports

Case One

A 20-year-old man was brought to the emergency room after an acute injury to his left foot while playing basketball. Physical examination revealed that the foot was completely displaced medially and the head of the talus was palpable and visible with the overlying skin on the dorsolateral aspect of the foot. The injury was closed and isolated. There was no accompanying neurovascular damage. Initial radiographs showed a medial peritalar dislocation without fracture, but an old fracture of the tuberosity of the tarsal navicular was observed (Figures 1a,b). A successful closed reduction was performed under general anesthesia in the operating room, and success was confirmed by image intensification. The foot was immobilized in a non-weightbearing short-leg cast. Computerized tomography (CT) scan evaluation revealed no occult fractures. Four weeks of immobilization was followed by cast removal, physiotherapy and progressive weightbearing. At the end of the sixth week full

weightbearing was permitted. At follow up evaluation 20 months later, the range of motion of the ankle joint was normal, but there was mild restriction of the movement of the subtalar joint. The patient complained of occasional mild pain at the lateral aspect of the foot when walking long distances. Radiographic evaluation showed no signs of avascular necrosis of the tarsal bones or posttraumatic arthritis.

Case Two

A 22-year-old man was exposed to an inversion injury to his left foot while he was walking downhill. He was referred to the emergency room 25 mins after the injury. His foot was swollen and partially medially displaced. The injury was closed and isolated. The head of the talus was palpable with the overlying skin. There was no neurovascular deficiency. Roentgenograms and CT scans taken before an attempt at reduction showed a medial peritalar dislocation with complete dislocation at the talonavicular joint and subluxation at the talocalcaneal joint. A fracture through the medial aspect of the talar head extending into the talonavicular joint was detected on CT scans (Figures 2a,b,c,d). In the operating room, under general anesthesia, manipulation for closed reduction was unsuccessful and open reduction was indicated. Surgical exposure was obtained through an incision over the talar prominence. The pathologic findings were buttonholing of the head of the talus through the extensor retinaculum and a fracture at the medial aspect of the talar head. The extensor retinaculum was incised and the head of the talus was reduced. Reduction of the fracture fragment was followed by fixation with three K-wires (Figures 3a,b). The foot was immobilized in a non-weightbearing short-leg cast for 6 weeks. By the end of the sixth week the cast and K-wires

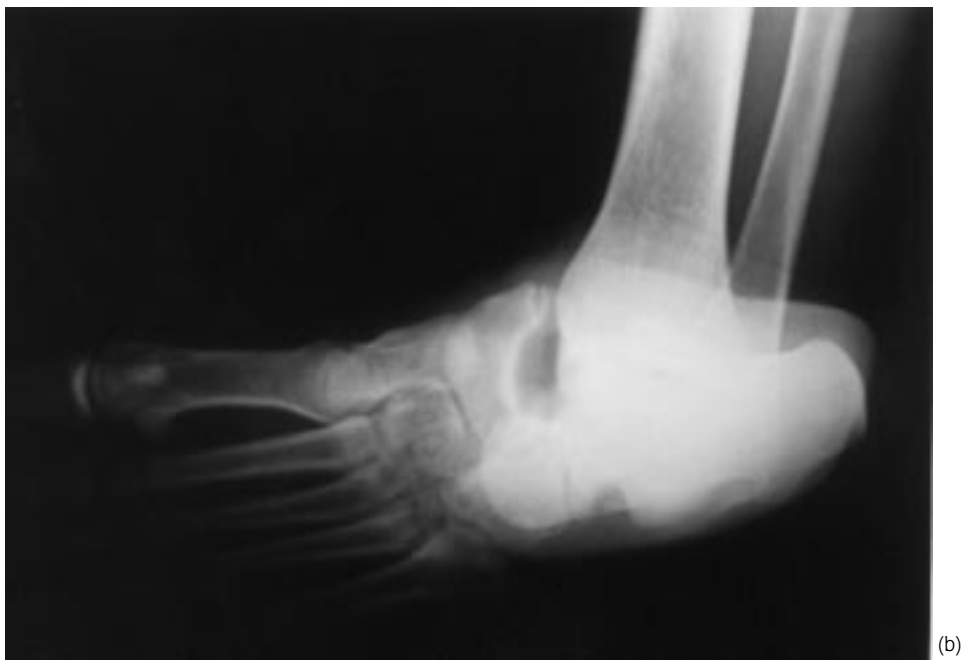
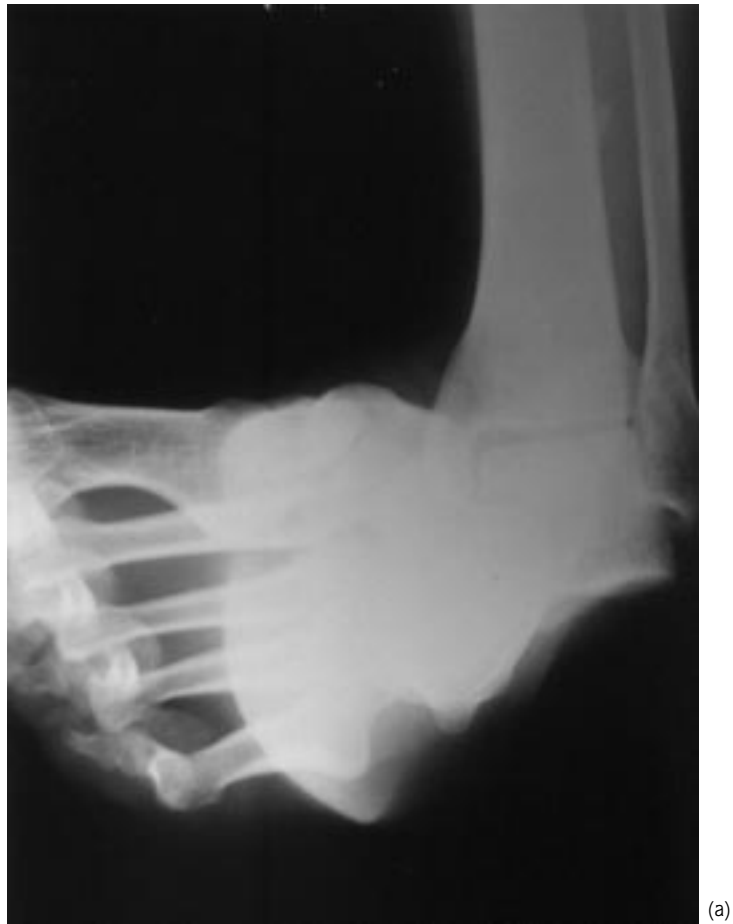
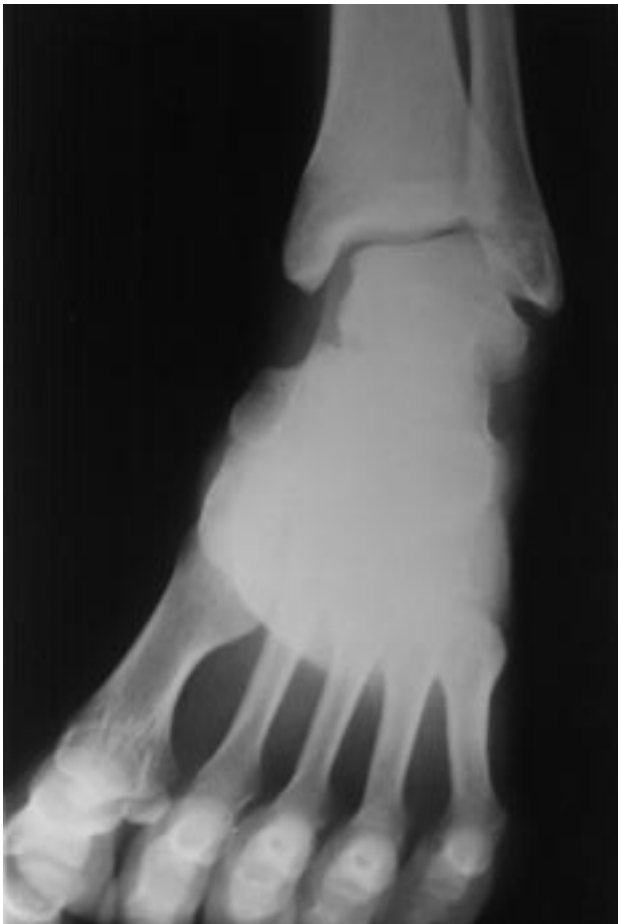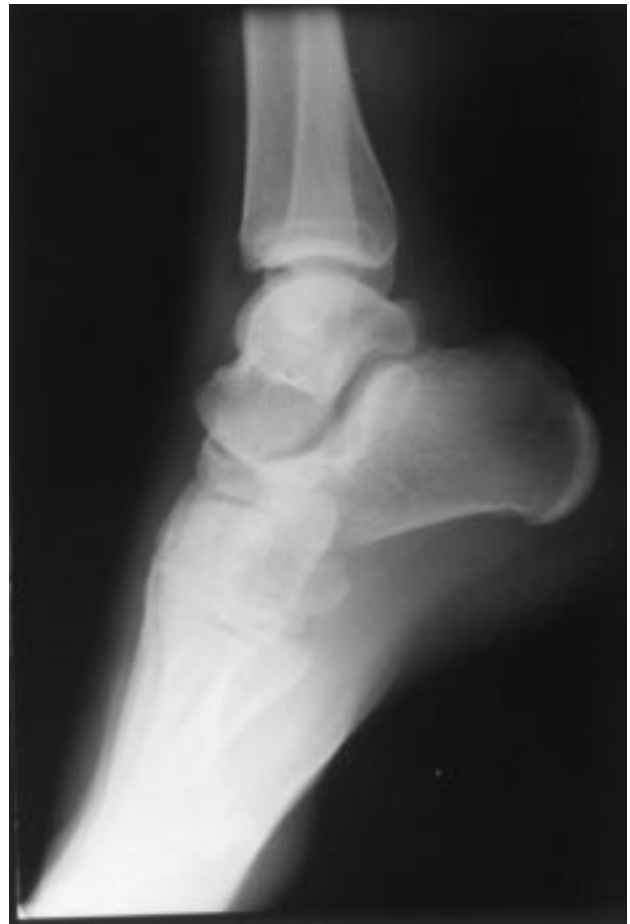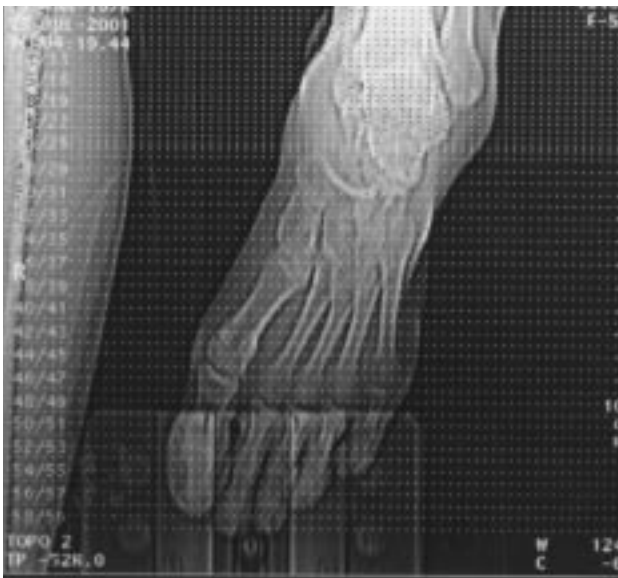Figure 1. Radiographs showing the complete dislocation of a) talocalcaneal and b) talonavicular joints.



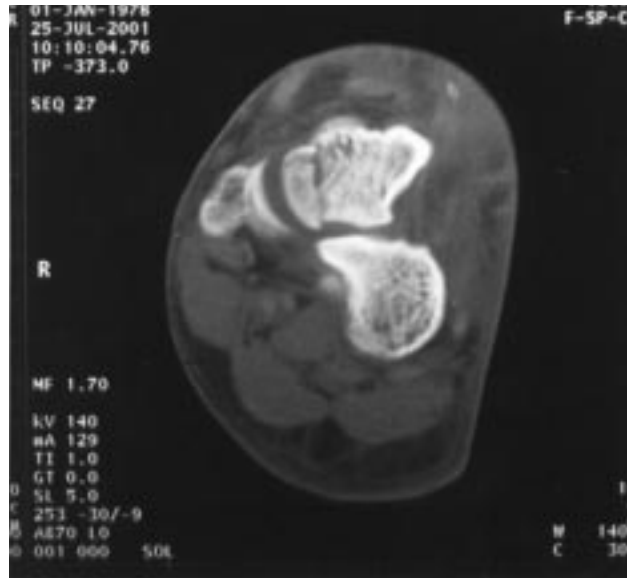
(a)



(b)



(c)



(d)

Figure 2. a) and b) radiographs showing talocalcaneal and talonavicular irregularity, c) and d) coronal CT topogram and scan showing the medial talonavicular dislocation and fracture at the medial side of the head of the talus.

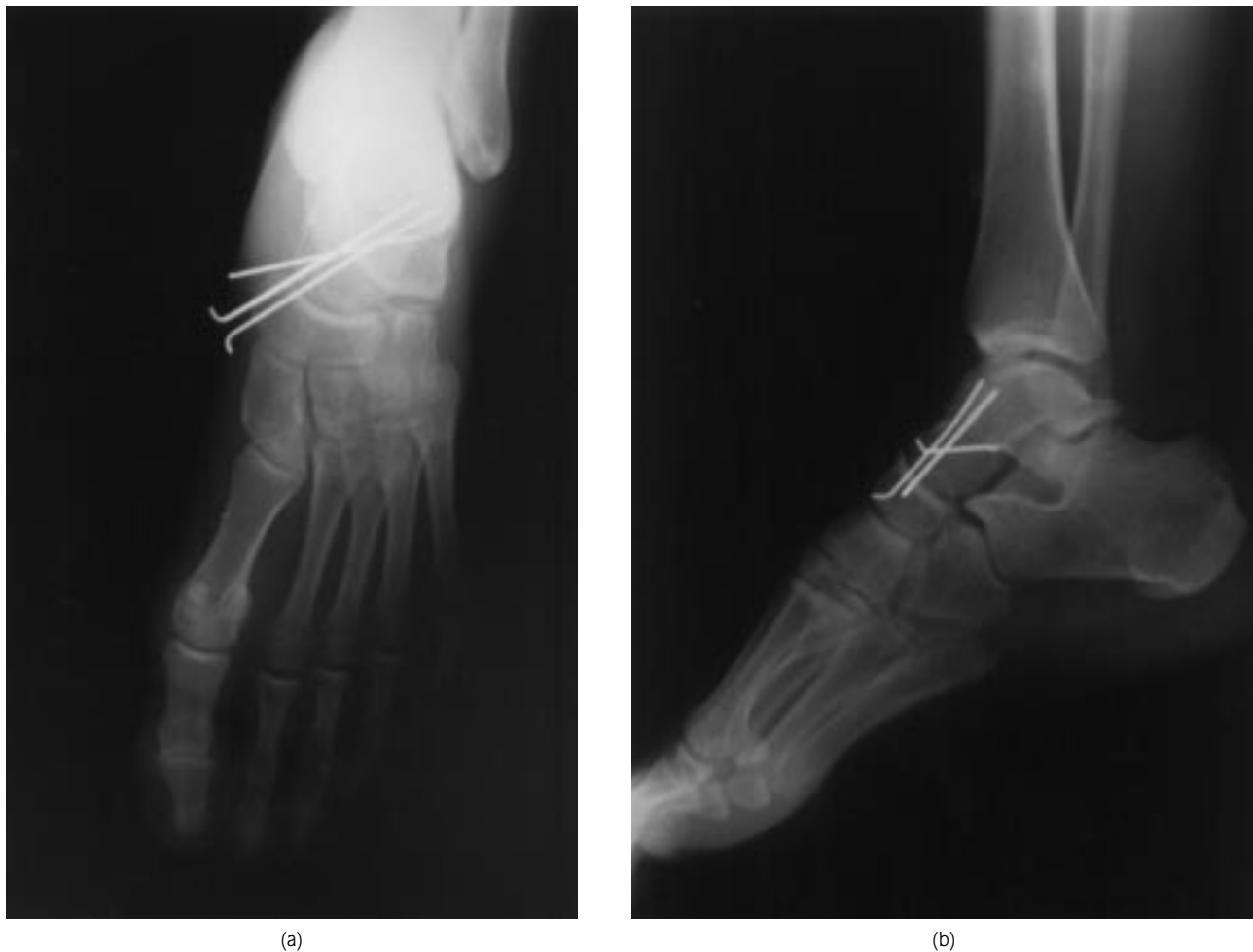

Figure 3. a) and b) radiographs after open reduction of peritalar dislocation and ORIF of the fracture of the head of the talus.

were removed without anesthesia, followed by physiotherapy and progressive weightbearing. At the end of the eighth week full weightbearing was permitted. The patient was monitored for 26 months. At the last follow-up examination he was currently pain-free in his daily activities, but he had mild to severe pain on the lateral side of the foot when walking long distances and at the forced inversion of the foot. There was no limitation of movement of the ankle joint, but the range of motion of the subtalar joint was diminished by 25% compared with the right side. There was no radiographic evidence of arthritis or avascular necrosis of the tarsal bones.

Discussion

Medial peritalar dislocation most commonly occurs by a severe inversion of the foot. The sustentaculum tali act

as a fulcrum causing first talonavicular dislocation, followed by talocalcaneal dislocation (2,4-7). Lateral dislocation is a result of a severe eversion force. The anterior calcaneal process acts as a fulcrum, causing subtalar dislocation first and talonavicular dislocation last (2,4,6).

Associated fractures of the tarsal bones, the base of the fifth metatarsal, and both malleoli are common with peritalar dislocations. The frequency of tarsal bone fractures varies from 20 to 60%, with lateral and open types being more likely to contain a fracture (2,4-8). In case one presented in this report, a rare condition of pure medial peritalar dislocation, without fracture, was treated.

Dislocation must be reduced as soon as possible in order to avoid soft tissue and circulatory complications.

Closed reduction, under general anesthesia, is usually successful in the medial type of dislocation (1-7). In the case of unsuccessful closed reduction, open reduction is mandatory. The most common obstacles to closed reduction are buttonholing of the talar head through the extensor retinaculum or extensor digitorum muscle, interlocking osteochondral fractures in the talonavicular joint and interposition of extensor digitorum brevis muscle (2-5,7). To our knowledge there have been no reports of the buttonholing of the talar head accompanied by osteochondral fracture of the head of the talus, as presented in this report in case two.

Complications in peritalar dislocations depend on the type and severity of the dislocation. Lateral or open dislocations have more chance of complications (1-3,7). Early complications in peritalar dislocations are skin necrosis, deep infection and neurovascular compromise. The frequency of these complications varies from 0.0 to 10%. Therefore, early diagnosis and accurate reduction are essential to avoid these early complications (2-4). Late complications include avascular necrosis of the tarsal bones, osteoporosis and posttraumatic arthritis. Avascular necrosis is a very rare condition and

osteoporosis is related to long-term of immobilization (2,4). Among the late complications the most common is posttraumatic arthritis, which causes pain and restriction of the subtalar joint movements (1,2,7). Dislocations with associated intra-articular fractures would likely result in arthritic changes causing varying degrees of stiffness of the subtalar joint. It has been reported that intra-articular fractures involving talocalcaneal or talonavicular joints can cause a significant amount of subtalar arthrosis (2,7,8). In order to minimize the degree of stiffness of the subtalar joint and related symptoms, uncomplicated medial subtalar dislocations should not be immobilized longer than 4 weeks and immobilization of dislocations with an associated fracture should not exceed 6 weeks. Immobilization should be followed by immediate mobilization, physiotherapy and full weightbearing (2,4,7).

Correspondence author:

Özcan PEHLİVAN

İlyas Bey Caddesi, No: 49/51 D.5

34310 Yedikule, İstanbul - Turkey

References

1. Bak K, Koch SS. Subtalar dislocation in a handball player. *Br J Sports Med* 25(1): 24-5, 1991.
2. Freund KG. Subtalar dislocations: a review of the literature. *J Foot Ankle Surg* 28(5): 429-32, 1989.
3. Heck BE, Ebraheim NA, Jackson WT. Anatomical considerations of irreducible medial subtalar dislocation. *Foot Ankle Int* 17(2): 103-6, 1996.
4. Marcinko DE, Zenker CC. Peritalar dislocation without fracture. *J Foot Ankle Surg* 30(5): 489-93, 1991.
5. Pierre RKST, Velazco A, Fleming LL, Whitesides T. Medial subtalar dislocation in an athlete: a case report. *Am J Sports Med* 10(4): 240-4, 1982.
6. Kınık H, Oktay O, Arıkan M, Mergen E. Medial subtalar dislocation. *Int Orthop* 23: 366-7, 1999.
7. Merianos P, Papagiannakos K, Hatzis A, Tsafantakis E. Peritalar dislocation: a follow-up report of 21 cases. *Injury* 19: 439-42, 1988.
8. Bohay DR, Manoli A. Occult fractures following subtalar joint injuries. *Foot Ankle Int* 17(3): 164-9, 1996.