

1-1-2003

## Benign Localized Fibrous Tumor of the Pleura: Report of three cases and a review of the literature

NİHAL KILINÇ

ALİ KEMAL UZUNLAR

Follow this and additional works at: <https://journals.tubitak.gov.tr/medical>



Part of the [Medical Sciences Commons](#)

---

### Recommended Citation

KILINÇ, NİHAL and UZUNLAR, ALİ KEMAL (2003) "Benign Localized Fibrous Tumor of the Pleura: Report of three cases and a review of the literature," *Turkish Journal of Medical Sciences*: Vol. 33: No. 6, Article 6. Available at: <https://journals.tubitak.gov.tr/medical/vol33/iss6/6>

This Article is brought to you for free and open access by TÜBİTAK Academic Journals. It has been accepted for inclusion in Turkish Journal of Medical Sciences by an authorized editor of TÜBİTAK Academic Journals. For more information, please contact [academic.publications@tubitak.gov.tr](mailto:academic.publications@tubitak.gov.tr).

## Benign Localized Fibrous Tumor of the Pleura: Report of three cases and a review of the literature

Nihal KILINÇ, Ali Kemal UZUNLAR

Department of Pathology, Faculty of Medicine, Dicle University, Diyarbakır - Turkey

Received: May 16, 2003

**Key Words:** Solitary fibrous tumor, Pleura.

Localized fibrous tumors (LFTs) of the pleura are an uncommon soft tissue tumor initially reported in the pleura but recently described in other sites in the body (1). Previously these tumors were mostly classified as localized mesotheliomas of the pleura, either benign or malignant (2). The morphological distinction between benign and malignant LFT is often difficult. An immunohistochemical study was performed in pleural and extrapleural sites (1,2). There was no clear relationship to asbestos exposure. This neoplasm originates from pluripotential mesenchymal cells located in the subserosal connective tissue (3). On average it measures 5 to 6 cm in diameter (4). Over 600 cases of LFT of the pleura have been reported worldwide (5).

We report 3 LFTs of the pleura and review the literature with particular attention to the clinical presentation and histopathologic characteristics of these tumors.

### Case Report

**Case 1:** A 57-year-old man presented with progressively increasing shortness of breath. A chest roentgenogram showed the presence of a mass of homogeneous density in the right hemithorax (Figure 1) and magnetic resonance of the chest confirmed the mass to be homogeneous in density in the right hemithorax (Figures 2a and b). Grossly the tumor was a solitary

lobulated mass covered by a smooth glistening capsule and with a broad base pedicle. The tumor measured 22 x 19 x 15 cm and weighed 2650 g (Figure 3). On histologic examination the tumor was composed of uniform collagen-forming spindle cells, which were accompanied by the deposition of abundant collagen, and there was no mitotic activity. Some areas had myxoid changes and hyalinization. The patient was doing well at 3-year follow-up.

**Case 2:** A 43-year-old man presented with chest pain, weight loss and a chest mass for nearly 6 weeks. PA and lateral chest roentgenograms showed the presence of a mass in the right hemitorax attached to the diaphragm. Grossly the tumor had a capsule and some areas had myxoid changes and hyalinization. The tumor measured 17 x 17 x 8 cm and weighed 2120 g. The cut surface had a nodular, firm, gray-white appearance, and small cysts and areas of hemorrhage (Figure 4). On histologic examination the tumor was composed of uniform spindle cells, which were arranged in interlacing fascicles and accompanied by the deposition of abundant collagen, and showed no mitotic activity (Figure 5). The tumor was resected. The patient was followed for about 4 years after surgical excision. There were no complications or recurrence.

**Case 3:** A 68-year-old women presented with cough and dyspnea. There was no history of exposure to asbestos. Her chest radiograph showed the presence of a

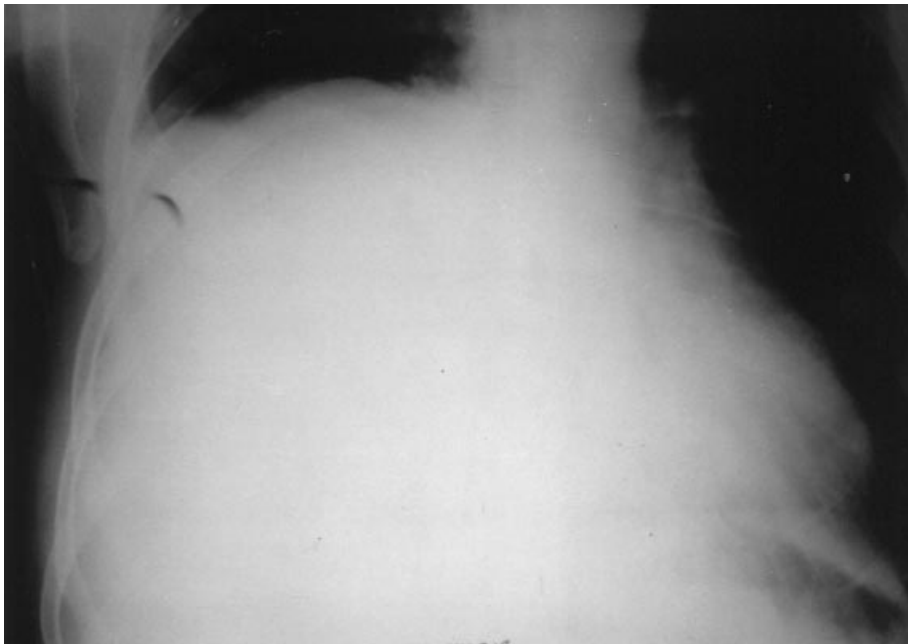


Figure 1. Preoperative chest roentgenogram shows mass involving right hemithorax.

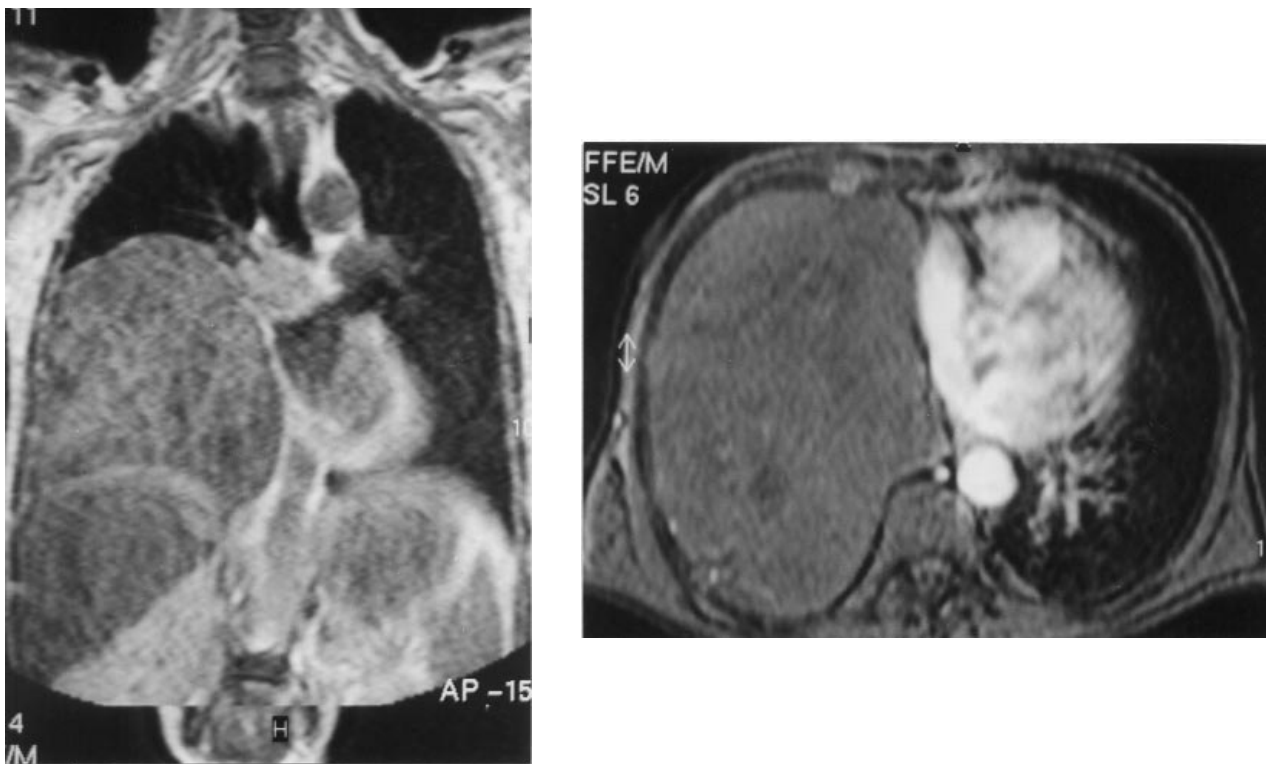

Figure 2. Axial (A) and coronal (B) T1 weighted magnetic resonance imaging of the chest shows a mass homogeneous in density in the right hemithorax.

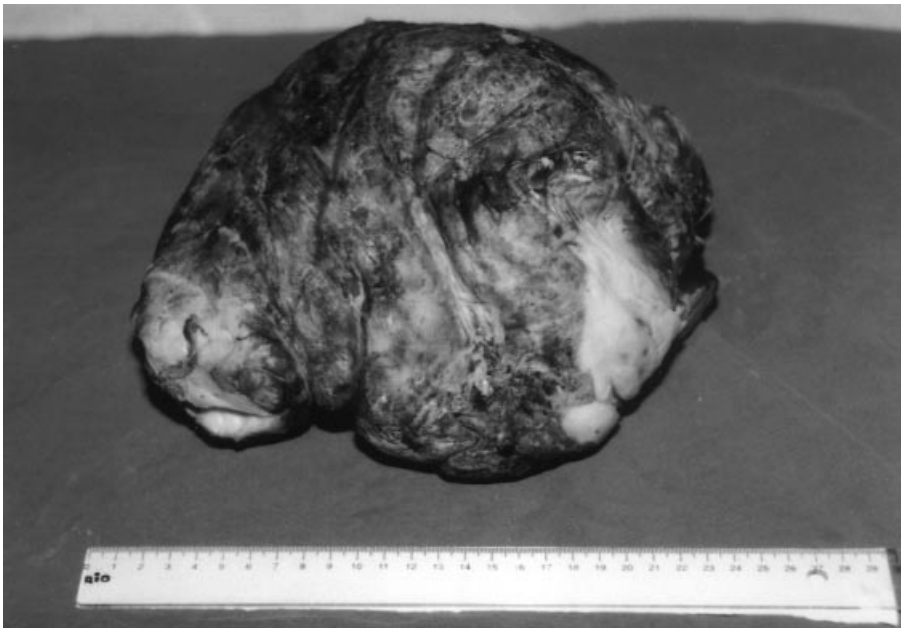

Figure 3. Grossly, a solitary lobulated mass covered by a smooth glistening capsule.

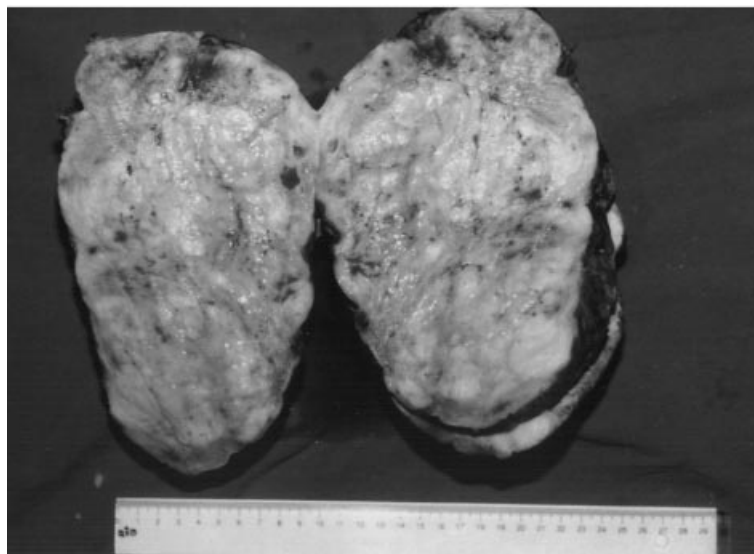

Figure 4. The cut surface showing a nodular, firm and gray-white appearance.

mass throughout the thorax. The tumor measured 17 x 15 x 15 cm and weighed 1340 g. On histologic examination the tumor had a combination of fibroblast-like cells and was accompanied by wirelike bands of collagen. Some areas had myxoid changes and hyalinization. Immunoreactivity for vimentin was

observed (Figure 6). The previous symptoms disappeared after resection. There was no evidence of any complaint 2 years after resection.

In all of our cases, hemogram and biochemical findings were normal and the cellularity of tumors varied

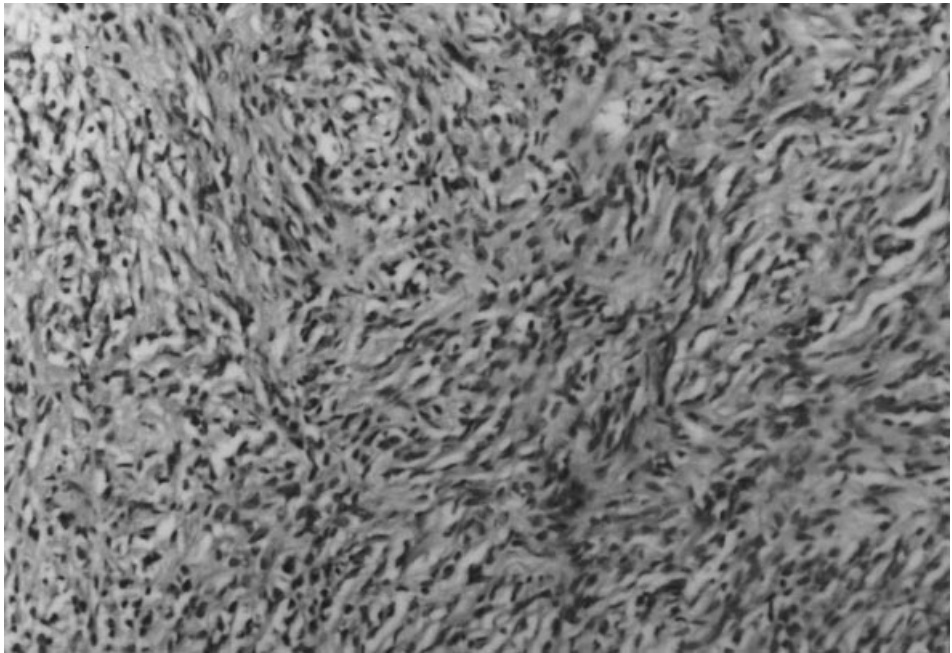


Figure 5. Benign localized fibrous tumor of the pleura. Interlacing fascicles showing tightly packed spindle cells (HE, x200).

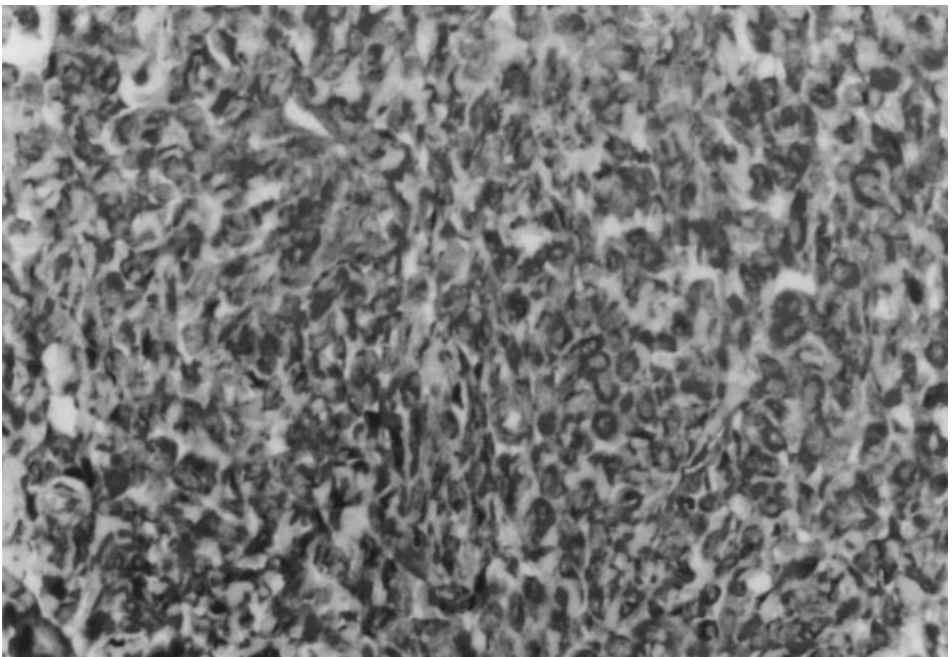


Figure 6. Vimentin immunoreactivity in the cytoplasm of many spindle tumor cells (labeled streptavidin biotin method, x400).

from area to area. There was no history of exposure to asbestos whether occupational or environmental. The totally resected tumors were examined histologically and immunohistochemically. There was no mitotic activity. All

cases expressed vimentin and CD34. However, there was no immunoreactivity with antibodies to cytokeratins, desmin, epithelial membrane antigen, smooth muscle actin, S100 or factor VIII. The pathological diagnosis all

of the tumors was benign LFT of the pleura. We observed no recurrence in the long-term follow-up.

Benign solitary fibrous tumors, previously called benign mesotheliomas, are an uncommon tumor first reported in the pleura, but recently described in other tissues, with approximately 600 cases reported in the literature (5,6). The localized form of the fibrous tumors is usually considered benign, but malignant variants of these localized tumors have been reported (7,8). The benign variant is 3 to 4 times as common as the malignant one (9). These tumors have a slightly higher incidence in females than in males. The peak incidence is in the fourth to sixth decade of life (10).

The usual presentation is an asymptomatic mass discovered incidentally on a chest radiograph (5). However, cough, chest pain, dyspnea and clubbing are seen in 30% of patients and are more common with tumors larger than 10 cm and those with malignant cellular features (5,11). At the time of surgery our patients were symptomatic. Because of the release of insulinlike peptide, hypoglycemia occurs in about 5% of solitary fibrous tumors of the pleura, especially large ones (4). The blood glucose levels of the 3 patients were normal.

Unlike the malignant form, benign localized fibrous tumors of the pleura appear to be unrelated to asbestos exposure, but rare instances of this association have been described (4). There was no asbestos exposure whether occupational or environmental in our cases. Eighty percent originate from the visceral pleura and 20% from the parietal pleura (2,9).

Tumors range in size from 1 cm to a massive tumor measuring 39 cm and weights range from 12 to 3,800 g (12). These tumors are usually less than 10 cm in size and are pedunculated (5). Grossly the tumor manifests as a solitary localized mass attached via a richly vascularized pedicle and a broad base to the parietal pleura, and is covered by a smooth glistening capsule (5). The cut surface has a uniform or nodular, firm, gray-white mass with a characteristic whorled appearance or shows a variegated picture with alternating firm and soft myxoid areas, sometimes with cystic spaces and areas of hemorrhage (4).

Although most solitary fibrous tumors are benign, up to 13% of the localized tumors can have malignant characteristics and a more aggressively fatal course (9).

The malignant variants can be recognized by their greater cellularity, cellular pleomorphism, and increased mitotic activity, usually more than 4 mitotic figures per 10 high-power fields (4). There were no mitotic figures in our 3 cases.

Infrequently a pleural effusion may be present. England et al. (12) reported that patients had a pleural effusion. We did not encounter pleural effusion at the time of surgery. The differential diagnosis of benign tumors can be uncomplicated, but atypical variants and malignant forms require the exclusion of other tumors included in the broad array of spindle cell neoplasms that can arise in or extend to a serosal surface. Electron microscopy is useful, but immunostaining procedures offer more extensive and reliable help in reaching the correct diagnosis (13).

There are a number of antigens that are useful in identifying LFT. Previous studies have reported that all cases of LFT were positive for vimentin and CD34. On the other hand, it is only occasionally positive for actin, desmin and alpha-1-antichymotrypsin. In contrast, it is always negative for cytokeratin, CD31, factor VIII, alpha-1-antitrypsin, carcinoembryonal antigen, neurofilament, neuroendocrine markers, synaptophysin and S-100 protein (10,14). Malignant mesothelioma is reactive for cytokeratin and negative for CD34, demonstrating that it has completely opposite characteristics from those of the localized benign fibrous tumor of the pleura. In our 3 cases this analysis was performed and the patients were immunopositive for CD34. More cellular types of fibrous mesothelioma must be distinguished from LFT. The immunohistochemical tests may be useful for distinguishing LFT from malignant mesothelioma.

Among these forms, high cellularity and microvessel density, high expression of Ki 67 and CD31 and negativity of CD34 are prognostic factors for a poor prognosis. All our cases expressed vimentin and CD34.

Treatment of benign fibrous tumors of the pleura consists of adequate local excision. Great care must be taken during surgery because of the highly vascular pedicle (15). The overall operative mortality is reported at 12% because of hemodynamic changes associated with decompressing the mediastinal structures (9).

Although most tumors are considered histologically benign, 10-30% locally recur or metastasize. Pathogenic

factors relevant to the determination of their biological properties are largely unknown (16). Perrot et al. (17) reported a case that recurred with fibrosarcomatous features 6 years after complete resection. In addition, local recurrence has been reported as late as 17 years after surgical excision (7). Survival is directly related to whether the tumor can be resected completely and the presence of malignant changes histologically (5). Long-term annual follow-up with chest roentgenograms is highly recommended (17). After 3-year follow-up, our patients were healthy and have no signs of recurrence.

Finally, the prognosis of fibrous tumor of pleura is generally good. These neoplasms are cured by surgical excision.

*Correspondence author:*

*Nihal KILINÇ*

*Department of Pathology*

*Faculty of medicine, Dicle University*

*21280, Diyarbakır - TURKEY*

*E-mail: nhl@dicle.edu.tr*

## References

1. Sun Y, Naito Z, Ishiwata T, et al. Basic FGF and Ki-67 proteins useful for immunohistological diagnostic evaluations in malignant solitary fibrous tumor. *Pathol Int* 53: 284-90, 2003.
2. Biçer M, Yaldız S, Gürsoy S, et al. A case of giant benign localized fibrous tumor of the pleura. *Eur J Cardiothorac Surg* 14:211-213,1998.
3. Bortolotti U, Calabrò F, Loy M, et al. Giant intrapericardial solitary fibrous tumor. *Ann Thorac Surg* 54: 1219-20, 1992.
4. Enzinger FM, Weiss WS. *Soft tissue tumors*. Third edition. Mosby, Missouri 810-813, 1995.
5. Khan JH, Rahman SB, Clary Macy C, et al. Giant solitary fibrous tumor of the pleura. *Ann Thorac Surg* 65: 1461-4, 1998.
6. Sawada N, Ishiwata T, Naito Z. Immunohistochemical localization of endothelial cell markers in solitary fibrous tumor. *Pathol Int* 52: 769-76, 2002.
7. Okike N, Bernatz PE, Woolner LB. Localized mesothelioma of the pleura: benign and malignant variants. *J Thorac Cardiovasc Surg* 75: 363-372, 1978.
8. De Perrot M, Fischer S, Brundler MA. Solitary fibrous tumors of the pleura. *Ann Thorac Surg* 74: 285-93, 2002.
9. Briselli M, Mark EJ, Dickersin OR. Solitary fibrous tumors of the pleura: eight new cases and review of 360 cases in the literature. *Cancer* 47: 2678-89, 1981.
10. Mezzetti M, Panigalli T, Giudice FL, et al. Surgical experience of 15 solitary benign fibrous tumor of the pleura. *Oncol Hematol* 47: 29-33, 2003.
11. Aribas OK, Gormus N, Kanat F, et al. Giant localized solitary fibrous tumors of the diaphragmatic pleura: report of two cases. *Surg Today* 32: 406-9, 2002.
12. England DM, Hochholzer L, McCarthy MJ. Localized benign and malignant fibrous tumors of the pleura: a clinicopathologic review of 223 cases. *Am J Surg Pathol* 13: 640-4, 1989.
13. Ordonez NG. Localized (solitary) fibrous tumor of the pleura. *Adv Anat Pathol* 7: 327-40, 2000.
14. Brozzetti S, D'Andrea N, Limiti MR. Clinical behavior of solitary fibrous tumors of the pleura. An immunohistochemical study. *Anticancer Res* 20: 4701-6, 2000.
15. Watts DM, Jones OP, Bowman GA, et al. Giant benign mesothelioma. *Ann Thorac Surg* 48: 590-1, 1989.
16. De Leval L, Defraigne JO, Hermans G. Malignant solitary fibrous tumor of the pleura: report of a case with cytogenetic analysis. *Virchows Arch* 442: 388-92, 2003.
17. Perrot M, Kurt AM, Robert JH, et al. Clinical behavior of solitary fibrous tumors of the pleura. *Ann Thorac Surg* 67: 1456-9, 1999.