

1-1-2004

A Morphometric Evaluation of Some Important Bony Landmarks on the Skull Base Related to Sexes

AYNUR EMİNE ÇİÇEKÇİBAŞI

KHALİL AWADH MURSHID

TANER ZİYLAN

MUZAFFER ŞEKER

IŞIK TUNCER

Follow this and additional works at: <https://journals.tubitak.gov.tr/medical>



Part of the [Medical Sciences Commons](#)

Recommended Citation

ÇİÇEKÇİBAŞI, AYNUR EMİNE; MURSHID, KHALİL AWADH; ZİYLAN, TANER; ŞEKER, MUZAFFER; and TUNCER, IŞIK (2004) "A Morphometric Evaluation of Some Important Bony Landmarks on the Skull Base Related to Sexes," *Turkish Journal of Medical Sciences*: Vol. 34: No. 1, Article 6. Available at: <https://journals.tubitak.gov.tr/medical/vol34/iss1/6>

This Article is brought to you for free and open access by TÜBİTAK Academic Journals. It has been accepted for inclusion in Turkish Journal of Medical Sciences by an authorized editor of TÜBİTAK Academic Journals. For more information, please contact academic.publications@tubitak.gov.tr.

CLINICAL INVESTIGATION

A Morphometric Evaluation of Some Important Bony Landmarks on the Skull Base Related to Sexes

Aynur Emine ÇİÇEKÇİBAŞI, Khalil Awadh MURSHED, Taner ZİYLAN, Muzaffer ŞEKER, Işık TUNCER
Department of Anatomy, Meram Faculty of Medicine, Selçuk University, Konya - Turkey

Received: August 14, 2003

Abstract: The purpose of this study is to evaluate the morphometric measurements of some important bony landmarks on the cranial base and to determine their relationships between the sexes and their bilateral differences.

In this study, 60 (34 male and 26 female) skulls were obtained from the teaching skeletal collections at the Anatomy Department of Meram Medical School, Selçuk University. The axial length of the occipital condyles (ALOC), the anterior intercondylar distance (AICD), the sagittal intercondylar angle (OICA), the transverse and sagittal diameters of the jugular foramen (TDJF) and (SDJF), the distance from the apex of the mastoid process to the outer border of the jugular foramen (MJ), the distance from the apex of the mastoid process to the outermost lateral point of the foramen magnum (MFM) and the distance from the apex of the mastoid process to the center of the external opening of the carotid canal (MCF) were measured by using a millimetric sliding caliper and a goniometer. Student's t- test was used to compare the male-female and right-left measurements. To determine the relationships between the studied parameters, Pearson correlation coefficients were calculated.

The results showed that the ALOC of both sides and the AICD parameters were significantly longer in males than in females ($P < 0.01$). Bilateral differences in the studied parameters showed that the measurements on the right side were significantly greater than those on the left in the MCF, MFM, SDJF and TDJF. Significant associations were found among some of the studied measurements.

We believe that the results of this study may be useful in cases of cranial base surgery, moreover a knowledge of the anatomical relationships and features of this region is very important for surgical approaches.

Key Words: Skull base, occipital condyles, jugular foramen, measurements

Introduction

Cranial base measurements and their importance have been estimated by various authors. The cranial base is such a complex structure that it is studied to be studied morphometrically. The distances between the anatomic landmarks and the sites where a number of vital structures have their entrances or exits are very important for clinical applications. Therefore, the assessment of these morphometrics is helpful for further lateral surgical approaches for reaching lesions in the middle and posterior parts of the cranial base. Part of the cranial base measurements was intended to improve different surgical approaches to the petrous carotid artery (1,2), the foramen magnum (3-5) and jugular foramen morphometrics (6,7). In other studies, cranial

base measurements were assessed for anthropometric and gender differences (8,9). The orientation of the cranial base plays an important role in growth and development, and thus the ultimate positioning of the various craniofacial components has been clearly illustrated in the literature (10-14). According to these authors, the floor of the cranium is the template on which the face is constructed (8). The length of the occipital condyles is of great surgical importance in performing a condylar resectos, as in the cases of identified tumors in the foramen magnum region and in improving techniques (5,15-17). Cranial base dimensional anatomy is essential to a quantitative distance evaluation of the structures in this complicated part of the skull and to facilitate the exposure of different foraminal regions.

The purpose of this study is to evaluate the morphometric measurements between some important bony landmarks on the cranial base and to determine their relationship to gender and bilateral differences.

Materials and Methods

Sixty (34 male and 26 female) skulls obtained from the teaching skeletal collections at the Anatomy Department of Meram Medical School, Selçuk University were used in this study. The determination of the skull sex was performed by considering the classic anatomic characteristics (Olivier, 1960; Testut and Latarjet, 1977; Gray, 1985). By using a millimetric sliding caliper the following parameters on both left and right were measured (Figure):

- The axial length of the occipital condyles (ALOC);
- The distance between the apex of the mastoid process and the center of the external opening of the carotid canal (MCF);
- The distance between the apex of the mastoid process and the outermost lateral point of the foramen magnum (MFM);
- The distance between the apex of the mastoid process and the outer border of the jugular foramen (fossa) (MJ);
- The sagittal diameter of the jugular foramen (fossa) on the outer surface of the skull base (SDJF);
- The transverse diameter of the jugular foramen (fossa) on the outer surface of the skull base (TDJF).

In addition to the abovementioned parameters, the anterior intercondylar distance (AICD) and the occipital intercondylar angle (sagittal condylar angle) (OICA) were measured. A goniometer was used for measuring the angle.

Student's t-test was applied to compare male-female and right-left measurements. To determine the relationships between the studied parameters, Pearson correlation coefficients were calculated.

Results

As shown in Table 1, the gender comparative results of the assessed parameters show that the left and right ALOCs were significantly longer in males than in females

($P < 0.05$) (Table 1). The AICD was also greater in males ($P < 0.05$) (Table 1). No significant differences were found in the other measurements ($P > 0.05$) (Table 1). Bilateral comparative results show that the MCF, MFM, SDJF and TDJF measurements were greater in the right side than in the left ($P < 0.05$) (Table 2).

The statistical comparisons of the correlations of all measured parameters are indicated in Table 3. Significant associations were found between the left MCF and both the right and left MJ ($r = 0.525$ and 0.688 , respectively) ($P < 0.01$). The same intercorrelations were found

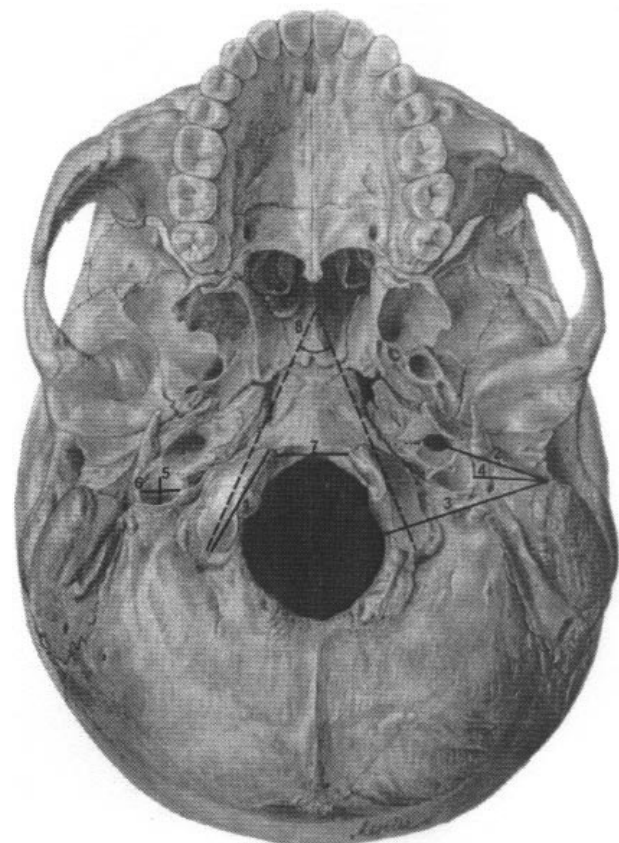


Figure 1. The measurements at the base of the skull: The axial length of the occipital condyles (1); The distance between the apex of the mastoid process and the center of the external opening of the carotid canal (2); The distance between the apex of the mastoid process and the outermost lateral point of the foramen magnum (3); The distance between the apex of the mastoid process and the outer border of the jugular foramen (fossa) (4); The sagittal diameter of the jugular foramen (fossa) on the outer surface of the skull base (5); The transverse diameter of the jugular foramen (fossa) on the outer surface of the skull base (6); The anterior intercondylar distance (7); The sagittal condylar angle (8).

Table 1. Maximum and minimum values of the measured parameters and gender comparative results (Mean \pm SD, t and P values).

PARAMETERS	Min (mm)	Max (mm)	MALES	FEMALES	t	P
			Mean \pm SD (mm)	Mean \pm SD (mm)		
ALOC – Left	18.3	31.0	24.82 \pm 2.43	23.17 \pm 1.89	2.483	0.017*
ALOC – Right	20.0	31.5	25.13 \pm 2.36	23.44 \pm 1.90	2.685	0.010*
MCF – Left	26.5	41.4	31.53 \pm 3.28	30.41 \pm 2.58	0.968	0.341
MCF – Right	26.5	42.0	31.83 \pm 3.52	30.55 \pm 2.59	1.068	0.294
MFM – Left	32.5	44.0	37.97 \pm 2.79	35.80 \pm 2.78	1.954	0.062
MFM – Right	32.5	44.5	38.37 \pm 2.70	37.82 \pm 3.59	0.477	0.637
MJ – Left	16.0	27.0	20.97 \pm 2.60	22.00 \pm 3.24	0.919	0.367
MJ – Right	17.0	27.2	21.00 \pm 3.29	20.64 \pm 3.11	0.300	0.766
SDJF – Left	5.0	10.7	6.83 \pm 1.60	6.75 \pm 1.44	0.137	0.892
SDJF – Right	6.0	11.9	7.61 \pm 1.37	7.91 \pm 0.89	0.657	0.516
TDJF – Left	7.5	18.5	12.61 \pm 1.74	12.11 \pm 1.52	0.859	0.397
TDJF – Right	7.9	18.0	12.91 \pm 1.89	12.88 \pm 1.65	0.050	0.960
AICD	10.5	20.3	16.09 \pm 1.93	14.68 \pm 1.80	2.510	0.016*
OICA (Degrees)	40°	74°	55.83 \pm 9.00	57.63 \pm 8.14	0.758	0.452

* P < 0.05

Table 2. Bilateral comparative results of the measured parameter (Mean \pm SD, t and P values).

PARAMETERS	LEFT	RIGHT	t	P
	Mean \pm SD	Mean \pm SD		
ALOC	24.01 \pm 2.31	24.36 \pm 2.32	1.942	0.059
MCF	31.19 \pm 3.18	31.83 \pm 3.20	2.186	0.038*
MFM	37.04 \pm 2.67	38.28 \pm 3.30	2.741	0.012*
MJ	21.26 \pm 2.94	21.16 \pm 3.22	0.236	0.815
SDJF	6.69 \pm 1.45	7.71 \pm 1.29	2.661	0.014*
TDJF	12.41 \pm 1.66	13.00 \pm 1.84	2.079	0.047*

* P < 0.05

among the right MCF and both the right and left MJs ($r = 0.635$ and 0.688 , respectively) ($P < 0.01$). A significant association was also determined between the right and left MFMs ($r = 0.755$) ($P < 0.01$). The same intercorrelation was found between the right and left MCFs ($r = 0.893$) ($P < 0.01$). The right and the left MJs were significantly associated with each other ($r = 0.767$) ($P < 0.01$). The right and left TDJFs were also

intercorrelated with each other ($r = 0.628$) ($P < 0.01$). A significant association was also found between the right and left ALOCs ($r = 0.870$) ($P < 0.01$). Moderate significant associations were found between the left SDJF and the right TDJF ($r = 0.448$) ($P < 0.05$) and between the right ALOC and the left MFM ($r = 0.425$) ($P < 0.05$). In the other correlations, no significant associations were found ($P > 0.05$).

Table 3. Correlation coefficients (r) between the measured parameters.

	TDJF-R	TDJF-L	SDJF-R	SDJF-L	OICA	MJ-R	MJ-L	MFM-R	MFM-L	MCF-R	MCF-L	ALOC-R	ALOC-L
AICD	0.157	0.262	0.143	0.002	0.164	0.194	0.227	0.113	0.153	0.228	0.168	0.151	0.107
ALOC-L	0.304	0.247	0.150	0.286	0.253	0.114	0.065	0.135	0.369	0.028	0.119	0.870**	
ALOC-R	0.118	0.270	0.170	0.380	0.120	0.300	0.179	0.186	0.425*	0.172	0.020		
MCF-L	0.207	0.282	0.130	0.105	0.037	0.525**	0.688**	0.028	0.134	0.893**			
MCF-R	0.020	0.127	0.040	0.058	0.082	0.635**	0.688**	0.130	0.347				
MFM-L	0.134	0.001	0.212	0.114	0.119	0.349	0.265	0.755**					
MFM-R	0.170	0.236	0.244	0.091	0.104	0.178	0.037						
MJ-L	0.189	0.198	0.098	0.019	0.065	0.767**							
MJ-R	0.237	0.001	0.048	0.367	0.270								
OICA	0.126	0.126	0.028	0.347									
SDJF-L	0.448*	0.181	0.065										
SDJF-R	0.117	0.049											
TDJF-L	0.628**												

* P < 0.05

** P < 0.01

Discussion

This study was conducted to provide information on the gender and bilateral morphological differences in the floor of the skull.

The significantly greater axial length of the left and right occipital condyles (ALOC-L, ALOC-R) in males can be interpreted as the presence of an intercorrelation between this parameter on both sides and the sagittal and transverse diameters of the foramen magnum, which were reported to be significantly greater in males than in females (21). This correlation is probably due to the morphometrical and structural relationships between the occipital condyles and the foramen magnum. The dimensions of the foramen magnum and the axial and antero-posterior lengths of the occipital condyles are very important factors. They should be considered for surgical exposure, such as in cases of tumor resection from the foramen magnum area (22). Lang (23) reported that the axial length of the occipital condyle on the right ranged from 15 to 27 mm, with an average of 22.9 mm, whereas on the left, it ranged from 15 to 29 mm, with a mean value of 22.9 mm. Our results showed that on the right this ranged from 20 to 31.5 mm, with an average of 24.36 mm, whereas on the left it ranged from 18.3 to

31 mm, with a mean value of 24.0 mm. The differences between the results are possibly due to racial variations in the cranial morphometrics of the 2 different studied populations. However, the nonsignificant difference between the right and left axial lengths of our studied samples agree with those obtained by Lang (23), who did not find significant bilateral differences in his samples.

In the present study, the results showed a significant difference between males and females in the AICD (P < 0.05). This can be considered as another possible explanation of the intercorrelation between the significantly greater dimensions of the foramen magnum in males (21) and the significantly wider anterior intercondylar distance that we found in this study. According to Lang (23), this parameter ranged from 16 to 30 mm, with a mean value of 23.6 mm. In our study, this parameter ranged from 10.5 to 20.3 mm, with a mean value of 15.4 mm (when the mean values in males and females are combined). The differences between these values were due to the differences in the method of measuring the AICD, in which we measured the distance between the anterior inner points of the occipital condyles, while in Langs (23) method, the distance was measured between the anterior circumferences of the

condyles. As a result of the 2 assessment methods, our results are smaller than those obtained by Lang (23). No significant difference between males and females was found in the OICA ($P > 0.05$). In our results, this angle ranged from 40 to 74°, with an average value of 56.7° (when the mean values in males and females are combined). In his study, Lang (23) reported that this angle ranged from 30 to 77°, with a mean value of 51.4°. The occipital condyles represent the cranial portion of the craniocervical junction and they form the articular surface of the atlas so that the axial lengths of the right and the left occipital condyles, the AICD and the OICA are of great dimensional importance, especially during the exposure of the vertebral artery and the resection of the occipital condyles, as in cases of transcondylar surgical approaches to reach the lesions at the ventrolateral clivus and jugular foramen (5, 24-27).

Several studies were performed on the measurements of the paramedian distances between the bony landmarks related to neurovascular routes at the base of the cranium (28-30). In the present study, we considered the apex of the mastoid process as a reference point from which the distances to the carotid foramen, the jugular fossa and the foramen magnum were measured in addition to the other studied measurements. In these measurements, we did not find any differences between males and females ($P > 0.05$) (Table 1). Sex differences were not seen in the transverse and sagittal diameters of the jugular foramen ($P > 0.05$) (Table 1). According to Lang (23), the distance between the outer border of the jugular fossa and the apex of the mastoid process was 23 mm. In our findings, this distance was 21.2 ± 3.1 mm (when the mean distances on the right and the left sides are combined). In this case, we can say that the 2 results are similar. In this measurement, no bilateral significant difference was found ($P > 0.05$) (Table 2). Lang et al. (29) and Lang and Schreiber (31) previously studied the dimensions of the jugular foramen and reported that the sagittal and transverse diameters were 9 and 17 mm, respectively. According to Ekinci and Unur (6), the sagittal and transverse diameters of the left jugular foramen were 7.6 and 15.5 mm, respectively, and on the right 8.4 and 16 mm, respectively. In our study, the sagittal and transverse dimensions of the left jugular foramen were 6.7 ± 1.5 mm and 12.4 ± 1.7 mm,

respectively, and on the right they were 7.7 ± 1.3 mm and 13 ± 1.8 mm, respectively. When the mean values of both sides were combined, these dimensions were 7.2 ± 1.4 mm and 12.7 ± 1.8 mm for the sagittal and transverse diameters, respectively. Further studies are recommended to clarify the speculation on the transverse diameter of the jugular foramen. Lang (23) stated that in most cases the width of the right jugular foramen is greater than that of the left, but there is no difference in respect of length. Ekinci and Unur (6) reported that the jugular foramen on the left side was longer in the transverse diameter, and that the right was jugular foramen longer in the sagittal diameter. In our samples, both diameters of the right jugular foramen were found to be significantly greater than those of the left ($P < 0.05$) (Table 2). Bilateral comparative results of the distances between the apex of the mastoid process and of both the MCF and MFM showed that the measurements on the right side were significantly greater than those on the left ($P < 0.05$) (Table 2). The significant correlations between the left and right mastoid – carotid foramina distances (MCF-L) (MCF-R), and left and right mastoid–jugular fossae distances (MJ-L) (MJ-R) ($P < 0.05$) (Table 3) indicate that bilateral increments in the former dimensions are accompanied by bilateral increments in the latter, and vice versa (Table 3). The same correlations were seen between the axial lengths of the bilateral occipital condyles, the transverse diameters of the bilateral jugular fossae, the bilateral mastoid–carotid foramina distances, the bilateral mastoid–jugular fossae distances, and the bilateral mastoid–foramen magnum distances ($P < 0.05$) (Table 3).

We conclude that the results of the present study can be useful in cranial base surgery and that a knowledge of the anatomical features of this region is very important for surgical approaches.

Corresponding author:

Aynur Emine ÇİÇEKÇİBAŞI

Selçuk University, Meram Faculty of Medicine

Department of Anatomy 42080 Konya – TURKEY

E mail: cicekbasi@hotmail.com

References

1. Villavicencio AT, Leveque JC, Bulsara KR et al. Three-dimensional computed tomographic cranial base measurements for improvement of surgical approaches to the petrous carotid artery and apex regions. *Neurosurgery* 49: 352-3, 2001.
2. Aslan A, Balyan FR, Taibah A et al. Anatomic relationships between surgical landmarks in type b and type c infratemporal fossa approaches. *Eur Arch Otorhinolaryngol* 255: 259-64, 1998.
3. Spektor S, Anderson GJ, McMenomey SO et al. Quantitative description of the far-lateral transcondylar transtuberular approach to the foramen magnum and clivus. *J Neurosurg* 92: 824-31, 2000.
4. Cornu P, Hentati K, Chabolle F et al. Lateral approach to the foramen magnum. *Surg Radiol Anat* 12: 77-8, 1990.
5. Dowd GC, Zeiller S, Awasthi D. Far lateral transcondylar approach: Dimensional anatomy. *Neurosurgery* 45: 95-9, 1999.
6. Ekinci N, Unur E. Macroscopic and morphometric investigation of the jugular foramen of the human skull. *Kaibogaku Zasshi* 72: 525-9, 1997.
7. Schwaber MK, Netteville JL, Maciunas R. Microsurgical anatomy of the lower skullbase - a morphometric analysis. *Am J Otol* 11: 401-5, 1990.
8. D'Aloisio D, Pangrazio-Kulbersh V. A comparative and correlational study of the cranial base of North American blacks. *Am J Orthod Dentofacial* 102: 449-55, 1992.
9. Rude J, Mertzluft O. Correlation coefficients in human skulls: Significant sexual differences. *Anthropologischer Anzeiger* 45: 371-5, 1987.
10. Enlow DH. *Handbook of facial growth*, 2nd ed. WB Saunders. Philadelphia 1982.
11. Jarabak JR, Fizzell JA. *Technique and treatment with light-wire edgewise appliances*, 2nd ed. CV Mosby. St. Louis 1972.
12. Bjork A. Cranial base development. *Am J Orthod* 41: 1982-5, 1955.
13. Bjork A. Facial growth in man, studied with the aid of metallic implants. *Acta Odont Scand* 13: 9-18, 1955.
14. Bjork A. Some biological aspects of prognathism and occlusion of the teeth. *Acta Odontol Scand* 8: 1-40, 1950.
15. Day JD, Fukushima T, Giannotta SL. Cranial base approaches to posterior circulation aneurysms. *J Neurosurg* 87: 544-54, 1997.
16. George B, Lot G. Anterolateral and posterolateral approaches to the foramen magnum: Technical description and experience from 97 cases. *Skull Base Surg* 5: 9-19, 1995.
17. George B, Lot G, Boissonnet H. Meningioma of the foramen magnum: A series of 40 cases. *Surg Neurol* 47: 371-9, 1997.
18. Olivier AG. *Antropologia del Cráneo: in Gomez-Oliveros, Lecciones de Anatomia Humana*, Marban. Madrid 1960.
19. Testut L, Latarjet A. *Tratado de anatomia humana*, Salvat. Barcelona 1977.
20. Gray H. *Características craneales en las diferentes edades; in Williams and Warwick, Anatomia*, Salvat. Barcelona 1985.
21. Catalina-Herrera CJ. Study of the Anatomic Metric Values of the Foramen Magnum and Its Relation to Sex. *Acta Anat* 130: 344-7, 1987.
22. Wanebo JE, Chicoine MR. Quantitative analysis of the transcondylar approach to the foramen magnum. *Neurosurgery* 49: 934-41, 2001
23. Lang J. *Skull Base and Related Structures – Atlas of Clinical Anatomy*. (Translation into English by Juliane Kemmer). Schattauer Verlagsgesellschaft mbH. Stuttgart, 1995.
24. Babu RP, Sekhar LN, Wright DC. Extreme lateral transcondylar approach: Technical improvements and lessons learned. *J Neurosurg* 81: 49-59, 1994.
25. George B, DeMantos C, Cophignon J. Lateral approach to the anterior portion of the foramen magnum. *Surg Neurol* 29: 484-90, 1988.
26. Heros RC. Lateral suboccipital approach for vertebral and vertebrobasilar artery lesions. *J Neurosurg* 64: 559-62, 1986.
27. Wen HT, Rhoton Jr AL, Katsuta T et al. Microsurgical anatomy of the transcondylar, supracondylar and paracondylar extensions of the far lateral approach. *J Neurosurg* 87: 555-85, 1997.
28. Behrens M. *Über volumen und Öffnungen der hinteren Schädelgrube*. Medizinische Dissertation, Würzburg. Germany 1975.
29. Lang J, Schafhauser O, Hoffman S. *Über die postnatale Entwicklung der transvasalen Schädelportalen: Canalis Caroticus, Foramen jugulare, Canalis hypoglossalis, Canalis condylaris und Foramen magnum*. *Anat Anz* 153: 315-57, 1983.
30. Lang J, Hornung G. *Über den Canalis hypoglossi und seinen Inhalt beim posterolateralen Zugang zur petroclivale Region*. *Neurochirurgia* 1993.
31. Lang J, Schreiber T. *Über Form und Lage des Foramen jugulare (Fossa jugularis), des Canalis caroticus und des Foramen stylomastoideum sowie deren postnatale Lageveränderungen*. *HNO* 31: 80-7, 1983.