

1-1-2004

The Evaluation of the Stomatognathic System of a Group with Anterior Openbite

SEMRA CİĞER

ELİF İDİL KESER

Follow this and additional works at: <https://journals.tubitak.gov.tr/medical>



Part of the [Medical Sciences Commons](#)

Recommended Citation

CİĞER, SEMRA and KESER, ELİF İDİL (2004) "The Evaluation of the Stomatognathic System of a Group with Anterior Openbite," *Turkish Journal of Medical Sciences*: Vol. 34: No. 4, Article 8. Available at: <https://journals.tubitak.gov.tr/medical/vol34/iss4/8>

This Article is brought to you for free and open access by TÜBİTAK Academic Journals. It has been accepted for inclusion in Turkish Journal of Medical Sciences by an authorized editor of TÜBİTAK Academic Journals. For more information, please contact academic.publications@tubitak.gov.tr.

The Evaluation of the Stomatognathic System of a Group with Anterior Openbite

Semra CİĞER, Elif İdil KESER

Department of Orthodontics, Faculty of Dentistry, Hacettepe University, Ankara - Turkey

Received: December 23, 2003

Abstract: Anterior openbite (AOB) is a malocclusion considered to be associated with symptoms and signs of temporomandibular disorders (TMD). An accurate, objective and repeatable method is needed in order to clarify the relationship between TMD and anterior openbite. The aim of this study is to examine the functions of the stomatognathic systems of 21 adolescents with AOB by means of electrovibratography (EVG), electrognathography (EMG), electrognathography (EGN), and transcranial and cephalometric radiographs. Noncentricity and mild asymmetry of the condyle fossa relationships were observed on transcranial radiographs. EMG results showed that 85% of the subjects had abnormal swallowing patterns and 52% had abnormal clenching patterns. The mean maximum vertical opening was 47.26 mm and mean deflection during opening was 2.15 mm. Some 14% of the subjects had high vibrations for the left joint and 10% for the right joint. Although the subjects did not exhibit clinical symptoms of TMD, they had abnormal patterns of stomatognathic function. This must be taken into consideration during the treatment of AOB malocclusion.

Key Words: openbite, temporomandibular disorder, electromyography, electrognathography, electrovibratography

Introduction

The relationship between malocclusion traits and symptoms and signs of temporomandibular disorders (TMD) has been extensively studied in the literature and TMD is generally considered to be one of the risks related to malocclusion(1-5) . Anterior openbite (AOB) is a malocclusion significantly associated with symptoms and signs of TMD (6-11). However, in some studies, no association was found between AOB and signs and symptoms of TMD (12,13).The aim of this study was to examine the functions of the stomatognathic system of adolescents with AOB.

Materials and Methods

Twenty-one subjects (13 female and 8 male) with a mean age of 14 years 7 months who had AOB were included in this study. All subjects had skeletal and dental class I malocclusions.

Standardized lateral cephalograms in centric occlusion, and anteroposterior and transcranial radiographs were obtained. Stomatognathic functions were evaluated by means of EVG, EMG and EGN (Bio-PAK, Bio-Research Ass.,Milwaukee, USA) (Figure 1).



Figure 1. Bio-PAK apparatus.

Skeletal and dental measurements were made on the lateral cephalograms by the same observer. Joint spaces (AJS, PJS, SJS), vertical height of the articular fossa, angle of the articular slope, ratio of posterior to anterior joint space and percentage of posterior to anterior joint space were evaluated on the transcranial radiographs as suggested by Cohlma et al. (14) (Figure 2).

Surface vibrations of the temporomandibular joints were recorded through EVG (Figure 3). Total integral (I) which is the total amount of energy in the vibration, integral below 300 Hz ($I < 300$ Hz), integral above 300 Hz ($I > 300$ Hz), and the relative fraction of high frequency to low frequency energy ($>/<$) were recorded and classified. The classification was as follows:

- 0: No clicking
- 1: Opening click
- 2: Closing click
- 3: Opening and closing click

Electromyographic data were collected during the rest position, swallowing and clenching for temporalis anterior (TA), masseter (MM), digastric anterior (DA) and sternocleidomastoid (SCM) muscles. Classifications were made for swallowing and clenching activity according to these criteria:

Classification for swallowing activity:

0: Normal (MM and TA fire with bilateral symmetry. DA shows very little activity as the mandible closes during swallowing but shows a burst later. The swallow lasts about 1-1.5 s).

1: Abnormal (MM shows little activity and DA shows higher activity as the mandible does not close onto centric occlusion. The swallow lasts more than 2 s) (Figure 4).

Classification for clenching activity:

0: Normal (balanced function between MM and TA, or between the left and right sides).

1: Abnormal (a difference $\geq 2:1$ between MM and TA, or between the left and right sides).

Jaw movements were recorded during opening and closing, chewing and speech using a jaw tracking sensor array. Maximum vertical opening, amount of deflection, maximum velocities, amount of horizontal movement and terminal velocities were calculated (Figure 5). Chewing cycles were obtained on different planes.

Results

The subjects exhibited a vertical growth pattern (FMA: 30.2°), and a mean ANB value of 2.56° . The mean overbite was -2.57 mm (Table 1).

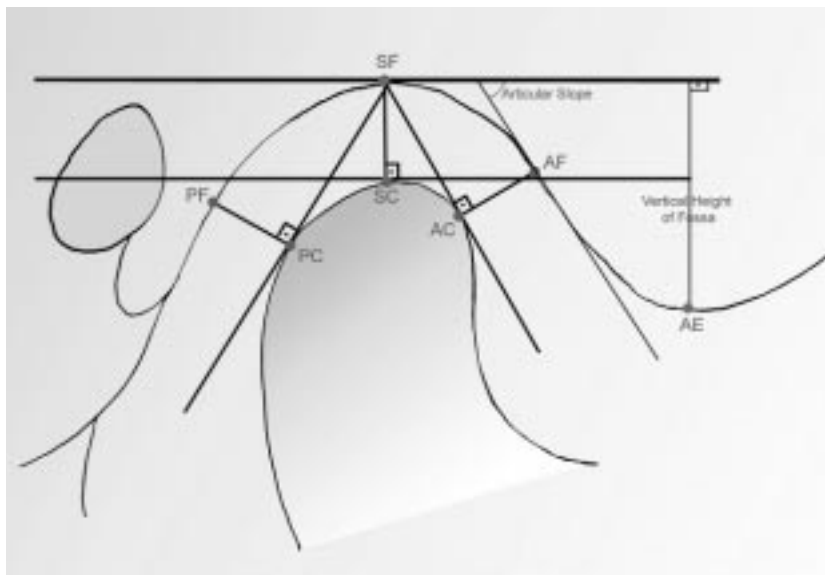


Figure 2. Measurements made on transcranial radiographs.

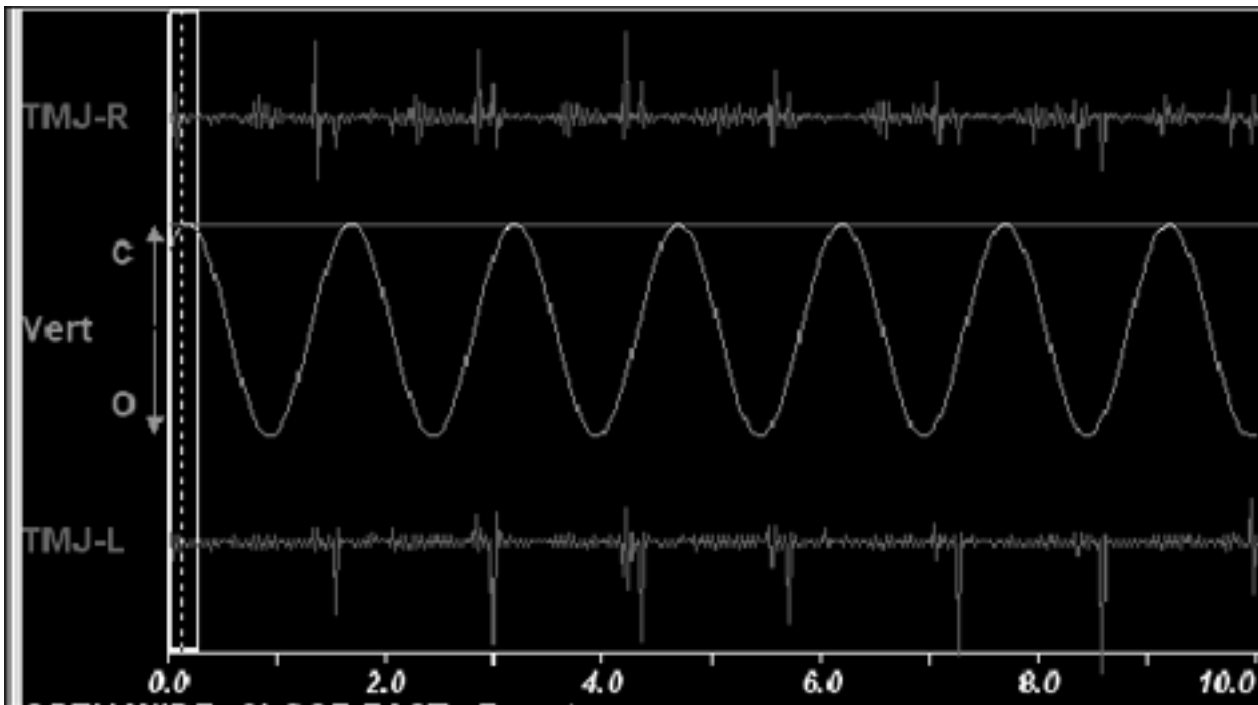


Figure 3. Joint vibration analysis, sweep display during opening and closing.

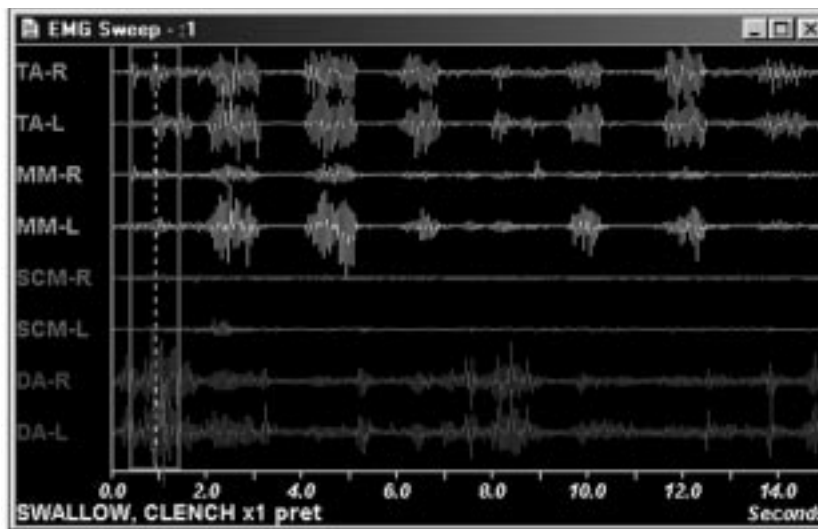


Figure 4. EMG sweep display during swallowing and clenching

Nonconcentricity and mild asymmetry of the condyle fossa relationships were commonly observed (Table 2). Left and right mean angles of the articular slope were smaller for this sample when compared to the values of normal subjects that were given in other studies.

Results of the joint vibration analysis showed that

14% of the subjects reported showed high vibrations for the left joint and 10% for the right joint, indicating derangement (Table 3).

EMG results showed that 85% of the subjects had abnormal swallowing patterns and 52% had abnormal clenching patterns (Table 4).

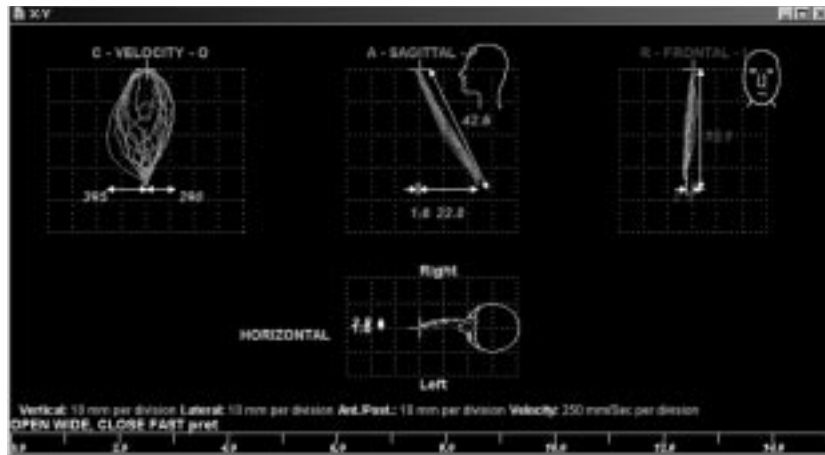


Figure 5. Electrognathography during opening and closing.

Table 1. Descriptive statistics of the cephalometric variables.

VARIABLES	MEAN	SD	MIN	MAX
Overbite (mm)	-2.57	1.95	-7	0
B1 ext. (mm)	-3.33E-02	1.37	-2.6	3
B1 AP (mm)	5.15	2.4	0	10.3
A1 AP (mm)	9.18	2.52	6	14
B1 inc. (°)	28.64	4.44	23	39.1
A1 inc. (°)	32.11	4.07	25.2	42
Convexity (mm)	2.85	2.42	-1.5	8.5
LFH (°)	53.51	4.03	46	61.2
Saddle (°)	125.02	5.83	115	135
Fac. Depth (°)	85.85	3.21	81	91.7
Fac. Axis (°)	80.59	2.75	75	84
Max. Depth (°)	88.46	2.23	84	93
Max. Height (°)	63.12	3.23	58	73
FMA (°)	30.2	3.87	24.5	38.7
SNA (°)	77.8	2.5	71	82
SNB (°)	75.22	2.74	69	79
ANB (°)	2.56	1.23	-0.5	5
TFH (°)	67.1	4.41	60	77
LL-EP (mm)	-0.19	3.02	-5.4	4

Table 2. Descriptive statistics of transcranial radiographs.

VARIABLES	MEAN	SD	MIN	MAX
SJSR (mm)	3.77	1.49	2	9
AJSR (mm)	2.23	0.8	1	5
PJSR (mm)	2.45	0.8	1	4
AFSR (°)	47.04	11.19	29	70
AEHR (mm)	7.83	1.88	5	12
%R	7.51	20.5	-42.85	50
P/A R	1.2	0.58	0.4	3
SJSL (mm)	3.7	0.86	2.3	6
AJSL (mm)	2.42	0.62	1.5	4.2
PJSL (mm)	2.87	1.05	1.5	6
AFSL (°)	48.71	10.76	29	69
AEHL (mm)	7.23	1.57	4	10
%L	6.84	21.18	-33.33	50
P/A L	1.27	0.61	0.5	3

EGN results showed that the mean maximum vertical opening was 47.26 mm and mean deflection during opening was 2.15 mm. When range of motion (ROM) was evaluated it was found that 28% of the subjects had an undeviated trajectory, 14% had an anterior opening posterior closing pattern, 23% had a posterior opening anterior closing pattern and 33% had crossovers (Table 5).

Discussion

In the literature, most studies examining the relationship between anterior openbite and TMD are based on questionnaires and controversy still remains. A more accurate, objective and repeatable method is needed in order to evaluate the relationship between malocclusion types and TMD. In this study all the variables

Table 3. Descriptive statistics of joint vibration analysis.

VARIABLES	MEAN	SD
Total Int L	11.91	6.83
Total Int R	10.96	4.39
< 300 Hz L	9.71	6.23
< 300 Hz R	8.89	3.96
> 300 Hz L	2.2	0.75
> 300 Hz R	2.08	0.68
Ratio L	0.28	0.12
Ratio R	0.26	0.12

Classification Left	Frequency	Percent
0	18	85.7
1	0	0
2	2	9.5
3	1	4.8

Classification Right	Frequency	Percent
0	19	90.5
1	1	4.8
2	1	4.8
3	0	0

Table 4. Descriptive statistics of the EMG variables.

VARIABLES	MEAN	SD	MIN	MAX
Rest TAR	3.6	2.09	1.3	7.2
Rest TAL	3.58	2.9	1.1	10
Rest MMR	2.51	1.44	1	5.2
Rest MML	2.75	2.71	1.1	13.3
Rest SCMR	2.72	1.65	0.8	6
Rest SCML	3.01	1.76	0.8	8.9
Rest DAR	3.17	1.87	1.1	9.4
Rest DAL	3.2	2.15	1	10.4
Swallow TAR	12.58	9.86	2.3	37.4
Swallow TAL	10.66	8.13	0.6	34.1
Swallow MMR	8.4	4.86	3.2	22
Swallow MML	8.84	1.06	4.4	17.9
Swallow SCMR	4.9	1.36	2	7.1
Swallow SCML	4.76	1.39	2.3	7.8
Swallow DAR	26.82	14.48	9.2	68.9
Swallow DAL	26.39	14.68	10.3	70.6
Swallow Time	1150.86	348.31	372	2000
Clench TAR	56.57	41.41	2.3	160.6
Clench TAL	64.69	49.2	7.4	174.3
Clench MMR	42.76	31.23	12.3	121.6
Clench MML	44.77	30.86	9.8	145.5
Clench SCMR	5.74	3.08	2.3	15.5
Clench SCML	6.89	3.77	2.2	14.5
Clench DAR	9.37	5.67	3.3	27.9
Clench DAL	9.79	6.76	3.3	29.3

Swallow Type	Frequency	Percent
0	3	14.3
1	18	85.7

Clench Type	Frequency	Percent
0	10	47.6
1	11	52.4

were measurable and evaluated according to norms, not according to patients' subjective statements.

One of the findings of this study is the asymmetry of the TMJ, confirming previous reports (15,16,17). This asymmetry may be related to normally occurring cranial base asymmetries (15,18) and side preferences during mastication (17). Analysis of TMJ vibrations has been advocated as a potential modality for evaluation of TMJ disorders and it has been suggested that the sound characteristics of the TMJ might have diagnostic significance (19). In a previous study it was found that joints with internal derangement had a significantly

energy level for joint vibrations at any frequency higher than normal joints and these differences were particularly apparent below 250 Hz. The overall energy content for joint vibrations was also higher for the internal derangement group (20). In our study group approximately 90% of the patients had low energy level vibrations; only 1 out of 42 TMJs had both opening and closing click. As the group consisted of asymptomatic subjects, this result was expected.

Results of the EMG showed that an abnormal swallowing pattern was a common feature of patients with AOB, and anterior digastric hyperactivity was seen

Table 5. Descriptive statistics of jaw tracker during opening and closing.

VARIABLES	MEAN	SD	MIN	MAX
Max. Vert. Op	47.26	4.34	39.8	58.8
Act. Vert. Op.	38.34	4.29	28.8	47.8
Deflection	2.15	2.01	0	8.8
H/Act. V.	73.37	19.27	49.15	128.75
Max. Vel. Op.	305.95	83.44	178	492
Max. Vel. Cl.	361	130.42	157	698
Terminal Vel.	64.76	27.68	30	150
Horizontal Right	4.19	2.79	0.6	10.9
Horizontal Left	1.59	1.65	0	5.9

Classification	Frequency	Percent	
0	6	28.6	0: Undeviated
1	3	14.3	1: Open anterior close posterior
2	5	23.8	2: Open posterior close anterior
3	7	33.3	3: Crossover

during swallowing in all patients. Since anterior digastric hyperactivity is associated with dysfunctional swallow, openbites and mouth breathing, this result was expected.

The amount of maximum vertical opening as recorded by EGN was within normal ranges. Although Harper (21) suggested that mandibular opening greater than 40 mm does not imply a normal joint status, it is still important in the evaluation of stomatognathic system functions. However, only 28.6% patients had an undeviated trajectory in the sagittal plane. As an undeviated trajectory represents a more relaxed muscular system and more coordinated opening and closing movements, it can be said that 71.4% of this group had disturbances during opening and closing movements.

Mastication is a complex activity that requires precise coordination of the entire stomatognathic system, and impairments of mandibular motion may be linked with various TMD conditions. The pattern of mastication is influenced by the occlusion, skeletal relationship and type of bolus. Chewing gum was used in this study to standardize the chewing cycles. Opening and closing velocities were found within normal ranges but chewing

patterns on different planes showed a great variety between subjects, presenting a need for individual interpretation of the chewing cycles for each subject.

Conclusion

The results of this study showed that the stomatognathic systems of AOB patients were disturbed by this malocclusion. Even though the subjects did not exhibit symptoms of TMD, they had abnormal patterns of chewing and muscle functions when evaluated by means of EVG, EMG and EGN.

Since openbite is a malocclusion which tends to display some of the signs and symptoms of TMD this risk must be taken into consideration during orthodontic treatment of this malocclusion.

Acknowledgment

This study was supported by a grant (no: 97K121370) from the State Planning Organization (Devlet Planlama Teşkilatı).

Corresponding author:*Elif İdil KESER**Department of Orthodontics,**Faculty of Dentistry, Hacettepe University,**TR-06100 Sıhhiye, Ankara - Turkey**E-mail: elifkeser@hotmail.com***References**

1. Brook P, Shaw WC. The development of an index of orthodontic treatment priority. *Europ J Orthod* 11: 309-20, 1989.
2. Espeland LV, Ivarsson K, Stenvik A. A new Norwegian index of orthodontic treatment need related to orthodontic concern among 11 years olds and their parents. *Comm Dent Oral Epidemiol* 20: 274-9, 1992.
3. Vanderas AP. Relationship between malocclusion and craniomandibular dysfunction in children and adolescents; a review. *Ped Dent* 15: 317-22, 1993.
4. McNamara JA, Seligman DA, Okeson JP. Occlusion, orthodontic treatment, and temporomandibular disorders; a review. *J Orofacial Pain* 9: 73-90, 1995.
5. Sonnesen L, Bakke M, Solow B. Malocclusion traits and symptoms and signs of temporomandibular disorders in children with severe malocclusion. *Europ J Orthod* 20: 543-59, 1998.
6. Brandt D. Temporomandibular disorders and their association with morphologic malocclusion in children. In: Carlson DS, McNamara JA, Ribbens KA (eds). *Developmental aspects of temporomandibular joint disorders*. Monograph No 16. Craniofacial Growth Series. Center for Human Growth and Development, University of Michigan, Ann Arbor, 1985 pp. 279-98.
7. Riolo ML, Brandt D, TenHave TR. Associations between occlusal characteristics and signs and symptoms of TMJ dysfunction in children and young adults. *Am J Orthod Dentofac Orthop* 92: 467-77, 1987.
8. Tanne K, Tanaka E, Sakuda M. Association between malocclusion and temporomandibular disorders in orthodontic patients before treatment. *J Orofacial Pain* 7: 156-62, 1993.
9. Williamson EH. Temporomandibular dysfunction in pretreatment adolescent patients. *Am J Orthod* 72: 429-33, 1977.
10. Koak JY, Kim KN, Heo SJ. A study on the mandibular movement of anterior openbite patients. *J Oral Rehab* 27: 817-22, 2000.
11. Thilander B, Rubio G, Pena L et al. Prevalence of temporomandibular dysfunction and its association with malocclusion in children and adolescents: an epidemiologic study related to specified stages of dental development. *Angle Orthodontist* 72: 146-54, 2002.
12. Egermark-Eriksson I, Ingervall B, Carlsson GE. The dependence of mandibular dysfunction in children on functional and morphologic malocclusion. *Am J Orthod* 83: 187-94, 1983.
13. Egermark-Eriksson I, Carlsson GE, Magnusson T et al. A longitudinal study on malocclusion in relation to signs and symptoms of cranio-mandibular disorders in children and adolescents. *Europ J Orthod* 12: 399-407, 1990.
14. Cohlmiä JT, Ghosh J, Sinha PK et al. Tomographic assessment of temporomandibular joints in patients with malocclusion. *Angle Orthodontist* 66: 27-36, 1996.
15. Pullinger A, Hollender L, Solberg W et al. A tomographic study of mandibular condyle position in an asymptomatic population. *Journal of Prosthetic Dentistry* 53: 706-13, 1985.
16. Artun J, Hollender L, Truelove E. Relationships between orthodontic treatment, condylar position and internal derangement in th temporomandibular joint. *Am J Orthod Dentofac Orthoped* 101: 48-53, 1992.
17. Larheim T. Temporomandibular joint space in children without joint disease. *Acta Radiol Diag* 22: 85-88, 1981.
18. Vig PS, Hewitt AB. Asymmetry of the human facial skeleton. *Angle Orthodontist* 45: 125-9, 1975.
19. Oster C, Katzberg R, Tallents R et al. Characterization of temporomandibular joint sounds. *Oral Surg Oral Med O& Path* 58: 10-15, 1984.
20. Ishigaki S, Bessette RW, Maruyama T. A clinical study of temporomandibular joint vibrations in TMJ dysfunction patients. *Journal of Craniomandibular Practice* 11: 7-13, 1993.
21. Harper RP. Analysis of temporomandibular joint function after orthognathic surgery using condylar path tracings. *Am J Orthod Dentofac Orthoped* 97: 480-8, 1990.