

1-1-2004

Difficulties and Failure of Laryngeal mask Insertion in a Patient with Ankylosing Spondylitis

GÖNÜL ÖLMEZ

HASAN NAZAROĞLU

SEHER GÜNDÜZ ARSLAN

MEHMET ALİ ÖZYILMAZ

AYŞE DİCLE TURHANOĞLU

Follow this and additional works at: <https://journals.tubitak.gov.tr/medical>



Part of the [Medical Sciences Commons](#)

Recommended Citation

ÖLMEZ, GÖNÜL; NAZAROĞLU, HASAN; ARSLAN, SEHER GÜNDÜZ; ÖZYILMAZ, MEHMET ALİ; and TURHANOĞLU, AYŞE DİCLE (2004) "Difficulties and Failure of Laryngeal mask Insertion in a Patient with Ankylosing Spondylitis," *Turkish Journal of Medical Sciences*: Vol. 34: No. 5, Article 12. Available at: <https://journals.tubitak.gov.tr/medical/vol34/iss5/12>

This Article is brought to you for free and open access by TÜBİTAK Academic Journals. It has been accepted for inclusion in Turkish Journal of Medical Sciences by an authorized editor of TÜBİTAK Academic Journals. For more information, please contact academic.publications@tubitak.gov.tr.

SHORT REPORT

Difficulties and Failure of Laryngeal mask Insertion in a Patient with Ankylosing Spondylitis

Gönül ÖLMEZ¹, Hasan NAZAROĞLU², Seher Gündüz ARSLAN³, Mehmet Ali ÖZYILMAZ¹,
Ayşe Dicle TURHANOĞLU⁴

¹Department of Anesthesiology, Faculty of Medicine, Dicle University, Diyarbakır - Turkey

²Department of Radiology, Faculty of Medicine, Dicle University, Diyarbakır - Turkey

³Department of Orthodontics, Faculty of Dentistry, Dicle University, Diyarbakır - Turkey

⁴Physical Therapy and Rehabilitation, Faculty of Medicine, Dicle University, Diyarbakır - Turkey

Received: November 11, 2003

Key Words: Ankylosing spondylitis, Anesthesia, Laryngeal masks

Patients with ankylosing spondylitis (AS) present some specific challenges to the anesthetist in both airway management and neuraxial access (1,2). Clinical presentation of the patients may be associated with decreasing mobility, total rigidity and even fixity because of the involvement of the cervical and thoracolumbar spine (1). Airway management of such a patient is still a subject of controversy.

This report describes the management of a patient with AS with fixed rigidity of the cervical spine in whom intubation or insertion of the laryngeal mask airway (LMA) could not be accomplished because of the acute oropharyngeal axes.

Case Report

A 40-year-old 70-kg man with a history of AS for 20 years was admitted to our emergency department with femoral fracture following an accident at home.

He had been suffering gradual onset of deformity for 20 years and he had progressively developed a thoracolumbar kyphosis limiting the him to lying down in a supine position and necessitating 2 thick pillows beneath his head for support. He had undegone uneventful general anesthesia 10 years before.

In the preoperative assessment, it was considered that intubation of the trachea was impossible because of previous attempts at intubations in a rural hospital. Neck movements were severely restricted in the anteroposterior as well as lateral positions. His mouth opening was 4.5 cm, but his upper airway Mallampati classification was grade 4.

In the operating room, routine monitoring was applied. At first step, a midline approach for spinal anesthesia was attempted but this failed. Then a lateral approach was attempted but this failed 3 times. We tried to apply LMA for supplying an effective airway and inducing general anesthesia. The patient was in the supine position with the head and neck supported on pillows so that he was as close to the neutral position as possible within the comfort limits of the patient. The patient was given 1 mg.kg⁻¹ ketamine and 0.05 mg.kg⁻¹ midazolam and underwent inhalation induction by breathing sevoflurane, spontaneously and unassisted, in 100% oxygen delivered via a facemask. When the eyelash reflex disappeared, insertion of the LMA was attempted using a standard technique. A size 4 LMA was used. However, insertion of the LMA was unsuccessful despite 3 attempts. The cuff tip of the LMA faced the posterior pharyngeal wall and curled spontaneously. All these attempts

followed the same course, in which the mask tip folded over the mask tube, which kinked against the posterior pharyngeal wall. The LMA also could not be advanced further downward onto the posterior pharyngeal wall. Even with the alternative technique – the use of a laryngoscope– rotational movement of the tube failed. After several unsuccessful attempts to establish the airway, we decided to start surgery under general anesthesia with sevoflurane in oxygen via a facemask and IV ketamine and spontaneous breathing. The intraoperative course of the patient was uneventful. Intubation was not performed with a fiberoptic laryngoscope as one was not available.

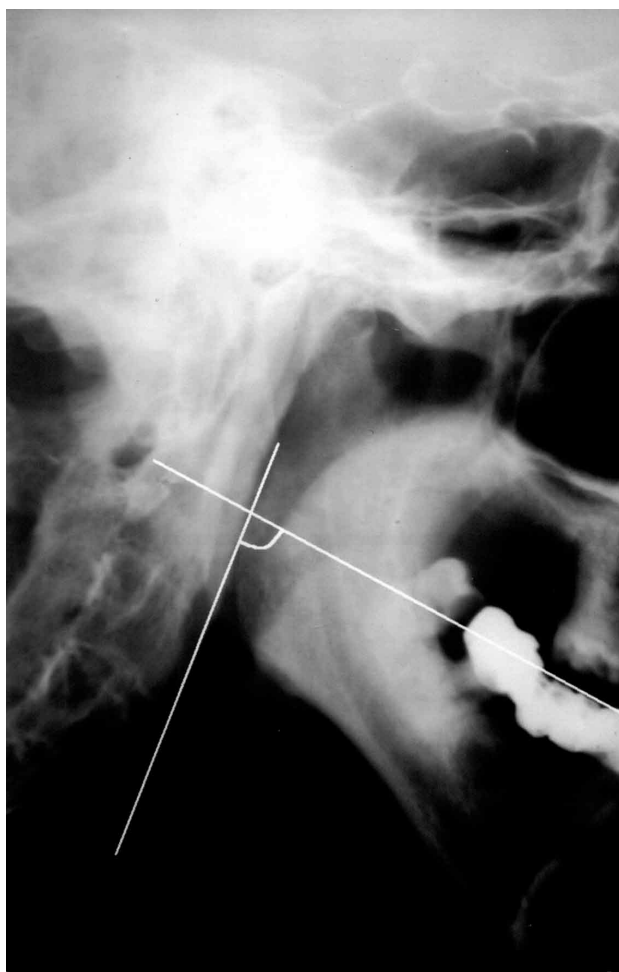


Figure. At neck flexion and maximal head extension, the angle between the oral and the pharyngeal axes at the back of the tongue was 73° in the patient.

One week later, the laryngeal anatomy was re-examined with rigid laryngoscopy, which revealed no anatomical abnormality. We evaluated the patient's neck radiologically and obtained an oropharyngeal axis, which was described by Ishimura et al. (3). The oropharyngeal axis consisted of 2 planes: the functional occlusal plane and the pharyngeal axis. The oral axis is the functional occlusal plane, which joins the cross points of the upper and lower premolar/molar teeth in the occlusal condition. The pharyngeal axis is the plane parallel to the cervical spine from the narrowest part of the back of the tongue. At neck flexion and maximal head extension, the angle between the oral and the pharyngeal axes at the back of the tongue was 73° (Figure).

The classic LMA and/or intubating laryngeal mask airway ((ILMA) devices have been used anecdotally in AS patients following failed laryngoscope-guided tracheal intubation (4), for conscious insertion (5,6), and as an alternative to (7) and/or aid to (8-10) tracheal intubation in anesthetized patients. The advantages of the LMA or ILMA for AS are that insertion and intubation can be accomplished without head and neck movement or direct laryngoscopy, and ventilation can continue during intubation (9-11).

The ILMA could offer potential advantages over the LMA in the patient whose head and neck movements are restricted since it may be easier to insert, and it is a better airway intubator (12,13). It has been claimed that when the intubating laryngeal mask is used, the position of the mask can be adjusted by the metal handle even when the position is initially suboptimal (14). However, the LMA is more suitable if the mouth opening is less than 2 cm or intubation is not required. We do not have an ILMA in our clinic. We planned to use, LMA for airway control but not for intubation. Because the procedure applied to our patient was limited in the lower extremity the operation could be only terminated by inhalation anesthesia and analgesia, which preserve spontaneous breathing. It was reported by Smigovec et al. (15) that by using LMA alone anesthesia can be achieved successfully in orthopedic surgery.

Lu et al. (10) reported that inhalation induction followed by intubating ILMA is a reasonable option in patients with severe AS undergoing elective surgery in which the ILMA provided an effective airway at the first attempt in their 11 patients.

Pennant and White (16), however, suggested that LMA use should be contraindicated in patients who are unable to extend the neck because of AS, severe rheumatoid arthritis (RA), or cervical spine instability.

On the other hand, there is a new challenging aspect of the oropharyngeal axis, which was first described by Ishimura et al. for RA patients. Ishimura et al. (3) considered that the angle in a patient in whom the LMA was successfully inserted is usually 105° when the neck is flexed and head extended, the maneuver considered necessary for successful LMA insertion. They suggest that LMA insertion appeared to be impossible when the angle between the oral and the pharyngeal axes was smaller than 90° at the back of the tongue. There have been few reports that refer in detail to difficult LMA insertion because of narrowing in this angle (9). Our patient's neck radiology showed a narrow angle of the oropharyngeal axis, which makes LMA insertion impossible. This axis should be measured prior to surgery in patients with AS. We think that this will serve as a guide for detecting the success of placement of the LMA. If there is an axis with an angle smaller than 90°, an alternative way might be considered, such as retrograde intubation, transtracheal jet ventilation, or surgical airway. A full range of equipment and personnel should be available if alternative means for obtaining an acceptable airway are required.

We induced anesthesia with sevoflurane to minimize the risk of sudden loss of airway control. There have been several studies reporting LMA insertion following induction with sevoflurane (3,10,17,18). Cross et al. (17) reported that spontaneous ventilation had been maintained in all patients in whom an LMA was placed following induction with sevoflurane. In a study by Kati et al. (18) the use of sevoflurane or propofol induction was investigated in the insertion of LMA. Spontaneous breathing was achieved in all patients with sevoflurane, whereas apnea was faced in 40% of patients with propofol.

We suggest that the oropharyngeal axis should be measured before performing anesthesia in a patient with severe AS because of the difficulties in intubation with an LMA. The use of the oropharyngeal axis as a predictor of difficult LMA insertion should be prospectively evaluated before any conclusions are made.

Corresponding author:

Gönül ÖLMEZ

Department of Anesthesiology, Faculty of Medicine,

Dicle University, 21280- Diyarbakır- Turkey

e-mail: golmez@dicle.edu.tr

References

1. Hamano N, Murao K, Sakamoto S et al. Anesthesia for a severe ankylosing spondylitis patient whose posture had been restricted to only sitting for over 20 years. *Masui* 51: 1026-1028, 2002.
2. Schelew BL, Vaghadia H. Ankylosing spondylitis and neuraxial anaesthesia—a 10 year review. *Can J Anaesth* 43: 65-68, 1996.
3. Ishimura H, Minami K, Sata T et al. Impossible insertion of the laryngeal mask airway and oropharyngeal axes. *Anesthesiology* 83: 867-869, 1995.
4. Steib A, Beller JP, Llieu JC et al. Difficult intubation managed by laryngeal mask and fibroscopy. *Ann Fr Anesth Reanim* 11: 601-603, 1992.
5. Williams PJ, Bailey PM. Management of failed oral fiberoptic intubation with laryngeal mask airway insertion under topical anaesthesia. *Can J Anaesth* 40: 287, 1993.
6. Dimitriou V, Voyagis G, Brimacombe J. Flexible light-wand-guided intubation through the ILM. *Acta Anaesthesiol Scand* 45: 263-264, 2001.
7. Defalque RJ, Hyder ML. Laryngeal mask airway in severe cervical ankylosis. *Can J Anaesth* 44: 305-307, 1997.
8. Chadd GD, Ackers JWL, Bailey PM. Difficult intubation aided by the laryngeal mask airway. *Anaesthesia* 44: 1015, 1989.
9. Brimacombe J, Berry A. Laryngeal mask airway insertion. A comparison of the standard versus neutral position in normal patients with a view to its use in cervical spine instability. *Anaesthesia* 48: 670-671, 1993.
10. Lu PP, Brimacombe J, Ho AC et al. The intubating laryngeal mask airway in severe ankylosing spondylitis. *Can J Anaesth* 48: 1015-1019, 2001.
11. Pennant JH, Pace NA, Gajraj NM. Role of the laryngeal mask airway in the immobile cervical spine. *J Clin Anesth* 5: 226-230, 1993.
12. Asai T, Wagle AU, Stacey M. Placement of the intubating laryngeal mask is easier than the laryngeal mask during manual in-line neck stabilization. *Br J Anaesth* 82: 712-4, 1999.
13. Lucas DN, Yentis SM. A comparison of the intubating laryngeal mask tracheal tube with a standard tracheal tube for fiberoptic intubation. *Anaesthesia* 55: 358-361, 2000.

14. Brain AI, Verghese C, Addy EV et al. The intubating laryngeal mask. II: A preliminary clinical report of a new means of intubating the trachea. *Br J Anaesth* 79: 704-709, 1997.
15. Smigovec E, Sakic K, Tripkovic B. The Laryngeal Mask— news in ortopedic anesthesia (Roman). *Lijec Vjesn* 115: 166-169, 1993.
16. Pennant JH, White PF. The laryngeal mask airway. Its uses in anesthesiology. *Anesthesiology* 79: 144-163, 1993.
17. Cros AM, Chopin F, Lopez C et al. Anesthesia induction with sevofluran in adult patients with predictive signs of difficult intubation. *Ann Fr Anesth Reanim (in French)* 21: 249-255, 2002.
18. Kati I, Demirel CB, Huseyinoglu UA et al. Comparison of propofol and sevoflurane for laryngeal mask airway insertion. *Tohoku J Exp Med* 200: 111-118, 2003.