

1-1-2004

## Persistent Müllerian Duct Syndrome with Transverse Testicular Ectopia: A Case Report with Literature Review

MUSTAFA FUAT AÇIKALIN

ÖZGÜL PAŞAOĞLU

BARAN TOKAR

DİLEK İLGİCİ

HÜSEYİN İLHAN

Follow this and additional works at: <https://journals.tubitak.gov.tr/medical>



Part of the [Medical Sciences Commons](#)

---

### Recommended Citation

AÇIKALIN, MUSTAFA FUAT; PAŞAOĞLU, ÖZGÜL; TOKAR, BARAN; İLGİCİ, DİLEK; and İLHAN, HÜSEYİN (2004) "Persistent Müllerian Duct Syndrome with Transverse Testicular Ectopia: A Case Report with Literature Review," *Turkish Journal of Medical Sciences*: Vol. 34: No. 5, Article 8. Available at: <https://journals.tubitak.gov.tr/medical/vol34/iss5/8>

This Article is brought to you for free and open access by TÜBİTAK Academic Journals. It has been accepted for inclusion in Turkish Journal of Medical Sciences by an authorized editor of TÜBİTAK Academic Journals. For more information, please contact [academic.publications@tubitak.gov.tr](mailto:academic.publications@tubitak.gov.tr).

SHORT REPORT

## Persistent Müllerian Duct Syndrome with Transverse Testicular Ectopia: A Case Report with Literature Review

Mustafa Fuat AÇIKALIN<sup>1</sup>, Özgül PAŞAOĞLU<sup>1</sup>, Baran TOKAR<sup>2</sup>, Dilek İLGİCİ<sup>1</sup>, Hüseyin İLHAN<sup>2</sup>

<sup>1</sup> Department of Pathology, Faculty of Medicine, Osmangazi University, Eskişehir - Turkey

<sup>2</sup> Department of Pediatric Surgery, Faculty of Medicine, Osmangazi University, Eskişehir - Turkey

Received: January 21, 2004

**Key Words:** Persistent müllerian duct syndrome, inguinal hernia.

Persistent müllerian duct syndrome (PMDS) is an uncommon form of male pseudohermaphroditism characterized by the persistence of well developed müllerian duct structures in an otherwise normal male with a 46,XY karyotype (1-3). The syndrome was first described by Nilson in 1939 as hernia uteri inguinalis. Subsequently, approximately 150 cases have been reported and a familial association has been found in some cases.

Transverse testicular ectopia (TTE) is one of the rarest forms of testicular ectopia. In this condition, 2 testes are located on one inguinal side and the opposite inguinal canal and scrotum are empty. TTE associated with PMDS is much rarer (1,2,4,5).

A case of PMDS with TTE discovered incidentally during surgery for inguinal hernia and undescended testes in a 39-day-old boy is presented with a literature review.

### Case Report

A 39-day-old boy was admitted with a complaint of left inguinal swelling. A left-sided inguinal hernia with bilateral cryptorchidism was found on physical examination. During the exploration of the left inguinal region, pulling of the left gonad in the hernia sac caused

protrusion of another gonad (Figure 1). The macroscopic appearance of both gonads was testis associated with fimbria-like structures. Both gonads had vas deferenses and vascular supplies. A right inguinal exploration showed no other gonad. The vas deferenses and vascular supplies of both gonads associated with a uterus-like structure located midline and posterior to the urinary bladder were determined in the abdominal exploration performed through a Pfannenstiel incision. Biopsy specimen were taken from both gonads and the left fimbria-like structure. Frozen section showed them to be testes and tubal fimbriae (Figures 2a, 2b). Histologic appearance of both testes was normal for age. Orchiopexy was performed to the respective sides of both testes. All the other structures associated with the testes were preserved. The chromosome analysis of peripheral leukocytes showed a normal 46,XY karyotype. The postoperative follow-up period was uneventful.

The exact cause of PMDS is uncertain. However, it is thought to result from the failure of synthesis or release of müllerian inhibiting factor (MIF), the failure of end-organs to respond to MIF, or a defect in the timing of the release of MIF (2). PMDS is a heterogeneous condition, which may exhibit different patterns of genetic transmission. Recent mapping of the MIF gene to chromosome 19 supports the hypothesis of an autosomal

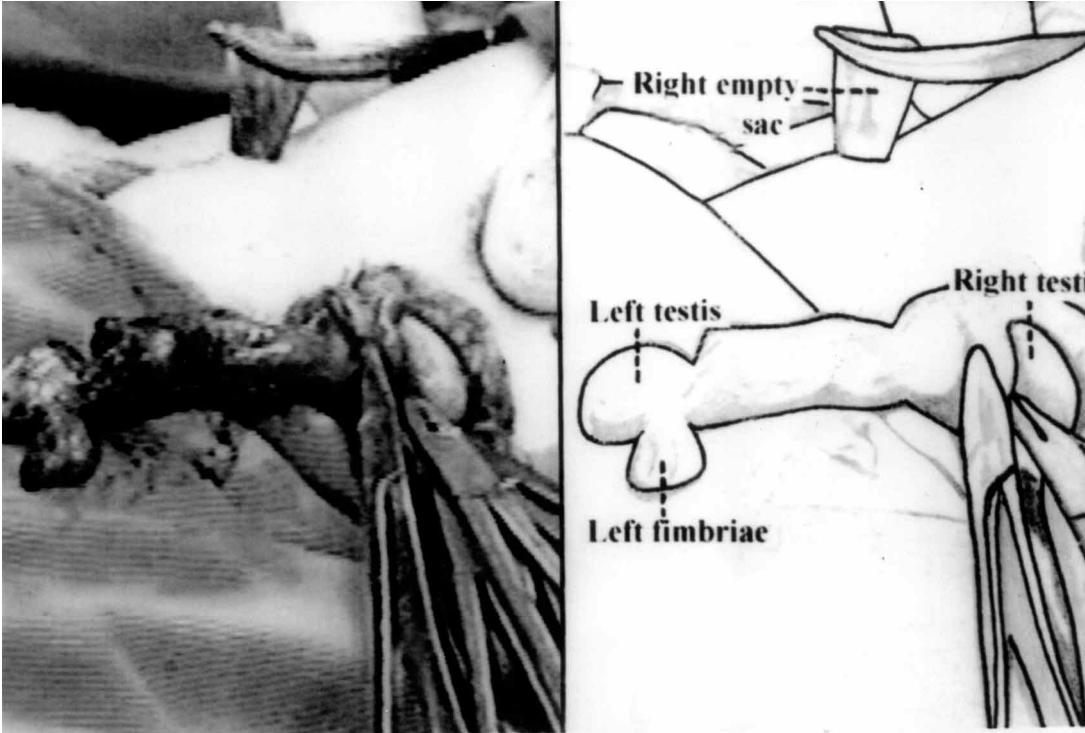


Figure 1. Intraoperative view showing the appearance of the testes and tubal fimbriae.

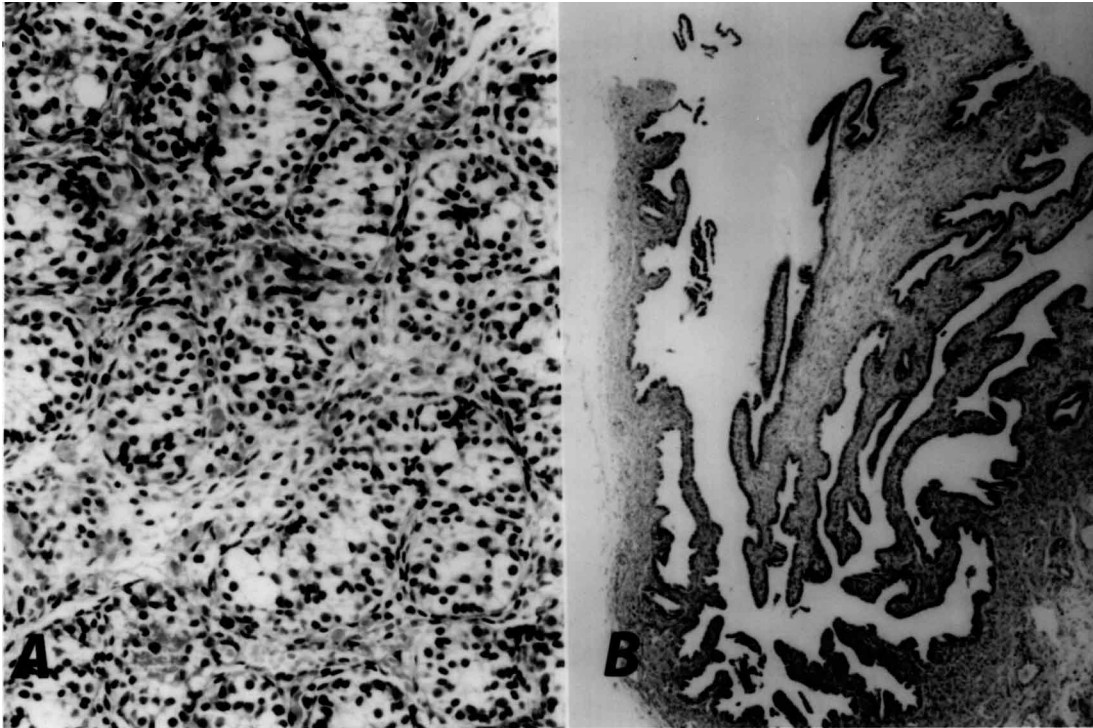


Figure 2. Microscopic appearance of the left testis (A) and tubal fimbriae (B) (H&E, original magnification x 100).

dominant mode of inheritance with sex-limited expression (6).

Patients with PMDS present with unilateral or bilateral cryptorchidism and an inguinal hernia containing a fallopian tube, uterus and testis. It is thought that a MIF does not have a direct role in the descent of the testes. Therefore, it is likely that the mechanical effect of the persistent müllerian duct structures produces cryptorchidism by preventing normal testicular descent (1). It seems possible in some cases that this mechanical effect also leads to both testicles being located on the same inguinal side, producing TTE, as in our case. As these patients have normal androgen production, they have male external genitalia and normal penile development. The testes of these patients are usually histologically normal, apart from lesions due to longstanding cryptorchidism. Putative fertility has been reported in patients with PMDS, although its occurrence is questionable.

Like other undescended testes, the gonads of these patients are at increased risk of malignant transformation. The overall incidence of malignant transformation in these gonads is 18%, similar to the rate in abdominal testes in otherwise normal men (5). There have been reports of embryonal carcinoma (7), seminoma (5,8), yolk sac tumor (8), and teratoma (5) in patients who have PMDS. There is no report of malignancy arising from the müllerian remnants. It has been suggested that tumor formation is not directly related to the defect of MIF activity (2).

As in our case, the diagnosis of PMDS is often made incidentally during surgery for an inguinal hernia or during exploration for cryptorchidism, since the PMDS does not affect organogenesis of male external genitalia and the müllerian remnants are not palpable on abdominal examination. TTE should be suspected preoperatively in patients who have unilateral inguinal hernia associated with a contralateral nonpalpable testis (1). If TTE is found, this itself represents an indication to search for PMDS (9). In suspected cases, laparoscopy and ultrasonographic evaluation may be helpful in diagnosing these conditions before surgery (10). The detection of MIF using bioassay techniques, especially in patients with bilateral cryptorchidism, also is helpful in diagnosing PMDS (5). The diagnosis of PMDS must be confirmed with testicular biopsies and chromosomal studies. The PMDS must be distinguished from mixed gonadal

dysgenesis in which the müllerian structures are generally present, but in which ambiguous genitalia are present, a testis is present unilaterally and there is a contralateral streak gonad. These patients usually show chromosome mosaicism of XO/XY (4). In contrast, PMDS is characterized by a normal 46,XY karyotype and normal masculinization of external genitalia (3). Therefore, for accurate diagnosis, both gonads must undergo frozen section biopsy and the karyotype must be determined with chromosomal studies. In our case, careful exploration of the inguinal hernia provided the first clue for diagnosis. The macroscopic appearance of testes associated with a fimbria-like structure, rudimentary uterus located midline, frozen section examination and chromosomal analysis completed all the data we needed for the differential diagnosis.

Whereas in the past removal of the müllerian remnants was targeted together with orchiopexy or orchiectomy, this is no longer recommended because there is no report of malignancy arising from the retained müllerian structures, and the removal of the uterus may damage the vasa deferentia, which are in close proximity. Hysterectomy is indicated only when müllerian structures limit intrascrotal placement of the testes (9). We think that the surgical management should be geared toward preservation of fertility, and then orchiopexy appears to be the optimal surgical management. Although orchiopexy, even if performed early in life, does not reduce the risk of malignancy, we do not recommend routine orchiectomy, because these patients do not have an increased risk of malignancy beyond that of other cryptorchidic testes. Furthermore, orchiopexy provides a palpable and, therefore, controllable location for the development of malignancy. Since most tumors occur after puberty, these patients should be kept under long-term follow-up. Orchiectomy is indicated only for testes that cannot be mobilized to a palpable location (9). Androgen replacement therapy should be given to patients who have undergone orchiectomy and to those with low levels of testosterone. In cases with TTE, crossed orchiopexy gives good results, particularly if it is performed with minimal delay.

In conclusion, although it is rare to find an association of PMDS with TTE, clinicians and pathologists should always consider these entities in the presence of bilateral cryptorchidism, especially when it is associated with unilateral inguinal hernia.

*Corresponding author:*

*Mustafa Fuat AÇIKALIN*

*Department of Pathology, Faculty of Medicine,*

*Osmangazi University,*

*26480 Meşelik, Eskişehir - Turkey*

*e-mail: acikalin@ogu.edu.tr*

**References**

1. Karnak I, Tanyel FC, Akçören Z et al. Transverse testicular ectopia with persistent müllerian duct syndrome. *J Pediatr Surg* 32: 1362-1364, 1997.
2. Thompson ST, Grillis MA, Wolkoff LH et al. Transverse testicular ectopia in a man with persistent müllerian duct syndrome. *Arch Pathol Lab Med* 118: 752-755, 1994.
3. Loeff DS, Imbeaud S, Reyes HM et al. Surgical and genetic aspects of persistent müllerian duct syndrome. *J Pediatr Surg* 29: 61-65, 1994
4. Martin EL, Bennett AH, Cromie WJ. Persistent müllerian duct syndrome with transverse testicular ectopia and spermatogenesis. *J Urol* 147: 1615-1617, 1992.
5. Berkmen F. Persistent müllerian duct syndrome with or without transverse testicular ectopia and testis tumours. *Br J Urol* 79: 122-126, 1997.
6. Cohen-Haguenauer O, Picard JY, Mattei MG et al. Mapping of the gene for müllerian hormone to the short arm of human chromosome 19. *Cytogenet Cell Genet* 44: 2-5, 1987.
7. Melman A, Leither E, Perez JM et al. The influence of neonatal orchiopexy upon the testis and persistent müllerian duct syndrome. *J Urol* 125: 856-858, 1981.
8. Eastham JA, McEvoy K, Sullivan R et al. A case of simultaneous bilateral nonseminomatous testicular tumors in persistent müllerian duct syndrome. *J Urol* 148: 407-408, 1992.
9. Buchholz NP, Biyabani R, Herzig MJU et al. Persistent müllerian duct syndrome. *Eur Urol* 34: 230-232, 1998.
10. Erk A, Özeren S, Özbay O et al. Persistent müllerian duct syndrome: A case report. *J Reprod Med* 44: 135-138, 1999.