

1-1-2005

Investigating Toxic Effects of the HIV-RT Inhibitor 2-Phenoxymethyl-5-Chloro-Benzimidazole on Rat Liver

YEŐİM UĐUR

AYŐEGÜL AKBAY YARPUZLU

AYŐEGÜL NAZİKOĐLU

ESİN AŐAN

İL KAY YILDIZ

See next page for additional authors

Follow this and additional works at: <https://journals.tubitak.gov.tr/medical>



Part of the [Medical Sciences Commons](#)

Recommended Citation

UĐUR, YEŐİM; YARPUZLU, AYŐEGÜL AKBAY; NAZİKOĐLU, AYŐEGÜL; AŐAN, ESİN; YILDIZ, İL KAY; and KELEŐ, ŐÜKRÜ (2005) "Investigating Toxic Effects of the HIV-RT Inhibitor 2-Phenoxymethyl-5-Chloro-Benzimidazole on Rat Liver," *Turkish Journal of Medical Sciences*: Vol. 35: No. 1, Article 2. Available at: <https://journals.tubitak.gov.tr/medical/vol35/iss1/2>

This Article is brought to you for free and open access by TÜBİTAK Academic Journals. It has been accepted for inclusion in Turkish Journal of Medical Sciences by an authorized editor of TÜBİTAK Academic Journals. For more information, please contact academic.publications@tubitak.gov.tr.

Investigating Toxic Effects of the HIV-RT Inhibitor 2-Phenoxymethyl-5-Chloro-Benzimidazole on Rat Liver

Authors

YEŐİM UĐUR, AYŐEGÜL AKBAY YARPUZLU, AYŐEGÜL NAZİKOĐLU, ESİN AŐAN, İLKAY YILDIZ, and ŐÜKRÜ KELEŐ

EXPERIMENTAL / LABORATORY STUDIES

Investigating Toxic Effects of the HIV-RT Inhibitor 2-Phenoxymethyl-5-Chloro-Benzimidazole on Rat Liver

Yeşim UĞUR¹, Ayşegül AKBAY YARPUZLU², Ayşegül NAZİKOĞLU¹, Esin AŞAN¹, İlkay YILDIZ³,
Şükrü KELEŞ⁴

¹Department of Histology-Embryology, Faculty of Medicine, Hacettepe University, Ankara - Turkey

²Department of Health Education, Faculty of Health Education, Ankara University, Ankara - Turkey

³Department of Pharmaceutical Chemistry, Faculty of Pharmacy, Ankara University, Ankara - Turkey

⁴Institute of Biotechnology, Ankara University, Ankara - Turkey

Received: September 17, 2004

Abstract: The aim of this study was to investigate the toxic effects of the human immunodeficiency virus- reverse transcriptase (HIV-RT) inhibitor 2-phenoxymethyl-5-chlorobenzimidazole on rat liver at the light microscopic level to gain an insight into possible effects in human subjects. To do this, an animal experimental model was constructed and rats were divided into single injected rat (SIR) and multiple injected rat (MIR) groups, as well as single and multiple solvent dimethylsulfoxide (DMSO) injected controls and an untreated control. Cellular heterogeneity was observed in a non-prominent way in the SIR group (prominent in only one area) and very prominently in the perivenous areas in the MIR group. In almost all groups, the hepatocytes were lightly to moderately stained but were moderately to darkly stained in the MIR group, in addition to a propensity to be lighter in the periportal area. In the single solvent injected and the multiple solvent injected groups hepatocyte cytoplasm displayed a granular appearance, whereas in the experimental groups (SIR and MIR) both granular and patchy appearances were seen. In the multiple injected solvent and chemical groups, some hyaline-like material was seen within hepatocyte cytoplasm. In all groups perivenous hepatocyte nuclei were both normal and large but periportal ones were larger. Especially in the MIR group more nuclei were large in both areas. In each group lipid droplet-filled (differing in size) hepatocytes were present, especially in the perivenous area, but also in the periportal area although less prominently.

More periportal hepatocytes contained lipid droplets in the MIR group. In all groups sinusoids were only slightly dilated especially peripherally in both regions. Endothelial cells were normal in all groups. They were usually undetectable in the MIR and multiple solvent injected groups, especially in the perivenous area whereas they seemed bulging towards the lumen in the SIR and single solvent injected groups. Kupffer cells were usually normal in morphology and number, but in the MIR and multiple solvent injected groups they were greater in number and displayed a bulging appearance. Also in the MIR group the number of Kupffer cells was higher. The space of Disse was normal in the multiple solvent injected group but was enlarged in the other groups. In almost all groups low to moderate amounts of lipid were seen within the dilated sinusoids, especially in the peripheral periportal area. The multiple solvent injected group displayed more lipid within the sinusoids. Bile canaliculi and ducts were normal in all groups. In the SIR and multiple solvent injected groups plasma cells and lymphocytes were seen within the connective tissue of the portal area, being more numerous in the multiple solvent injected group.

The cellular toxic effects of 2-phenoxymethyl-5-chlorobenzimidazole on rat liver morphology should be further investigated at the subcellular and molecular levels.

Key Words: AIDS, HIV-RT inhibitor, hepatic toxicity, histopathology, 2-phenoxymethyl-5-chloro-benzimidazole, dimethylsulfoxide

Introduction

2-Phenoximethyl-5-chloro-benzimidazole is a substituted benzimidazole that has been synthesized by our team. Benzimidazoles and their substituted

derivatives have been used as antimicrobials in the treatment of *Pneumocystis pneumonia* (1) and *Helicobacter pylori* (2), in plant protection (3), as antivirals against cytomegalovirus (4), as antiparasitics

against *Giardia lamblia* (5) and some Microsporidia species such as *Encephalitozoon hellem*, *Encephalitozoon intestinalis* (6) by binding to the cytoskeleton (7). Some have also been shown to be inhibitors of human immunodeficiency virus- reverse transcriptase (HIV-RT) (8) and adenosine deaminase (ADA) (9).

Even though there are some studies with other substituted benzimidazoles, neither LD50 nor pharmacotoxicity, pharmacokinetic or pharmacodynamic studies have been performed with 2-phenoximethyl-5-chloro-benzimidazole and from a chemical perspective, and the purity in solution with respect to any possible isomeric forms is also unknown .

This study was intended to observe some fast and accumulative effects of 2-phenoximethyl-5-chloro-benzimidazole administration to be observed at the microscopic level that may lead to hepatotoxicity.

Materials and Methods

Chemicals

The method of synthesis of the 2-phenoximethyl-5-chloro-benzimidazole compound, which has been shown to have antimicrobial activity, is as follows : 0.01 mol (1.42 g) of 4-chloro-o-phenylene diamine was mixed with 0.01 mol (1.52 g) of phenoxy acetic acid. The mixture was heated at 100 °C for 5 h in 15 ml of 6N HCl under continuous cooling. Water was added to the reaction mix until cooled. The mixture was alkalized with sodium bicarbonate and the precipitate was washed after filtration, followed by a clean-up through product colon chromatography. The product was recrystallized from an ethanol-water mixture.

Animals and Experimental Design

Wistar Swiss albino male rats (*Rattus rattus*) weighing 300-350 g were housed in the Experimental Animals Facility of Ankara University Faculty of Medicine. The rats were housed in standard stainless steel cages. All animals were kept under the same environmental conditions at a room temperature of 20 ± 2 °C in a 12-h light-dark cycle, food and water were provided ad libitum. Ten male rats were divided randomly into 4 groups. The first group consisted of 3 rats receiving intramuscular injections of 5 mg/kg of 2-phenoxymethyl-5-chloro-benzimidazole dissolved in dimethylsulfoxide (DMSO) in a total volume of 0.5 ml, once only on day 1 (SIR group). The second

group consisted of 4 rats receiving intramuscular injections of 5 mg/kg of 2-phenoxymethyl-5-chloro-benzimidazole dissolved in DMSO, in 7 injections on days 1, 3, 5, 7, 9, 11 and 13 (MIR group). The third group consisted of 1 rat receiving 0.5 ml of DMSO alone (single solvent injected group) as a single injection on day 1, and group 4 (multiple solvent injected group) consisted of 1 rat receiving 7 injections on days 1, 3, 5, 7, 9, 11 and 13. Finally; the fifth experimental group consisted of a single rat without any intervention. All animals were fed with standard rat chow. At the end of the treatment period, the animals were anaesthetized with ethanol and were killed by decapitation followed by partial excision of the livers.

Tissue Samples

Tissue samples were fixed in 2% glutaraldehyde-phosphate buffered saline (PBS) solution overnight. After a PBS wash, post-fixation was applied in 1% osmium tetroxide buffer solution for 1.5 h. Again after a PBS wash samples were dehydrated. After being processed in propylene oxide for half an hour, they were left in araldite (Araldite CY212 Kit) - propylene oxide mixtures at ratios of 1:3, 1:1 and 3:1 for 0.5, 1 h and overnight respectively. Then samples were processed in pure Araldite for 1 h and embedded in Beem capsules. They were left to polymerize in an incubator at 60 °C for 48 h. Semi-thin sections were cut and stained with methylene blue. Sections were examined under a light microscope (Olympus BH-2) by 3 histologists working separately and photographs were taken representing each group. Tables summarizing the findings of each investigator were constructed and conflicting results were re-evaluated until consensus was reached.

Results

Group 1 (SIR):

The hepatocytes in both the perivenous (around the central vein) and periportal (neighboring portal area) areas were lightly to moderately stained. Their borders were only sometimes clearly identified. Almost no heterogeneity was observed. In both areas, a patchy cytoplasmic appearance was displayed within hepatocytes. In addition some granular appearance was seen in periportal cells. In the perivenous area, both normal and large nuclei were observed, but in the periportal area mostly large-nucleated, lightly colored cells were seen. In

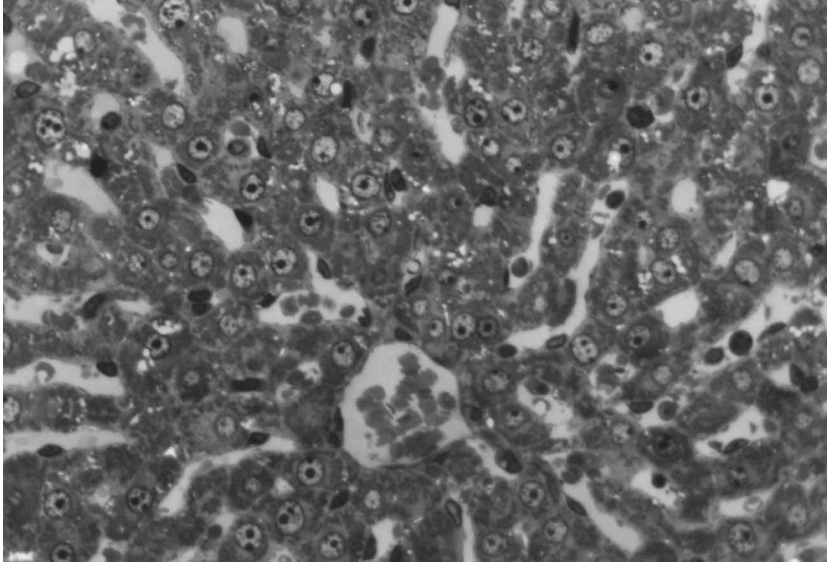


Figure 1. View of the perivenous area from an animal belonging to group 1. Methylene blue, original magnification X 40.

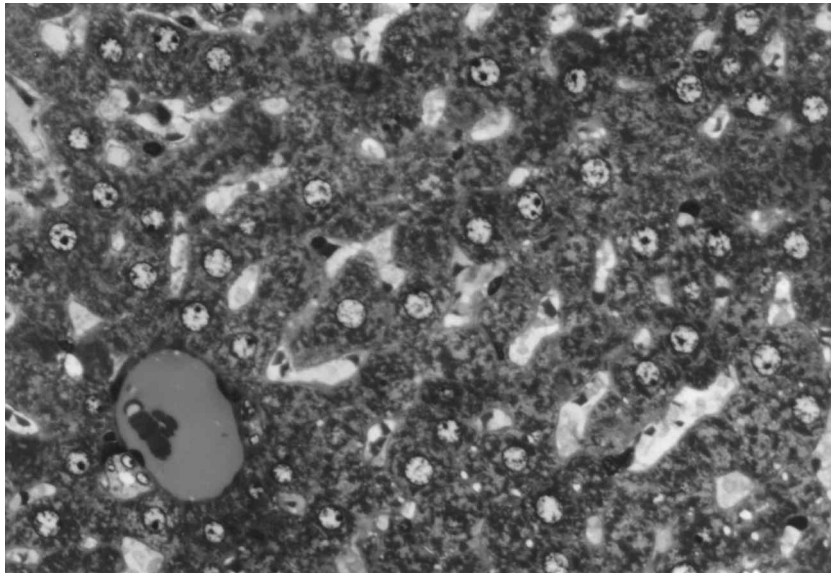


Figure 2. View of the periportal area from an animal belonging to group 1. Methylene blue, original magnification X 40. .

the perivenous area, giant lipid droplets were seen within the hepatocytes, but periportal there were only non-prominent amounts of lipid within some hepatocytes only. In both areas, sinusoids were normal or only slightly dilated peripherally. The endothelium was normal, but sometimes bulged towards the lumen in the perivenous area. In this area, Kupffer cells were slightly increased in number. Periportal some normal-appearing Kupffer

cells were seen. In the perivenous area, sinusoidal contents were normal, or slight to moderate amounts of lipid were observed within the dilated ones. Periportal, the same was observed, but in a peripheral region only, and sinusoids were filled with prominent amounts of lipid. Bile canaliculi were normal. Some plasma cells were seen within the connective tissue of the portal area.

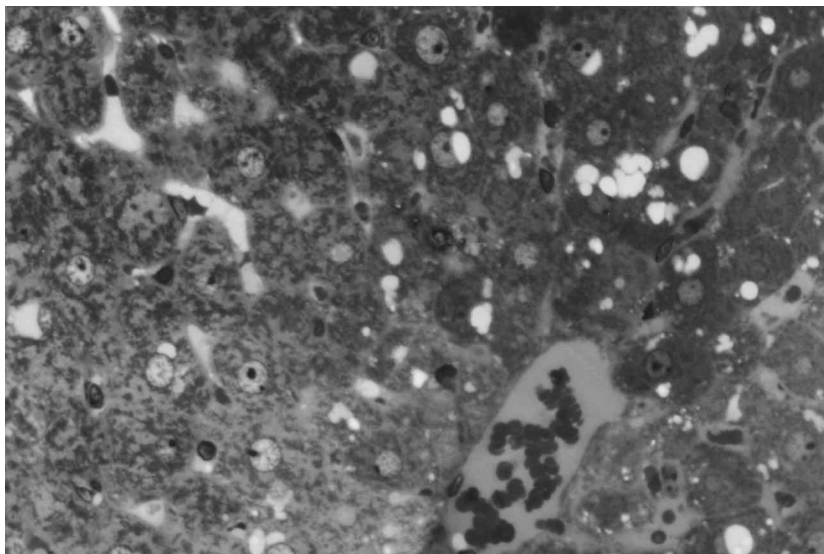


Figure 3. View of the perivenous area from an animal belonging to group 2. Methylene blue, original magnification X 40.

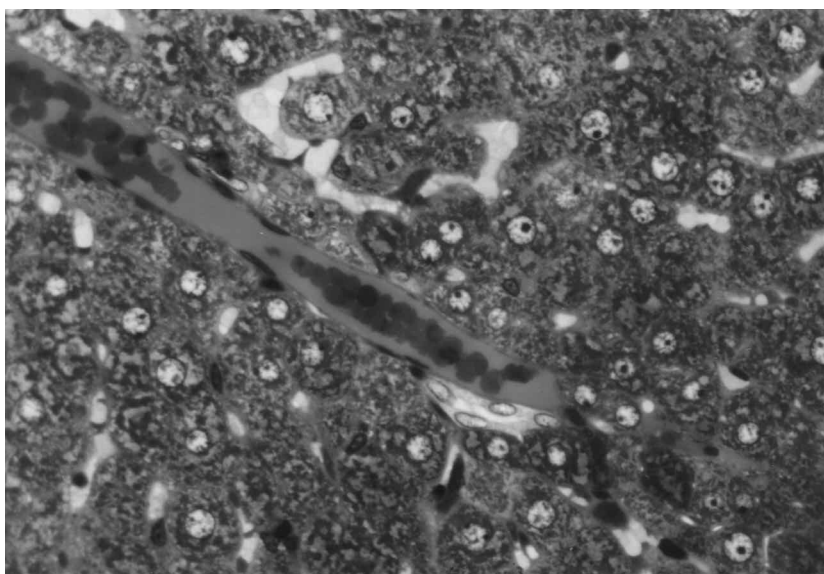


Figure 4.: View of the periportal area from an animal belonging to group 2. Methylene blue, original magnification X 40.

Group 2 (MIR):

The hepatocytes were moderately to darkly stained in both areas. In the perivenous area, darker cells were peripherally located and very prominent peripheral heterogeneity was detected. However, periportal heterogeneity was unremarkable and the cell borders were only sometimes clearly identified. In the perivenous area, a granular cytoplasmic appearance was observed in

hepatocytes displaying hyaline-like material, but a patchy appearance was seen in moderately stained lighter cells. Periportal, both types were seen. In both areas mostly large-nucleated cells were observed. Especially in the immediate vicinity of the portal area the nuclei were very large. Around the central vein and near to it, many hepatocytes were filled with large lipid droplets. Periportal, there were wholly lipid droplet-filled cells,

and these were large ones in peripherally located hepatocytes. In the perivenous area, hyaline-like material was seen in peripheral hepatocytes. This material was bulky in darkly stained cells. Periportally, there were many hyaline-like material containing hepatocytes, again located peripherally. Sinusoids were normal or slightly dilated, but were usually undetectable in the perivenous area. Sometimes they resembled as a cavity. Periportally they were again normal and only some peripherally located ones were slightly dilated. Endothelial cells were normal in both areas, but the endothelium occasionally appeared as if it were detached. Sometimes the endothelium was not detectable at all in the perivenous area. Some normal Kupffer cells were again seen in both areas. The space of Disse was enlarged in both areas, and periportally especially this was very prominent. In the perivenous area, small or moderate amounts of lipid were seen within some sinusoids. The cavity-like sinusoids displayed no lipids. In the periportal area, in a peripheral region only, sinusoids contained a small amount of lipid. Bile canaliculi were normal.

Group 3- Single injection of DMSO

The borders of hepatocytes were usually clearly identified in both areas. More peripherally located in these regions, non-prominent cellular heterogeneity was observed. Both normal and large nuclei were seen in these 2 areas. In the perivenous area, some hepatocytes were filled with lipid. Periportally, the hepatocytes were lighter in color. They displayed a granular cytoplasmic appearance and a few of them displayed hyaline-like material. In one area only, there was stasis, sinusoids were dilated and filled with erythrocytes, and prominent cellular heterogeneity was observed. In this area, lightly colored hepatocytes displayed hypertrophy and a few lipids whereas darker ones were smaller and displayed moderate amounts of hyaline-like material. No sinusoidal dilatation was seen in either area. Sometimes, in the perivenous area, non-prominent dilatation was observed. The endothelium was normal and no Kupffer cells were detected. Periportally, the space of Disse was enlarged. No lipid was seen within the sinusoids.

Group 4- Consecutive injections of DMSO

The color of hepatocytes were light to moderate in both areas. Cellular borders were sometimes clearly identified. A patchy cytoplasmic appearance was displayed within the hepatocytes in the perivenous area, whereas a

both patchy and granular appearance was seen periportally. Both normal and large nuclei were observed in the perivenous area, but mostly large nuclei were seen in the periportal area, especially peripherally. In the perivenous area, moderate to large lipid droplets were present inside hepatocytes and hyaline-like material was observed very prominently in many cells especially peripherally. However, only some hepatocytes displayed hyaline-like material in them periportally. Sinusoids were mostly peripherally dilated in both areas. The endothelium was normal, sometimes bulging towards the lumen in dilated ones. Some Kupffer cells were seen in both areas, and were bulging in the perivenous area. The space of Disse was enlarged in the perivenous area. In this area, there was usually no lipid within the sinusoids, and only a little was observed in peripheral ones. Periportally, peripheral sinusoids especially were filled with lipids. Some plasma cells and lymphocytes were seen within the sinusoids of both areas. Bile canaliculi were normal.

Group 5:

In the perivenous area, cell borders of hepatocytes were not clearly identified and no cellular heterogeneity was observed. A blurred cytoplasmic granular appearance was displayed within the hepatocytes. Hepatocyte nuclei were smaller compared to those in the periportal area. Nucleoli were not prominent either. Only a few large nuclei were seen. Near the central vein, some wholly lipid droplet-filled hepatocytes were present. Some of them were filled with large lipid droplets. They had small and heterochromatic nuclei. Sinusoids were dilated and filled with lipid globules. The endothelium was normal and usually undetectable. Some bulging Kupffer cells were observed. The space of Disse was usually undetectable. Some lymphocytes were seen within sinusoids. Periportally, the borders of hepatocytes were only sometimes clearly identified and they were lightly colored. No cellular heterogeneity was observed. Hepatocyte cytoplasm displayed a granular appearance. Their nuclei were large and nucleoli were prominent. Sinusoids were dilated, but immediately neighboring the portal area they were not dilated. Approaching the periphery, sinusoids gradually became dilated and filled with lipids. However, some sinusoids displayed no lipid in them. The endothelium was normal and usually undetectable. Some extremely bulging Kupffer cells were present. The space of Disse was detectable but not extremely enlarged. Some suspicious endothelial

detachment was observed within some sinusoids. Within the connective tissue of the portal area, and especially near the bile duct, some plasma cells and lymphocytes were seen. Some lymphocytes were also present within the sinusoids.

Discussion

Normally hepatocytes have well defined plasma membranes differentiated into basolateral and bile canalicular domains. In this study, in almost all groups the cell borders of hepatocytes were only sometimes clearly identified, which may be because of late or poor fixation due to extended excision procedure or really representing the onset of a toxic effect. As this was seen in all groups without exception including the single dose injected groups, and no intensification was observed in the multiple-exposed groups, it is unlikely to be because of any toxic effect. In our study, longest exposure to the administered agents was limited to 15 days and so possible late effects can not be underestimated. In normal liver, depending on differential oxygen gradient, metabolic activity and distribution of enzymes there is a zonal distribution of hepatocytes and accordingly hepatocellular damage, and so hepatocellular heterogeneity is an expected finding. In our study, prominent perivenous peripheral heterogeneity was observed in group 2, possibly simply indicating to higher metabolic activity of hepatocytes exposed to multiple doses of the chemical + solvent. In almost all groups, the hepatocytes were lightly to moderately stained but were moderately to darkly stained in group 2, again pointing to the differential organization of organelles depending on long exposure to the administered agents. Hepatocyte cytoplasm contains fine basophilic granules representing rough endoplasmic reticulum and glycogen usually gives a reticulated, foamy appearance to the cytoplasm. In group 5 and the single-injected rats of groups 3 and 4 hepatocyte cytoplasm displayed a granular appearance, whereas in other groups both granular and patchy appearances were seen. This reflects the differential reorganization of the synthetic machinery of hepatocytes, possibly leading to new gene transcription and expressions of their products, which were as expected in the normal and single injected solvent groups, pointing to a difference in chemical-administered groups independent of the number of administrations. Hepatocyte nuclei vary in size. In all groups, perivenous hepatocyte nuclei were

both normal and large but periportal ones were larger, suggesting a forthcoming response in zone 3 hepatocytes of the liver acinus. Especially in group 2 more nuclei were large in both areas, indicating a possible transcriptional inductive activity in the longest chemical exposed group, in contrast to its anti-proliferative activity, and the fact that unexplained mitoses of hepatocytes as an innocent and common finding in normal livers must not be forgotten. Therefore, further studies are needed to determine longer-term effects of this agent, if any. A few vacuoles are common in normal hepatocytes. Lipofuscin is seen in varying amounts as light brown granules especially in zone 3 of the liver acinus, and accumulates along the bile canaliculi. Focal steatosis involving small groups of hepatocytes, fat globules and undefined pigmentation are other innocent hepatic lesions. In each group lipid droplet-filled (differing in size) hepatocytes were present especially in the perivenous area but also in the periportal area being less prominent than in normal livers. More periportal hepatocytes contained lipid droplets in group 2 which can be interpreted as a metabolic difference related to the longest exposure to the chemical being of little importance. Observation of hyaline-like material in some

hepatocytes randomly seen in some groups can be interpreted as undefined pigmentation. Dilatation of the sinusoidal and perisinusoidal spaces is of little significance in postmortem human livers. At both autopsy and biopsies, dilatation of sinusoids in zone 3 is commonly seen. In our study, in all groups sinusoids were only slightly dilated especially peripherally in both regions as in normal livers. Endothelial cells were normal in all groups. They were usually undetectable in groups 5 and 2, especially in the perivenous area, whereas they bulged towards the lumen in group 1 and the multiple injected rat of group 4. These findings reflect the random appearance and morphology of endothelial cells in different groups indicating no group-specific property and no relation can be proposed or attributed to single, multiple injection, chemical or non-chemical groups. Normal Kupffer cells have a bean-shaped nucleus and plump cytoplasm. Kupffer cells are more numerous near the portal area and respond to injury with proliferation and enlargement. Non-specific reactive hepatitis is characterized by activation of sinusoidal lining cells. In our groups, Kupffer cells were usually normal in morphology and number but in group 5 they were greater in number

and displayed a bulging appearance. As nothing was administered to the animal in this group, this finding must be interpreted inversely as a minor decrease in the experimental groups, and this decrease can be attributed to the anti-proliferative activity of the chemical in the chemical-administered groups and indicates that any minor toxic effect causing proliferation of Kupffer cells might have been hidden. The bulging appearance of Kupffer cells observed in the multiple-injected rat in group 4 may indicate a normal, non-hidden response in the late solvent group. In group 1, the number of Kupffer cells was slightly higher which may point to an early normal response seen before anti-proliferative activity is dominant. The space of Disse is not discernible in well-fixed normal human biopsy material, but in post mortem liver as hepatocytes shrink and pericellular edema develops the space becomes more conspicuous. In autopsy liver specimens dilation of sinusoids and the space of Disse with prominent endothelial and Kupffer cells is commonly seen. The space of Disse was normal in group 5 but seemed enlarged in the other groups, which can be interpreted as a normal or minor pathological condition when compared to autopsies and group 5, respectively. However, the fact that any autopsy takes place after abnormal (involving tissue damage) death must be remembered and not be considered normal. In almost all groups few to moderate amounts of lipid were seen within the dilated sinusoids especially in the peripheral periportal area. Group 5 displayed more lipid within the sinusoids which reflects the lipid-dissolving activity of the solvent DMSO administered in the remaining groups. Bile canaliculi and canals of Hering are not discernible on routine sections of normal liver. In our study, bile canaliculi and ducts were normal in all groups. Chronic inflammatory cells replacing a few necrotic hepatocytes are not unusual in otherwise apparently normal livers. With aging, the portal area exhibits a

higher number of mononuclear inflammatory cells. In human biopsy specimens removed at the end of long surgical procedures clusters of neutrophils are seen as a result of minor trauma. In groups 5 and 1 some plasma cells and lymphocytes were seen within the connective tissue of the portal area, being greater in number in group 5. Again this may be interpreted as the time-dependent yet non-induced anti-proliferative activity of the chemical for group 1, but this theory can not be applied to the solvent groups, because it is clearly demonstrated that culture conditions by Chee's medium supplied with dexamethasone and DMSO maintains hepatocytes in a healthy and highly differentiated state (10). Therefore, we did not expect any toxic changes in the solvent groups and our findings supported those in the literature. In conclusion, 2- phenoxyethyl-5-chloro-benzimidazole is suggested to be safe for the liver at the light microscopic level (11). Our study will continue with an investigation at the electron microscopic level and will reveal ultrastructural changes if any. This preliminary study provides basic information about a subject on which further studies can be planned to determine the long term effects of this chemical with an expanded series.

Acknowledgment

Special thanks to Seyhan Özer for his technical assistance.

Corresponding author:

Ayşeğül Akbay Yarpuzlu

Ankara University,

Faculty of Health Education and Institute of Biotechnology

Fatih Caddesi. No.197, 06290, Keçiören, Ankara - Turkey

e-mail:akbay@diyalup.ankara.edu.tr

References

1. Fishman JA. Treatment of infection due to pneumocystis carinii. *Antimicrobial Agents and Chemotherapy*; 42: 1309-1314,1998.
2. Hof H. Critical annotations to the use of azole antifungals for plant protection. *Antimicrobial Agents Chemother*; 45:2987-2990, 2001.
3. Chiba N, von Zanten SJ, Sinclair P et al. Treating helicobacter pylori infection in primary care patients with uninvestigated dyspepsia: the Canadian adult dyspepsia empiric treatment-helicobacter pylori positive (CADET-Hp) randomised controlled trial. *BMJ*; 324:1012, 2002.
4. Buerger I, Reefschaeger J, Bender W et al. A novel nonnucleoside inhibitor specifically targets cytomegalovirus DNA maturation via the UL89 and UL56 gene products. *J Virol*; 75: 9077-9086, 2001.

5. Adam RD. Biology of giardia lamblia. Clin Microbiol Rev;14: 447-475, 2001.
6. Ridoux O, Drancourt M. In vitro susceptibilities of the microsporidia encephalitozoon cuniculi, encephalitozoon hellem and encephalitozoon intestinalis to albendazole and its sulfoxide and sulfone metabolites. Antimicrob Agents Chemother; 42: 3301-3303,1998.
7. Morrissette NS, Sibley LD. Cytoskeleton of ampiccomplexon parasites. Microbiol Mol Biol Rev; 66:21-38, 2002.
8. Akbay A, Ören İ, Temiz-Arpacı Ö et al. Synthesis and HIV-1 reverse transcriptase inhibitor activity of some 2,5,6-substituted benzoxazole, benzimidazole, benzthiazole and oxazolo (4,5-b) pyridine derivatives. ArzneimForschDrugRes; 53: 266-71, 2003.
9. Yarpuzlu Akbay A, Yıldız İ, Temiz Arpacı Ö et al. Adenosine deaminase inhibitor activity of some benzoxazole, benzimidazole and oxazolo (4,5-b) pyridine derivatives. XIII. BİYOTEKNOLOJİ KONGRESİ Bildiriler Kitabı. 25-29 A?ustos 2003 Çanakkale pp.21-26.
10. Arterburn LM, Zurlo J, Yager JD, Overton RM, Heifetz AH. A morphological study of differentiated hepatocytes in vitro. Hepatology; 22: 175-187, 1995.
11. Associated Intestinal Tract Organs, Part 25 Liver, pages: 575-591 in Histology for Pathologists, edited by Sternberg SS. Second edition, Lippincott-Raven Publishers , Philadelphia, 1997.