

1-1-2005

Heterotopic Bone Formation in Upper Midline Abdominal Incision

BUMİN DEĞİRMENCİ

MURAT ACAR

RAMAZAN ALBAYRAK

ALPAY HAKTANIR

AYLİN YÜCEL

See next page for additional authors

Follow this and additional works at: <https://journals.tubitak.gov.tr/medical>



Part of the [Medical Sciences Commons](#)

Recommended Citation

DEĞİRMENCİ, BUMİN; ACAR, MURAT; ALBAYRAK, RAMAZAN; HAKTANIR, ALPAY; YÜCEL, AYLİN; and DİLEK, OSMAN NURİ (2005) "Heterotopic Bone Formation in Upper Midline Abdominal Incision," *Turkish Journal of Medical Sciences*: Vol. 35: No. 3, Article 10. Available at: <https://journals.tubitak.gov.tr/medical/vol35/iss3/10>

This Article is brought to you for free and open access by TÜBİTAK Academic Journals. It has been accepted for inclusion in Turkish Journal of Medical Sciences by an authorized editor of TÜBİTAK Academic Journals. For more information, please contact academic.publications@tubitak.gov.tr.

Heterotopic Bone Formation in Upper Midline Abdominal Incision

Authors

BUMİN DEĞİRMENÇİ, MURAT ACAR, RAMAZAN ALBAYRAK, ALPAY HAKTANIR, AYLİN YÜCEL, and
OSMAN NURİ DİLEK

SHORT REPORT

Heterotopic Bone Formation in Upper Midline Abdominal Incision

Bumin DEĞİRMENCI¹, Murat ACAR¹, Ramazan ALBAYRAK¹, Alpay HAKTANIR¹
Aylin YÜCEL¹, Osman Nuri DİLEK²

¹Department of Radiology, Faculty of Medicine, Kocatepe University, Afyon - Turkey

²Department of General Surgery, Faculty of Medicine, Kocatepe University, Afyon - Turkey

Received: December 30, 2004

Key Words: Ectopic ossification, Abdominal wall, Computed tomography, X-ray.

Heterotopic bone formation in abdominal incisions is a recognized but uncommon sequela of abdominal surgery (1). On the other hand, the formation of ectopic bone is a well recognized complication following arthroplasty of the hip (2). Heterotopic ossification of midline abdominal incision scars is a subtype of myositis ossificans traumatica (3). Ectopic bone formation of midline abdominal incisions may cause regional pain or discomfort in the patient after surgery. Treatment is complete excision with primary closure. Radiologically, it is important to distinguish this benign entity from postoperative complications.

Case Report

In 2003, recurrent tumoral lesions were detected at the operation site and incisional line in the control abdominal computed tomography (CT) examination of a 64-year-old male patient who had had 2 operations previously, one for antral gastric carcinoma 3 years previously and one for local recurrence 1 year previously. In the abdominal CT examination, a bone density lesion, with no relation to xiphoid, was seen in the midepigastic area and on the incisional line (Figure 1a). The lesion was excised because it was causing pain. In the operation, a boomerang-shaped, bony mass 15 x 4.5 cm in size lying between subcutaneous soft tissues and the peritoneum was removed (Figure 1b). The distance was approximately 3.5 cm from the xiphoid process to the

most superior aspect of the bony mass. Microscopically, the lesion consisted of cartilage and mature bone tissue, within which hematopoiesis was present.

Dystrophic calcification of soft tissues is a condition in which there is an abnormal deposition of amorphous calcium. This condition can be found in the calcification of bursae and hematomas, neoplasms, and collagen diseases (2). Traumatic myositis ossificans has been repeatedly reported in the literature. This usually follows a contusion to a muscle caused by a sports injury (4). Ectopic bone formation is a more advanced process than dystrophic calcification and traumatic myositis ossificans. There are definite osteoblastic activity, and cartilaginous and myelogenous elements in the ectopic osseous matrix. The presence of these cartilaginous and bony elements distinguishes this entity from dystrophic calcification (1,5). Histologically the ectopic bone formations are composed of mature bone with marrow and cartilaginous elements surrounded by fibrous tissue (3,6). A striking male prevalence has been noted, and it is estimated that the male-to-female ratio is approximately 10:1 (6).

Ectopic bone formation in midline abdominal surgical scars has been noted to occur only within vertical incisions. In incisions with both horizontal and vertical components, ossification always occurs in the vertical component (1). In our case, abdominal surgery with vertical incisions had been carried out twice. The exact mechanisms of ectopic bone formation are unknown (7).

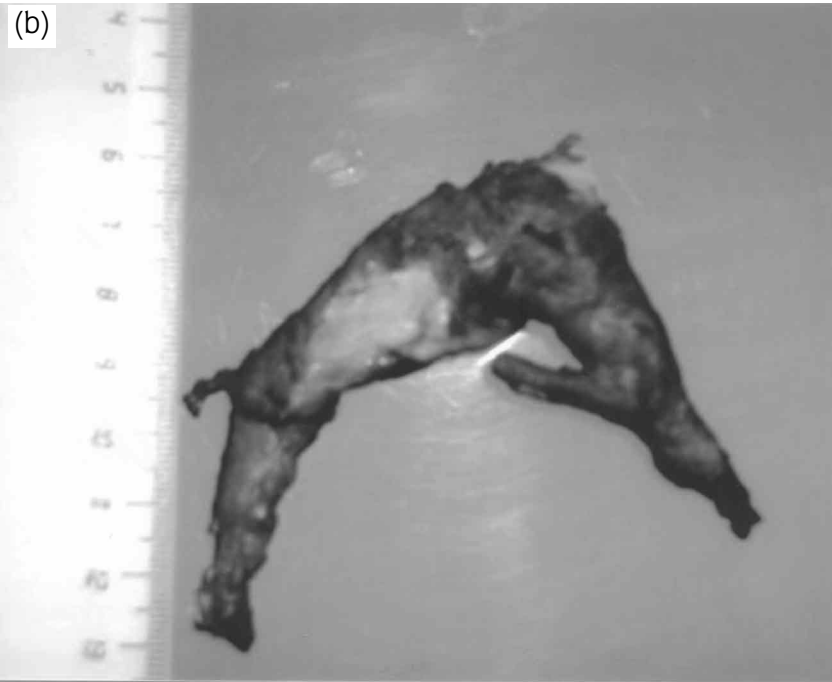
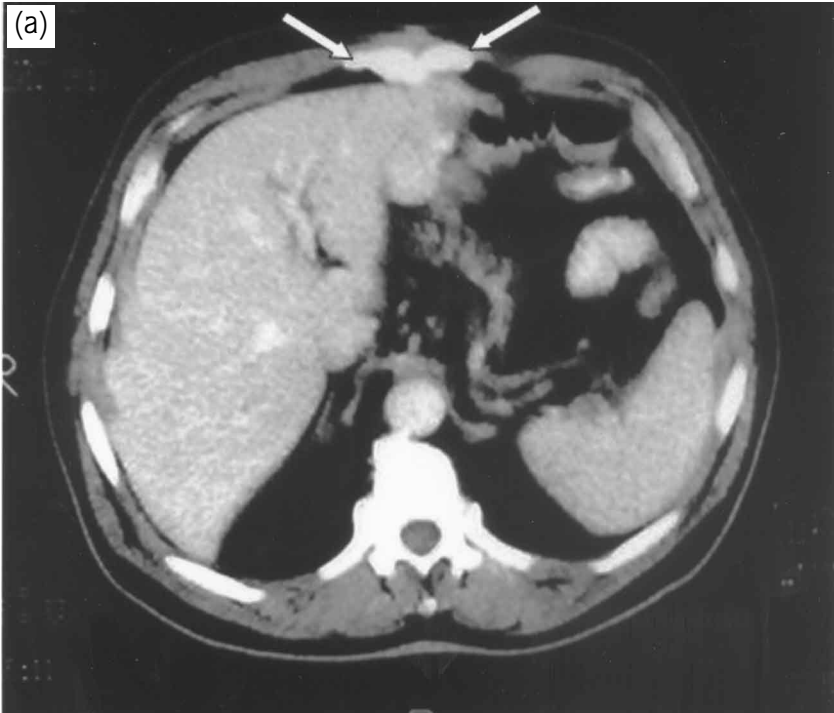


Figure 1. Axial computerized tomography scan of upper abdomen shows bone density lesion in the anterior abdominal wall (a), photograph of surgical specimen is shown (b).

There are 3 prevailing theories for heterotopic ossification of abdominal scars (3). According to the first theory, small particles from the periosteum or perichondrium of the xyphoid process or symphysis pubis are inoculated during surgery into the surgical wound and lead to the formation of bone. This theory is supported by the fact that all reported incidences of heterotopic bone formation are from vertical incisions (1). This theory does not sufficiently explain heterotopic ossification with no close anatomic relationship to osseous tissue. The second theory contends that heterotopic bone formation is a result of immature pluripotent mesenchymal cells differentiating to osteoblasts or chondroblasts as a reaction to local injury. It fails to explain the occurrence in vertical incisions only. The third theory is excessive suture line tension, which may lead to intramuscular implantation and ossification of periosteal particles torn from sites of muscular insertion into bone (1,3).

In general, ectopic bone formation in midline incision scars takes place within a few months and almost always within the first year after surgery. In our patient, heterotopic ossification was observed within 6 months of the second surgical procedure. The size of heterotopic bone varies greatly in the literature, with the largest piece, reported by Pearson and Clark, being 15 x 4.5 cm (8). In our case, the size of heterotopic bone was 15 x 4.5 cm. Imaging of ectopic bone formation in abdominal midline incisions appears typical. Nuclear medicine studies employing Tc pyrophosphate have been reported to show increasing activity within the incision before ossification shows on plain films (8). A lateral plain film will demonstrate a calcific or bone density linear structure

within the abdominal wall (6). Sonography may demonstrate a hyperechoic mass with posterior acoustic shadowing (8). CT can show complete ossifications indicative of the mature phase of the pathologic process and may help in planning surgical resection (9). Ossified components show densities equivalent to bone, with intralesional fatty components representative of marrow sometimes present (3).

Although it is rare, ectopic bone formation in midline abdominal incisions may cause regional pain or discomfort (6). Treatment should consist of complete excision with primary closure. In the literature, 3 cases of recurrent ectopic bone in surgical scars have been reported. In our case, no recurrence was observed in the 3 months following excision of the ectopic bone. Recurrent ectopic bone formation is treated with re-excision and postoperative radiotherapy. Non-steroidal anti-inflammatory medication can be used to prevent recurrent heterotopic bone formation (1).

Radiologically, it is important to distinguish this benign entity from other postoperative complications such as wound infection or foreign bodies and from an intra-incisional primary or metastatic neoplasm. This can be achieved using the typical imaging characteristics of heterotopic bone formation in surgical scars.

Corresponding author:

Bumin DEĞİRMENÇİ

Department of Radiology, Faculty of Medicine,

Kocatepe University, Afyon – TURKEY

E-mail: bd2002tr@yahoo.com

References

1. Reardon MJ, Tillou A, Mody DR et al. Heterotopic calcification in abdominal wounds. *Am J Surg* 173: 145-147, 1997.
2. Barthel HJ. Abdominal wall ectopic bone formation with previous abdominal surgery. *J Fam Pract* 24: 410-411, 1987.
3. Jacobs JE, Birnbaum BA, Siegelman ES. Heterotopic ossification of midline abdominal incisions: CT and MR imaging findings. *Am J Roentgenol* 166: 579-584, 1996.
4. Daoud RA, Watkins MI, Brown G et al. Mature bone metaplasia in abdominal wall scar. *Postgrad Med J* 75: 226-227, 1999.
5. Orava S, Tallila E, Larmi TK. Heterotopic ossification in upper midline abdominal scars. *Ann Chir Gynaecol* 69: 115-118, 1980.
6. Lohela P, Orava S, Leinonen A. Heterotopic bone formation in abdominal midline scars. *Forstchr Röntgenstr* 139: 412-415, 1983.
7. Ledermann HP, Schweitzer ME, Morrison WB. Pelvic heterotopic ossification: MR imaging characteristics. *Radiology* 222: 189-195, 2002.
8. Pearson J, Clark OH. Heterotopic calcification in abdominal wounds. *Surg Gyn Obst* 146: 371-374, 1978.
9. Amendola MA, Glaze GM, Agha FP et al. Myositis ossificans circumscripta: computed tomographic diagnosis. *Radiology* 149: 775-779, 1983.