

1-1-2005

## Salivary Malondialdehyde Levels in Patients with Oral Leukoplakia

YEGANE GÜVEN

MERAL ÜNÜR

KIVANÇ BEKTAŞ

EZEL USLU

AHMET BELCE

*See next page for additional authors*

Follow this and additional works at: <https://journals.tubitak.gov.tr/medical>



Part of the [Medical Sciences Commons](#)

---

### Recommended Citation

GÜVEN, YEGANE; ÜNÜR, MERAL; BEKTAŞ, KIVANÇ; USLU, EZEL; BELCE, AHMET; DEMİREZ, ERDİNÇ; and CAN, ŞULE (2005) "Salivary Malondialdehyde Levels in Patients with Oral Leukoplakia," *Turkish Journal of Medical Sciences*: Vol. 35: No. 5, Article 9. Available at: <https://journals.tubitak.gov.tr/medical/vol35/iss5/9>

This Article is brought to you for free and open access by TÜBİTAK Academic Journals. It has been accepted for inclusion in Turkish Journal of Medical Sciences by an authorized editor of TÜBİTAK Academic Journals. For more information, please contact [academic.publications@tubitak.gov.tr](mailto:academic.publications@tubitak.gov.tr).

---

## Salivary Malondialdehyde Levels in Patients with Oral Leukoplakia

### Authors

YEGANE GÜVEN, MERAL ÜNÜR, KIVANÇ BEKTAŞ, EZEL USLU, AHMET BELCE, ERDİNÇ DEMİREZ, and ŞULE CAN

## CLINICAL INVESTIGATION

# Salivary Malondialdehyde Levels in Patients with Oral Leukoplakia

Yegane GÜVEN<sup>1</sup>, Meral ÜNÜR<sup>2</sup>, Kivanç BEKTAŞ<sup>2</sup>, Ezel USLU<sup>3</sup>, Ahmet BELCE<sup>3</sup>,  
Erdoğan DEMİREZ<sup>2</sup>, Şule CAN<sup>1</sup>

<sup>1</sup>Department of Biochemistry, Faculty of Dentistry, İstanbul University, İstanbul - Turkey

<sup>2</sup>Department of Oral Surgery and Medicine, Faculty of Dentistry, İstanbul University, İstanbul - Turkey

<sup>3</sup>Department of Biochemistry, Cerrahpaşa Faculty of Medicine, İstanbul University, İstanbul - Turkey

Received: April 15, 2004

**Abstract:** Since leukoplakia is a premalignant condition, it is evident that an effective means of control would contribute to reducing the mortality and morbidity of oral cancer. The reactivity of free radicals and singlet oxygen is believed to be an important factor in the pathogenesis of many degenerative diseases including carcinogenesis. Reactive free radicals may damage cells by induction of lipid peroxidation of the polyunsaturated fatty acids. Buege and Aust's method was used for lipid peroxidation analysis.

One way of estimating free radical activity and lipid peroxidation is to determine the concentration of malondialdehyde (MDA) in the body fluids. MDA concentration was determined in a group of 9 patients with oral leukoplakia and 11 healthy subjects as the control group. Mean MDA levels were  $3.835 \pm 1.20$  nM/ml in healthy subjects and  $3.23 \pm 1.33$  nM/ml in patients.

The difference between the two groups was not statistically significant. However, we found this result meaningful for our cases of leukoplakias which were all simple leukoplakias without any sign of dysplasia.

**Key Words:** Leukoplakia, malondialdehyde, saliva, lipid peroxidation

## Introduction

Leukoplakia is a clinical term indicating a white patch or a plaque in the oral mucosa that can not be rubbed off and cannot be characterized clinically as any other disease (1).

It was shown that in addition to tobacco use, alcohol abuse, physical and chemical causative agents, *Candida albicans* infection might play a role in the etiology of leukoplakia (2).

At the time of identification of leukoplakia, biopsy reveals dysplasia in 12 % to 25 % of the patients and carcinoma in 3 % to 10 % (3). Studies indicate that malignant transformation of leukoplakia occurs in a range

of 1 % to 17 %, averaging 4 to 5 % (2). Dysplasia alters the shape, size and organization of the tissue and is occasionally associated with neoplastic transformation (2). On the other hand, some authors believe that leukoplakia of the oral cavity and the vulva are preneoplastic lesions and patients with preneoplastic lesions are at increased risk of developing neoplasia at the lesion tissue site (4,5).

Free radicals can be defined as molecules or molecular fragments with an unpaired electron which imparts certain characteristics to the free radicals such as reactivity (6). Reactive free radicals are able to produce chemical modifications and to damage proteins, lipids, carbohydrates and nucleotids in the tissues (7). Its known

\* This paper was presented as a poster in the 6th European Symposium on Saliva as poster no 5 in Egmond aan Zee, Netherlands between 29 May-1 June 2002.

that free oxygen radicals are probably mediators for tissue damage in neoplastic disease (8).

There are various major routes in which free radicals can interact with neighboring components in cells to disturb their integrity and functions. One of these routes is lipid peroxidation. Reactive free radicals may damage cells by the initiation of lipid peroxidation of the polyunsaturated fatty acids. This has direct effects on the membrane structure and is associated with influences of the products of peroxidation on membrane fluidity, cross-linking, structure and function (6).

A way of estimating free radical activity and lipid peroxidation is to determine the concentration of malondialdehyde (MDA), which is the most widely used test and is an easy initial screening test (9).

Saliva is a diagnostic fluid for many oral and systemic diseases (10,11). In this study we aimed to determine salivary MDA levels, which is an acceptable parameter and the end product of lipid peroxidation of the patients with oral leukoplakia, which is considered as a precancerous lesion.

## Materials and Methods

### Subjects

9 patients ( 6 male, 3 female ) having problems with eating and drinking, especially with hot and spicy foods, applied to our clinic. In their oral examination leukoplakia was identified at different anatomic sites of the oral mucosa. All the patients were smokers of more than 6 years and had no systemic diseases except one with hypertension (Table 1).

The leukoplakia lesions were observed at the lateral borders of the tongue in 5, buccal mucosa adjacent to the commissura in 3 and the ventral surface of the tongue in 1 of the patients. In Figures 1 and 2 of the same patient with leukoplakias on both sides and in Figure 3 another patient with leukoplakia can be seen. Our clinical diagnosis was simple leukoplakia since the patches were regular and smooth surfaced. These persistent white patches were excised after all patients had given informed consent for this study. Biopsies were evaluated histopathologically and all were leukoplakias with hyperkeratosis and acanthosis on the overlying epithelium without dysplasia. The control group was composed of 11 healthy subjects with a mean age of 34.

Table 1. Distribution of patients with leukoplakia.

No	Age	Sex	Location
1	37	F	LBT*
2	47	M	LBT
3	30	M	VST**
4	54	M	LBT
5	43	F	C***
6	41	M	C
7	38	M	LBT
8	46	F	LBT
9	42	M	C

Note that all lesions were simple leukoplakias in clinical diagnosis and their histopathology results showed papillomatosis, hyperkeratinization, acanthosis on overlying epithelium but no sign of dysplasia.

\* LBT: Lateral borders of the tongue.

\*\* VST: Ventral surface of the tongue.

\*\*\* C: Commissura.

### Collection of Saliva Samples

Unstimulated whole saliva was collected over ice. After centrifugation at 4 °C for 10 min at 1200xg it was frozen within an hour at - 20 °C and stored frozen until the analysis.

### Measurement of Salivary MDA Concentration

Buege and Aust's method was used for the lipid peroxidation analysis with MDA. MDA reacts with thiobarbituric acid and lipid peroxidation products, with a red color formed at 535 nm (12).

## Results

As seen in Table 2 mean MDA levels in healthy subjects was  $3.835 \pm 1.20$  nM/ml, while it was  $3.23 \pm 1.33$  nM/ml in the patients. The difference between the two groups was not statistically significant.

## Discussion

Lipid peroxidation can result in membrane disorganization by peroxidizing mainly the highly unsaturated polyunsaturated fatty acids and thereby changing the composition of the polyunsaturated fatty acid and phospholipid fractions. Such changes, and lipid peroxidation itself, are associated with decreases in

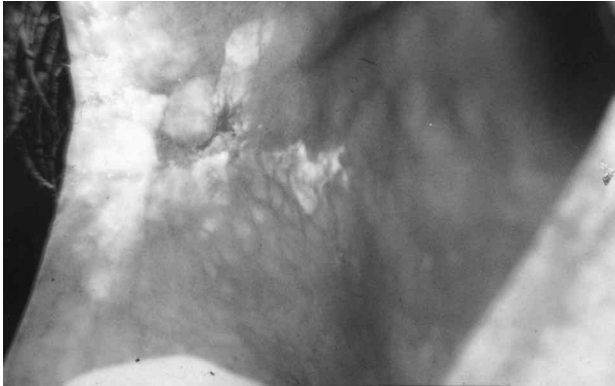


Figure 1. Male patient (age:41) leukoplakia on left commissura.

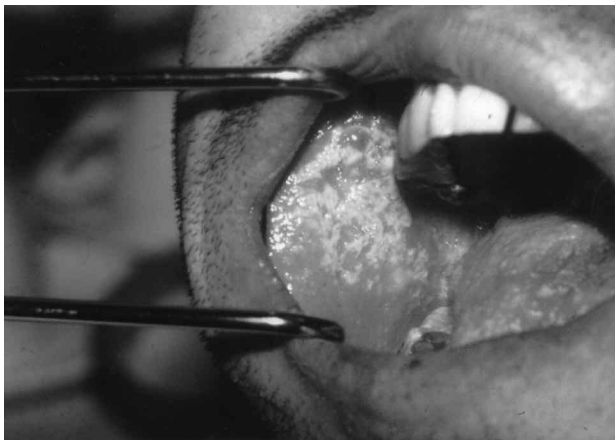


Figure 2. Male patient (age:41) leukoplakia on right commissura.

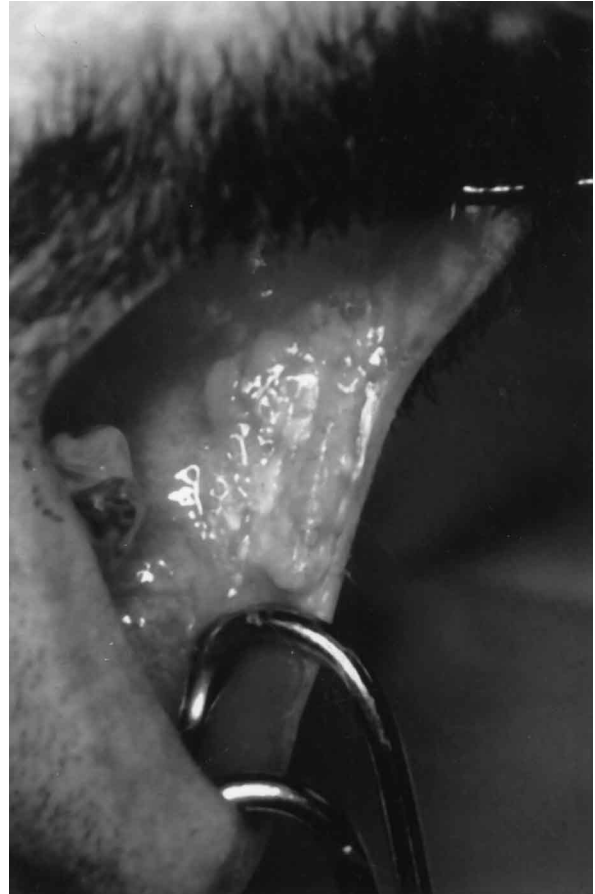


Figure 3. Male patient (age:42) leukoplakia on left commissura.

Table 2. Salivary MDA levels of patients with leukoplakias and the control subjects.

Subjects	N	Mean Age	Salivary MDA Levels (nM/ml)	Statistical Evaluation
Patients with leukoplakia	9	42	3.835 ± 1.20*	NS**
Control group	11	34	3.23 ± 1.33	NS

\* Student t test was used for statistical evaluation.

\*\* NS: Not specific P < 0.5.

membrane fluidity (6) and by crosslinking reactions involving bifunctional aldehydes.

The uncontrolled peroxidation of biomembranes can cause profound effects on membrane structure and function, and may be sufficient to cause cell death (6). Levels of lipid peroxidation are altered in tumour cells (8). For example in a study on a baby hamster kidney cell line and its polyoma-virus-transformed malignant counterpart, the level of lipid peroxidation ( as measured

by HPLC-based determination of MDA ) was higher in transformed cells and the alpha tocoferol content lower, suggesting that the level of lipid peroxidation is increased in the malignant state (13).

Malignant neoplasms can kill the host directly by destruction of vital tissues (5,14). Cells have an atypical, pleomorphic and disorganized, bizzare architecture. There may be numerous mitotic figures and abnormal polarity and configuration. It is known that in

histopathologic sections of leukoplakia with dysplasia, mitotic figures and abnormal polarity increase in accordance with the severity of the disease (14).

In the biopsy results of our study we did not determine dysplasia, so that the function and structure of the cells were normal and peroxidation of the lipids in the membranes was not affected significantly according to MDA levels.

## References

1. WHO Collaborating Center for Oral Precancerous Lesions: Definition of Leukoplakia and related lesions: an aid to studies on oral precancer. *Oral Surg Oral Med Oral Pathol* 46:518-539,1978.
2. Regezi JA, Sciubba J. *Oral Pathology: Clinical-Pathologic Correlations*. WB Saunders Company, Philadelphia 2nd Edition p.104-109, 1993.
3. Epstein J. *Oral Cancer in: Burkett's Oral Medicine* ed. Lynch MA, Brightman VJ, Greenberg MS. Philadelphia: J.B. Lippincott 6th Edition p.462-482, 1971.
4. Maronpot RR. *Chemical Carcinogenesis in Handbook of Toxicology Pathology* ed. Academic Press Inc. p.91-127, 1991.
5. Cawson RA, Eveson JW. *Oral Pathology and Diagnosis*. WB Saunders Company, Philadelphia p.12-23,1987.
6. Slater FT. Free radical mechanisms in tissue injury. *Biochem J* 222:1-15,1984.
7. De Zwart LL, Meerman JHN, Commandeur JNM et al. Biomarkers of free radical damage applications in experimental animals and humans. *Free Radical Biology&Medicine* 26:202-226,1999.
8. Halliwell B, Gutteridge JMC. *Free radicals in biology and medicine*. Oxford University Press Inc. New York 701-707,2000.
9. Draper HH, Haley M. Malondialdehyde determination as index of lipid peroxidation. *Methods Enzymol.* 186:421-431,1990.
10. Hall DH. Protective and maintenance functions of human saliva. *Quintessence International* 24:813-816,1993.
11. Mandel ID. The role of saliva in maintaining oral homostasis *JADA* 119:298-304,1989.
12. Buege JA, Aust SD. Microsomal lipid peroxidation. *Methods Enzymol.* 52:302-310,1978.
13. Goldring CE, Rice-Evans CA, Burdon RH et al. Alpha tocopherol uptake and its influence on cell proliferation and lipid peroxidation in transformed and nontransformed baby hamster kidney cells. *Arch Biochem Biophys* 303:429,1993.
14. Neville BW, Damm DD, Allen CM et al. *Oral maxillofacial Pathology*. WB Saunders Company, Philadelphia 2nd Edition 104-109,1993.

## Corresponding author:

Meral ÜNÜR

Department of Oral Medicine and Surgery,

Faculty of Dentistry,

Istanbul University,

Çapa, İstanbul - Turkey

e-mail: meralunur@yahoo.com