

1-1-2006

Arterial Hypertension Due To Primary Huge Hepatic Hydatid Cyst: A Case Report

RAMAZAN ALBAYRAK

RAFET YİĞİTBAŞI

AYLİN YÜCEL

BUMİN DEĞİRMENCİ

MURAT ACAR

See next page for additional authors

Follow this and additional works at: <https://journals.tubitak.gov.tr/medical>

 Part of the [Medical Sciences Commons](#)

Recommended Citation

ALBAYRAK, RAMAZAN; YİĞİTBAŞI, RAFET; YÜCEL, AYLİN; DEĞİRMENCİ, BUMİN; ACAR, MURAT; and HAKTANIR, ALPAY (2006) "Arterial Hypertension Due To Primary Huge Hepatic Hydatid Cyst: A Case Report," *Turkish Journal of Medical Sciences*: Vol. 36: No. 2, Article 10. Available at: <https://journals.tubitak.gov.tr/medical/vol36/iss2/10>

This Article is brought to you for free and open access by TÜBİTAK Academic Journals. It has been accepted for inclusion in Turkish Journal of Medical Sciences by an authorized editor of TÜBİTAK Academic Journals. For more information, please contact academic.publications@tubitak.gov.tr.

Arterial Hypertension Due To Primary Huge Hepatic Hydatid Cyst: A Case Report

Authors

RAMAZAN ALBAYRAK, RAFET YİĞİTBAŞI, AYLİN YÜCEL, BUMİN DEĞİRMENCİ, MURAT ACAR, and ALPAY HAKTANIR

SHORT REPORT

Arterial Hypertension Due To Primary Huge Hepatic Hydatid Cyst: A Case Report

Ramazan ALBAYRAK¹, Rafet YİĞİTBAŞ², Aylin YÜCEL¹, Bumin DEĞİRMENCI¹,
Murat ACAR¹, Alpay HAKTANIR¹

¹ Department of Radiology, Kocatepe University, Faculty of Medicine, Afyon- Turkey

² Department of Radiology, Cerrahpaşa Faculty of Medicine, Istanbul University, İstanbul - Turkey

Received: November 11, 2005

Key Words: Huge hydatid cyst; Exophytic growth; Arterial hypertension

Hepatic hydatid cysts show exophytic growth in three regions liver capsule, gastrohepatic ligament and peritoneum. The hydatid cyst enlarging through the diaphragm may show thoracic invasion. The cyst enlarging along gastrohepatic ligament may cause exophytic compression of the stomach. Huge cysts, as seen in our patient, enlarging through the peritoneum may also cause rare symptoms because of the intraabdominal mass effect. In this report, we present a huge hepatic cyst which caused a type of renovascular hypertension by compressing and rotating the right kidney and its vasculature in an already left nephrectomized patient.

Case Report

A 55-year-old woman was admitted with the complaint of a palpable mass in the abdomen. At physical examination a painless, fixed and hard mass was detected in the right upper abdomen. She had a past history of splenectomy due to splenic hydatid cyst and a left nephrectomy operation 20 years previously. We could not determine the exact indication of the left nephrectomy. Although she had been using combined, antihypertensive therapy with ACE inhibitors, Ca-channel blocker and Beta-blocker, the blood pressure had been uncontrollable

for 5 years. She had also a history of hospitalization due to hypertensive cerebrovascular attack, leading to right hemiplegia in September 2000. Her blood pressure was 230/140 mmHg on the admission. Abdominal sonography was performed to identify the palpable mass in right upper abdomen. A huge, septated, cystic mass in the right lobe of the liver was detected. This finding was suggestive of hydatid cystic disease. The abdominal computed tomography revealed a huge, multiseptated, thick walled cyst of 15 cm in diameter, occupying almost the whole right lobe of the liver. The cystic mass was compressing the right kidney and displacing the kidney inferiorly and medially. The renal hilus with the vascular pedicle was found to be rotated in a counter clockwise direction (Figure 1). Absence of the left kidney possibly due to a previous operation was also noted. The patient underwent operation and the whole cystic mass was removed (Figure 2). In the early postoperative period, the arterial blood pressure steeply decreased and remained stable at normal levels. The dramatic improvement of blood pressure made us think that the hypertension had developed secondary to the mass effect of the huge cyst of the kidney. During the three years follow up period, the systolic blood pressure was about 140-150 mmHg and diastolic blood pressure was about 80-85 mmHg without any antihypertensive medication.

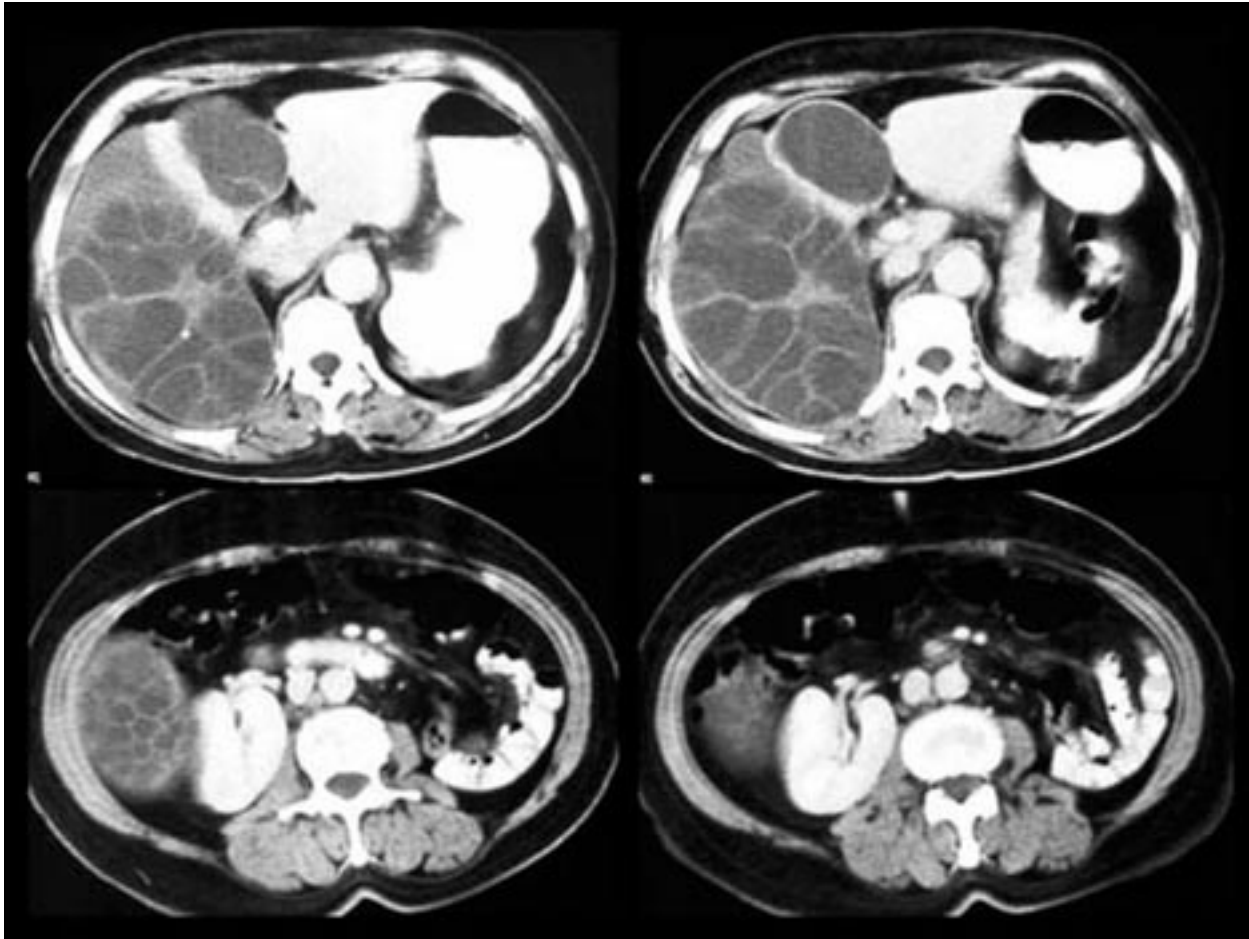


Figure 1. (A-D). Contrast-enhanced CT images.
A, B. Septated huge hydatid cyst located in right lobe of the liver. Right kidney cannot be seen.
C, D. The inferior and medial displacement of right kidney and rotation of its vascular pedicle. Right psoas muscle is compressed. Note the right renal hilum is at the level of third segment of duodenum.

Most patients with a hydatid cyst in the liver are asymptomatic, and its presence becomes evident only when the liver is found to be enlarged or a cystic lesion is noted when the liver is imaged for any other reason (1). On the other hand, complications of hydatid disease such as infection, free rupture, invasion and opening into the biliary tract may also lead to the diagnosis of hepatic hydatid disease (1-3). Hepatic hydatid cysts generally show exophytic growth in three directions: (a) liver capsule (b) gastrohepatic ligament and, (c) peritoneum. The hydatid cyst enlarging through the diaphragm may show thoracic invasion. The cyst enlarging along the gastrohepatic ligament may cause exophytic compression of stomach. Huge cysts, as seen in our patient, may also cause rare symptoms because of the intraabdominal mass

effect. In our patient, we suggest that a huge hepatic cyst caused a type of renovascular hypertension by compressing and rotating the right kidney and its vasculature in an already nephrectomized patient .

In the general literature, arterial hypertension caused by hydatid disease has been reported only in two cases in which the cysts were located in the adrenal glands (4). Escudero et al reported a cyst hydatid located in the left adrenal gland which had caused the left kidney to displace inferiorly, resulting in hypertension. The suggested mechanism of arterial hypertension was similar to ours.

To the best of our knowledge, this is the first case of hepatic hydatid disease causing hypertension in the general literature. The achievement of normal blood pressure after surgical removal of cyst not only clarified

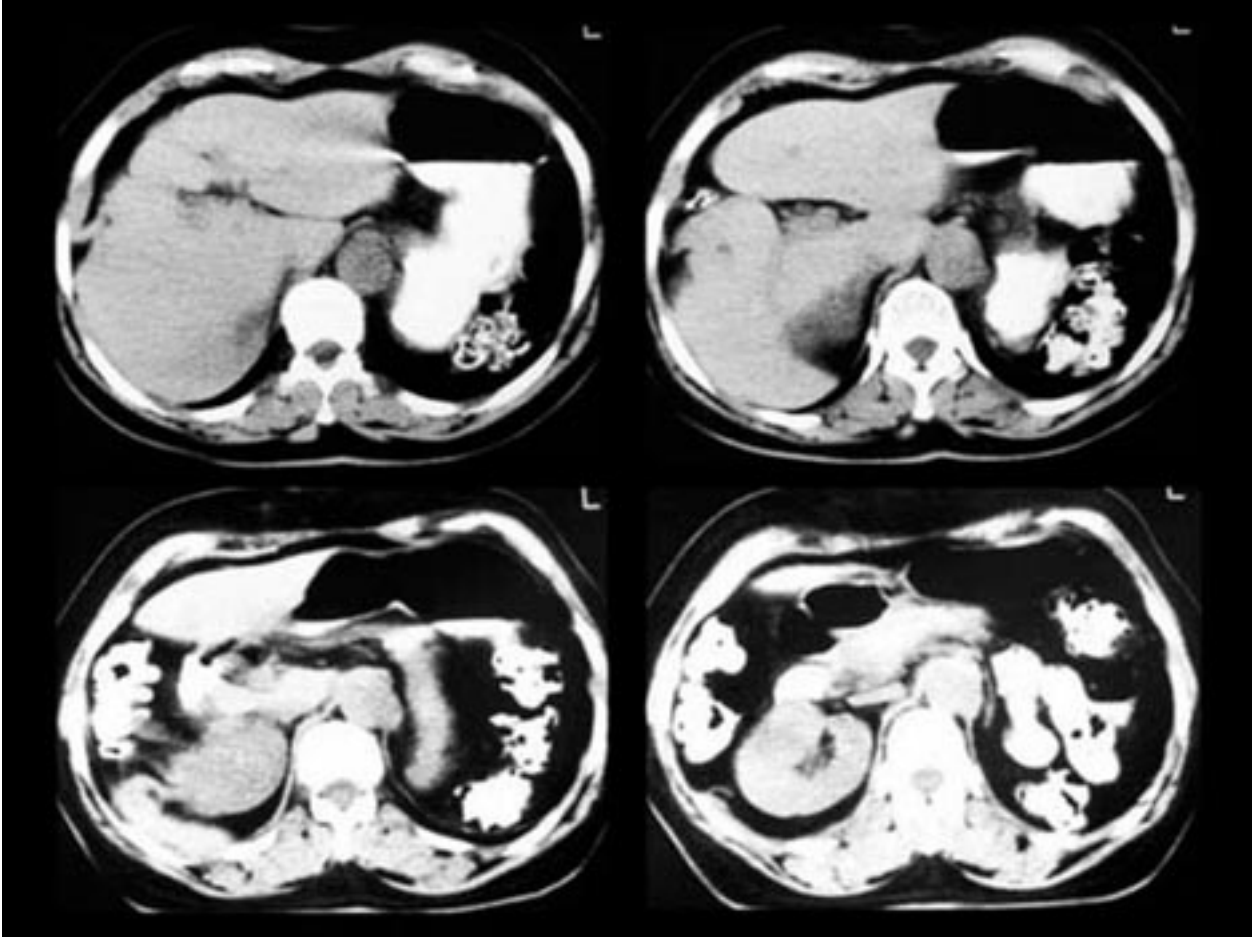


Figure 2. (A-D). Postoperative consecutive noncontrast CT images.
A-D. The right kidney in natural position after surgery. Note the right renal hilum is at the level of gastric antrum.

the etiology of hypertension but provided the cure as well. In conclusion, the mass effect of an enlarged hepatic hydatid cyst should be taken into consideration as one of the rare causes of arterial hypertension in regions where hydatid disease is endemic.

Corresponding author:

Ramazan ALBAYRAK

Department of Radiology, Faculty of Medicine,

Kocatepe University, Afyon - TURKEY

E-mail: rtabayrak@yahoo.com

References

1. Örmeci N, Soykan I, Bektaş A et al. A new percutaneous approach for the treatment of hydatid cysts of the liver. *Gastroenterology* 96: 2225-2230, 2001.
2. Pedrosa I, Saiz A, Arrazola J et al. Hydatid Disease: Radiologic and pathologic features and complications. *RadioGraphics* 20: 795-817, 2000.
3. Men S, Yücesoy C, Edgüer TR et al. Intraaortic growth of hydatid cysts causing occlusion of the aorta and of both iliac arteries: Case report. *Radiology* 213: 192-194, 1999.
4. Escudero MD, Sabater L, Calvete J et al. Arterial hypertension due to primary adrenal hydatid cyst. *Surgery* 131: 894-195, 2002.