

1-1-2007

## A Torsioned and Autoamputated Ovarian Cyst Simulating a Duplication Cyst: A Case Report

SEMA UĞURALP

BİRSEN HARMA

AHMET SİĞİRCİ

NEŞE KARADAĞ

Follow this and additional works at: <https://journals.tubitak.gov.tr/medical>



Part of the [Medical Sciences Commons](#)

---

### Recommended Citation

UĞURALP, SEMA; HARMA, BİRSEN; SİĞİRCİ, AHMET; and KARADAĞ, NEŞE (2007) "A Torsioned and Autoamputated Ovarian Cyst Simulating a Duplication Cyst: A Case Report," *Turkish Journal of Medical Sciences*: Vol. 37: No. 2, Article 9. Available at: <https://journals.tubitak.gov.tr/medical/vol37/iss2/9>

This Article is brought to you for free and open access by TÜBİTAK Academic Journals. It has been accepted for inclusion in Turkish Journal of Medical Sciences by an authorized editor of TÜBİTAK Academic Journals. For more information, please contact [academic.publications@tubitak.gov.tr](mailto:academic.publications@tubitak.gov.tr).

## A Torsioned and Autoamputated Ovarian Cyst Simulating a Duplication Cyst: A Case Report

Sema UĞURALP<sup>1</sup>  
Birsen HARMA<sup>1</sup>  
Ahmet SİĞİRCİ<sup>2</sup>  
Neşe KARADAĞ<sup>3</sup>

**Abstract:** The commonest and most serious complication of neonatal ovarian cysts is torsion. Ovarian torsion leads to loss of the ovary. We report a case of a torsioned and autoamputated right ovarian cyst presenting as a duplication cyst of the intestine in a newborn. An abdominal cystic mass 4.8 × 3.4 cm in diameter was diagnosed in a 36-week-gestation fetus using antenatal ultrasonography (US). The physical examination revealed a mobile abdominal mass in the right upper quadrant. Postnatal US confirmed a cystic mass in the right upper quadrant. Intraoperatively, the ovarian cyst was autoamputated and it was adhered to the antimesenteric edge of the ileum by a fibrotic band. The right ovary could not be found.

Autoamputated ovarian cysts should be considered in the differential diagnosis of mobile abdominal masses with atypical localizations.

**Key Words:** Autoamputation, ovary, torsion, antenatal

### Dublikasyon Kistini Taklit Eden Torsiyone ve Otoampüte Over Kisti: Olgu Sunumu

<sup>1</sup> Department of Pediatric Surgery,  
Faculty of Medicine,  
Turgut Özal Medical Center,  
İnönü University, Malatya - TURKEY

<sup>2</sup> Department of Radiology,  
Faculty of Medicine,  
Turgut Özal Medical Center,  
İnönü University, Malatya - TURKEY

<sup>3</sup> Department of Pathology,  
Faculty of Medicine,  
Turgut Özal Medical Center,  
İnönü University, Malatya - TURKEY

**Özet:** Yenidoğan over kistlerinin en yaygın ve en ciddi komplikasyonu over torsiyonudur. Over torsiyonu over kaybına yolaçar. Biz sağ overi torsiyon sonrasında oto ampute olan ve ince barsağın dublikasyon kisti gibi prezente olan bir yenidoğan rapor ettik. Antenatal 36. haftada yapılan fetal ultrasonografi (US) de 4.8 × 3.4 cm çaplı abdominal kistik tanısı kondu. Postnatal dönemde yapılan US de sağ üst kadranda kistik kitle sebat etmekteydi. İntraoperatif olarak, over kistinin oto ampute olduğu ve fibrotik bir bantla ileum antimezenterik kenarına yapıştığı görüldü. Sağ over bulunamadı.

Atipik lokalizasyonu olan mobil karın kitlelerinde ayırıcı tanıları arasında oto ampute over kistleri düşünülmelidir.

**Anahtar Sözcükler:** Otoampütasyon, over, torsiyon, antenatal

### Introduction

More than 85% of prenatal ovarian cysts have a follicular or luteal origin. Although most neonatal ovarian cysts usually resolve spontaneously (1), they may be complicated by rupture, hemorrhage, or torsion (2). Hemorrhagic cysts almost uniformly result from torsion, and are associated with infarction (3). Many neonatal intra-abdominal cystic lesions are increasingly recognized with the advent of antenatal ultrasonography (US).

We report a case of a torsioned and autoamputated ovarian cyst presenting as a duplication cyst of the intestine in a newborn that was managed with surgical extirpation.

### Case Report

An abdominal cystic mass 4.8 × 3.4 cm in diameter was diagnosed in a 36-week-gestation female fetus on antenatal US. The baby was born vaginally at the 40<sup>th</sup> week of gestation. The physical examination revealed a mobile abdominal mass. Hematological and biochemical investigations were normal.

Postnatal US confirmed a cystic mass 5 × 4 cm in diameter in the right upper quadrant. The abdominal computed tomography (CT) revealed a hypodense, cystic mass

Received: October 30, 2006  
Accepted: March 12, 2007

#### Correspondence

Sema UĞURALP  
Department of Pediatric Surgery,  
Turgut Özal Medical Center,  
Faculty of Medicine,  
İnönü University,  
44069 Malatya - TURKEY

suguralp@inonu.edu.tr

having a thin wall with smooth contours. It extended from the right pelvic area to the inferior side of the liver on the lateral side of bowel segments with the dimensions  $5 \times 3.7 \times 2.5$  cm (Figure 1). The pre-operative diagnosis was enteric duplication cyst.

The baby underwent surgery on her third day of life. Upon exploration, the cyst was approximately 5 cm in diameter, having a thin wall. It was filled with hemorrhagic fluid, and it was adhered to the antimesenteric edge of the ileum by a fibrotic band. There was a white nodule 5 mm in diameter on the surface of the cystic mass. The right ovary and right ovary proprium could not be found. The uterus, fallopian tubes, and left ovary were normal. Following the extirpation of the cystic mass, the baby was discharged on the postoperative fourth day without any complication.

On histopathological examination, it was demonstrated that the necrotic and calcified ovarian tissue (Figure 2) was covered with a single layer flattened epithelial wall (Figure 3).

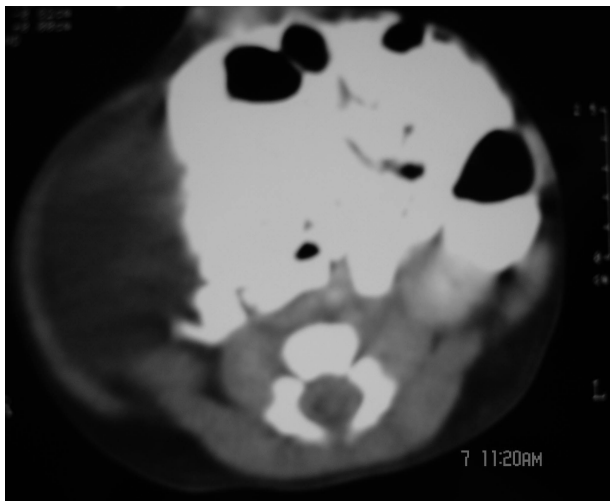


Figure 1. Cystic abdominal mass on the lateral side of bowel segments.

## Discussion

The ovarian cyst is the most common intra-abdominal cystic lesion in the female neonate (3). The commonest and most serious complication of neonatal ovarian cysts is torsion, which occurs more frequently in large cysts. Autoamputation of ovarian cysts appears rarely, and only a few cases are reported in the literature (4-8). Other

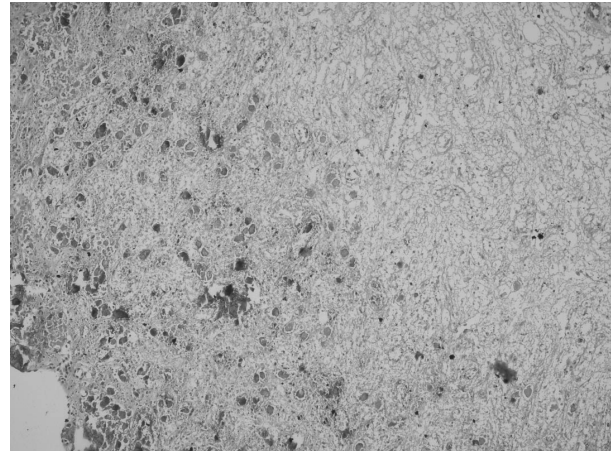


Figure 2. Widespread ischemic necrosis and dystrophic calcification in the ovary (HE  $\times$  100).



Figure 3. The ovarian cyst wall (HE  $\times$  200).

complications are rupture of ovarian cysts with subsequent peritonitis and/or abscess formation (2).

The ultrasonographic appearance and size of an ovarian cyst vary. It appears anechoic with an imperceptible wall if the cyst is uncomplicated by torsion or hemorrhage, but when it is complicated the cyst contains fluid-debris level, a retracting clot, septae, or is completely filled with echoes, producing a solid mass-like appearance (3). US often cannot differentiate among the various intra-abdominal cystic lesions. Other cystic structures that may be confused with ovarian cysts are mesenteric or enteric cysts, meconium cysts, hydrometrocolpos, urachal cysts, bowel atresia, renal cysts, and hydronephrosis (3,9). Mesenteric and omental

cysts may be the most difficult to distinguish from an ovarian cyst, and early surgery is indicated if the diagnosis is not clear. In our patient, the preoperative diagnosis was duplication cyst of the intestine according to US and/or CT findings. The cystic mass had a thin wall with smooth contours, and was hypodense. Its localization was the right upper and lower quadrants. The bowel segments were pushed to the left side. Because of these findings our preoperative diagnosis was not ovarian cyst. Upon exploration, the right ovary with the cyst was autoamputated and we thought that it had adhered to the ileum during the antenatal period. It may be concluded that inflammation and ischemia resulted in amputation of the ovarian cyst. The amputated ovary may either completely resorbed or detached and become a loose calcified fibrotic nodule that moves freely in the peritoneal cavity, often in the cul-de-sac. It has been reported that occasionally an ovary that became detached in a neonate resulted in a cystic mass containing necrotic

material and a solid, partially calcified mural node. The cysts were attached to the omentum, the mesentery, or other intraperitoneal organs by a long, twisted pedicle containing thin-walled vascular spaces (8).

After birth, the decrease in hormonal stimulation is associated with spontaneous regression of most small ovarian cysts. Simple ovarian cysts less than 4 cm in diameter can be observed using serial ultrasonography. Neonatal ovarian cysts or cystic ovaries greater than 4 cm in diameter should be excised, even if asymptomatic, because they are prone to or have undergone torsion, and in many torsion occurs antenatally. The treatment of cysts larger than 4 cm includes gonad sparing surgery, laparoscopic needle aspiration, or laparoscopy (10).

We present this case since its appearance is rare. Autoamputated ovarian cysts should be considered in the differential diagnosis of mobile abdominal masses with atypical localizations.

## References

1. Schmähmann S, Haller JO. Neonatal ovarian cysts: pathogenesis, diagnosis and management. *Pediatr Radiol* 1997; 27: 101-105.
2. Maninolfi FG, Standiford JWE, Hubbard TB. Ruptured ovarian cyst in the newborn. *J Pediatr Surg* 1968; 3: 612-616.
3. Nussbaum AR, Sanders RC, Hartman DS, Dudgeon DL, Parmley TH. Neonatal ovarian cysts: sonographic-pathologic correlation. *Radiology* 1988; 168: 817-821.
4. Özkol M, Ovalı GY, Tunçyürek Ö, Şencan A, Pabuççu Y. Amputated tuba-ovarian torsion in a newborn. *Turk J Med Sci* 2005; 35: 337-339.
5. Alrabeeh A, Galliani CA, Giacomantonio M, Heifetz SA, Lau H. Neonatal ovarian torsion: report of three cases and review of the literature. *Pediatr Pathol*, 1988; 8: 143-149.
6. Avni EF, Godart S, Israel C, Schmitz C. Ovarian torsion cyst presenting as a wandering tumour in a newborn: antenatal diagnosis and postnatal assessment. *Pediatr Radiol* 1983; 13: 169-171.
7. Aslam A, Wong C, Haworth JM, Noble HR. Autoamputation of ovarian cyst in an infant. *J Pediatr Surg* 1995; 30: 1609-1610.
8. Currarino G, Rutledge JC. Ovarian torsion and amputation resulting in partially calcified pedunculated cystic mass. *Pediatr Radiol* 1989; 19: 395-399.
9. Stoupis C, Ros PR, Abbitt PL, Burton SS, Gauger J. Bubbles in the belly: imaging of cystic, mesenteric or omental masses. *Radiographics* 1994; 14: 729-737.
10. Shah A, Shah A. Laparoscopic removal of twisted ovarian cyst in a 22 hour old neonate. *Letters to the editor. Indian Pediatrics* 2003; 40: 800-801.