

1-1-2007

## Supernumerary Tooth in the Nose

CENGİZ ÖZTÜRK

KERİM ERYILMAZ

BİNALİ ÇAKUR

Follow this and additional works at: <https://journals.tubitak.gov.tr/medical>



Part of the [Medical Sciences Commons](#)

---

### Recommended Citation

ÖZTÜRK, CENGİZ; ERYILMAZ, KERİM; and ÇAKUR, BİNALİ (2007) "Supernumerary Tooth in the Nose," *Turkish Journal of Medical Sciences*: Vol. 37: No. 4, Article 8. Available at: <https://journals.tubitak.gov.tr/medical/vol37/iss4/8>

This Article is brought to you for free and open access by TÜBİTAK Academic Journals. It has been accepted for inclusion in Turkish Journal of Medical Sciences by an authorized editor of TÜBİTAK Academic Journals. For more information, please contact [academic.publications@tubitak.gov.tr](mailto:academic.publications@tubitak.gov.tr).

## Supernumerary Tooth in the Nose

Cengiz ÖZTÜRK<sup>1</sup>  
Kerim ERYILMAZ<sup>2</sup>  
Binali ÇAKUR<sup>3</sup>

**Abstract:** The presence of a supernumerary tooth in the nose is an unusual phenomenon and a rare form of ectopic tooth eruption in the maxillofacial region. In this case, the patient was referred to the hospital with the complaint of severe headache. In the endoscopic examination, the supernumerary tooth crown was not covered with mucosa or granulation tissue. In the present study, the clinical and radiological diagnosis of a supernumerary tooth located in the nose is reported.

**Key Words:** Tooth, supernumerary, nose

### Burunda Süpernumerer Diş

**Özet:** Burun içerisinde süpernumerer dişin görülmesi nadir bir olgudur ve maksillofasiyal bölgede gelişen ektopik dişlerin nadir bir şeklidir. Bu vakada hasta şiddetli baş ağrısı şikâyeti ile hastaneye başvurdu. Endoskopik muayenede, süpernumerer diş kuru mukoza ve granülasyon dokusu ile kaplı değildi. Bu çalışmada burun içerisindeki süpernumerer dişin klinik ve radyolojik teşhisi rapor edildi.

**Anahtar Sözcükler:** Diş, süpernumerer, burun

### Introduction

Extra teeth are usually termed as supernumerary. However, some authors reserve this term to describe abnormally formed extra teeth, while others apply the term "supplemental" to extra teeth having the shape and size of normal teeth (1). Ectopic teeth have been commonly found in the palate and maxillary sinus. They have been reported in the mandibular condyle, coronoid process, nasal and orbital cavities, inferior nasal concha, and through the skin (2-5). In rare cases, they are reported in a variety of uncommon locations, including the anterior mediastinum, retroperitoneal area, pre-sacral region, coccygeal region, ovaries, and testes (6). The presence of a supernumerary tooth in the nose is an unusual phenomenon, and the etiology is not completely understood. However, some factors regarding the origin of supernumerary teeth have been proposed, including obstruction at the time of tooth eruption secondary to crowded dentition, persistent deciduous teeth, dens bone, a genetic predisposition, developmental disturbances such as a cleft palate, infections, and displacement as a result of trauma, cysts or operations (1,4,5,7). Tooth eruption in the nose may cause recurrent or chronic sinusitis, nasal or cheek pain, speech problems, nasal obstruction, recurrent epistaxis, headache, nasal discharge, localized ulceration, foul smell, external deviation of nose, or nasal septal abscess (4,8-12). An intranasal tooth is sometimes asymptomatic and may present in clinical practice as an asymptomatic dense radiopaque shadow on routine radiological examination (3,4,7,13). In the clinical and endoscopic examination, computed tomography (CT) scanning and routine orthodontic radiographs can be helpful in diagnosis and treatment plan.

### Case Report

A 27-year-old woman applied to the otorhinolaryngology polyclinic with the complaint of headache, which continuously referred to left facial site, especially around the middle region of the face, for three months. She had frequently received treatment

<sup>1</sup> Department of Anatomy,  
Numune Hospital,  
Erzurum - TURKEY

<sup>2</sup> Department of Otorhinolaryngology,  
Numune Hospital,  
Erzurum - TURKEY

<sup>3</sup> Department of Oral Diagnosis and  
Radiology, Faculty of Dentistry,  
Atatürk University,  
Erzurum - TURKEY

Received: March 06, 2007  
Accepted: July 20, 2007

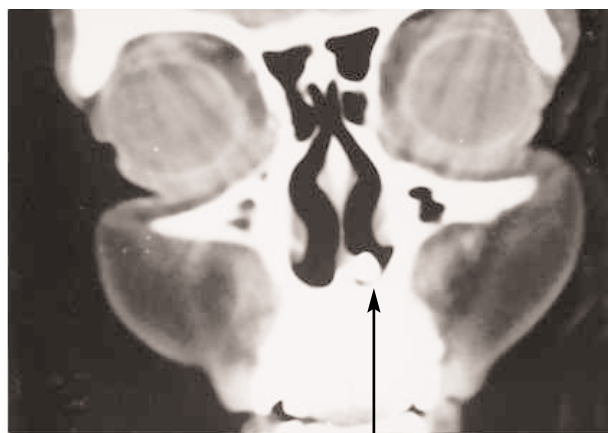
#### Correspondence

Binali ÇAKUR  
Department of Oral Diagnosis  
and Oral Radiology  
Faculty of Dentistry,  
Atatürk University  
25240 Erzurum - TURKEY

bcakur@atauni.edu.tr

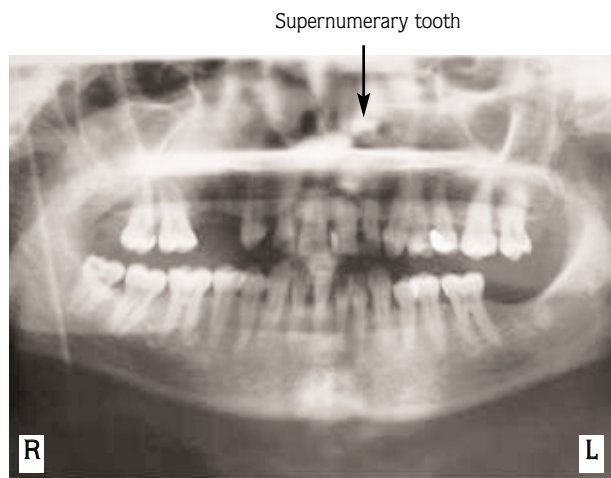
for maxillary sinusitis during the last four years. In the endoscopic examination, a supernumerary tooth was seen, displaying an inverted position. It was localized in the left nasal cavity, very close to the inferior turbinate, in contact with the nasal septum, approximately 15 mm proximal to the left nasal sill. It had a white-colored crown, and was 4 mm in diameter and 7 mm in length. The crown was not covered with mucosa or granulation tissue. The intraoral examination revealed that the maxillary right first and second premolars were absent. General medical history of the patient revealed that they had been extracted. CT of the paranasal sinuses showed a radiopaque mass resembling a tooth which was inverted onto the processus palatinus maxillae and partially exposed into the left nasal cavity (Figure 1). Panoramic

radiography revealed an inverted tooth with a crown above the nasal floor, and a normal intraoral dentition (Figure 2). Periapical radiography showed a well-defined radiopacity consistent with the ectopic tooth (Figure 3). The tooth was dislocated from its site of impaction and extracted with Blakesley nasal forceps through the left nostril under local anesthesia. The removed tooth was an abnormal complete tooth including radix, cervix and crown. It was an incisor-like tooth with 12 mm length and was abnormally white-colored. Cervix and most of the radix of the extracted tooth were covered with mucosa or granulation tissue (Figure 4). Postoperative nasal bleeding was controlled with nasal packing and the patient was discharged after two days.



Supernumerary tooth

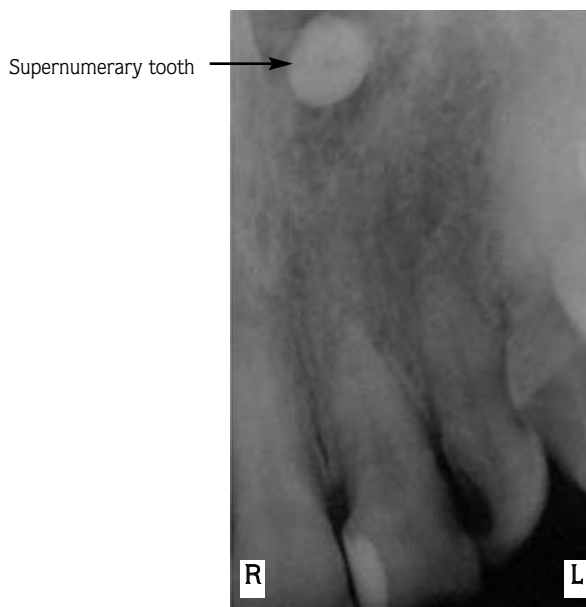
Figure 1. Coronal computed tomography of the paranasal sinuses.



Supernumerary tooth



Figure 2. Panoramic radiography.



Supernumerary tooth

Figure 3. Periapical radiography.

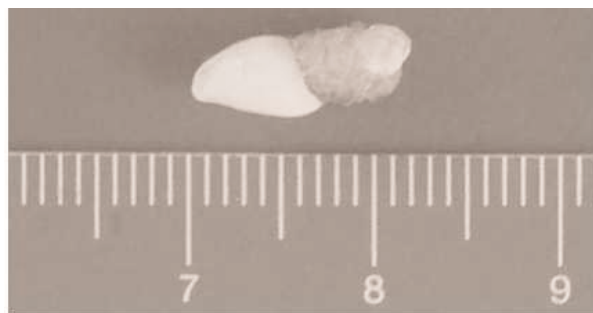

Figure 4. Removed tooth was of complete character with a length of 12 mm.

## Discussion

In general, the incidence of supernumerary teeth ranges from 0.1–1% in the population and the most commonly affected location is the upper central incisor area. A tooth existing in the nasal cavity is an unusual phenomenon and a rare form of supernumerary teeth (1). They may appear in the palate or in the nasal cavity (Figure 1) (9). They may be in vertical, horizontal, or inverted position (Figure 1) (2,9). It has been found that extra teeth have abnormal appearance (Figure 4) (9). Intranasal teeth may cause a variety of symptoms, but can be asymptomatic as well. These situations may be explained anatomically. The pain sense of the intranasal mucosa, which is a kind of superficial sense, referred to the facial half. However, subconscious proprioceptive senses associated with the periosteum and the bones are commonly asymptomatic. Aspergillosis, rhinitis caseosa with septal perforation and naso-oral fistula have been reported as complications associated with nasal teeth (9). The diagnosis was based on clinical and radiological findings. Clinically, an intranasal tooth may be seen to be embedded in the mucosa of the nasal cavity completely or incompletely in the endoscopic examination (Figures 1–4) (3). The differential diagnosis of intranasal mass should be made by evaluating for nasal foreign bodies, rhinoliths, neoplasm, exocytosis, and granulomatous infections (2,9). Radiologically, CT scan may be helpful in diagnosis and treatment plan. However, a nonspecific opacity may not confirm the diagnosis on every occasion (3). Early extraction is the treatment for intranasal tooth to avoid potential morbidity or complications. Periodical radiographic examination is advised if the tooth is not to be extracted. The most appropriate time for removal of ectopic teeth is after their development, in order to minimize the complications that may arise due to their eruption course (9). The endoscopic surgical approach

used in this case caused less morbidity compared to the conventional methods related to removal of ectopic tooth. We present a successful removal of an intranasal supernumerary tooth.

Mechanisms of ectopic eruption are not completely understood. However, some theories have been proposed, including a development resulting from a reversion to the dentition of extinct primates which had three pairs of incisor teeth (1), a defect in migration of neural crest derivatives destined to reach the jaw bones (5), or a multi-step epithelial-mesenchymal interaction (5,14). Supernumerary teeth appear in both children and adults (4), and sometimes may appear in unusual locations (6). Considering these situations, the more plausible theory is epithelial-mesenchymal interaction. Other situations, such as an accessory eruption arising from the permanent tooth bed (1) and in which each tooth develops a self-specific development (5), support the epithelial-mesenchymal interaction theory. One or more numerous etiologic factors may predispose to beginning the epithelial-mesenchymal interaction. We also speculate that the long-term increasing irritation of bones or of periosteal proprioceptive sense (factors such as operations, cleft palate, infection, dens bone, wound healing, genetic effect) have an efferent effect destined to the region of irritation with the central modulation (like cerebellum), which may begin the epithelial-mesenchymal interaction.

In conclusion, etiologies of supernumerary teeth are most likely varied, and epithelial-mesenchymal interaction is important in the tooth development. The diagnosed intranasal teeth should generally be extracted under endoscopic guidance to avoid morbidity and complications. Such extraction also has the advantages of good illumination and clear visualization.

## References

1. Thawley SE, Ferriere KA. Supernumerary nasal tooth. *Laryngoscope* 1977; 87: 1770–1773.
2. Nastri AL, Smith AC. The nasal tooth: case report. *Aust Dent J* 1996; 41(3): 176–177.
3. Kim DH, Kim JM, Chae SW, Hwang SJ, Lee SH, Lee HM. Endoscopic removal of an intranasal ectopic tooth. *Int J Paediatr Otorhinolaryngol* 2003; 67(1): 79–81.
4. Gupta YK, Shah N. Intranasal tooth as a complication of cleft lip and alveolus in four year old child: case report and literature review. *Int J Paediatr Dent* 2001; 11(3): 221–224.
5. Ray B, Singh LK, Das CJ, Roy TS. Ectopic supernumerary tooth on the inferior nasal concha. *Clin Anat* 2006; 19: 68–74.
6. Zeitler DM, Kanowitz SJ, Lee KC, Lebowitz RA. Radiology quiz case 1. Diagnosis: supernumerary intranasal tooth. *Arch Otolaryngol Head Neck Surg* 2006; 132(10): 1152–1154.

7. Moreano EH, Zich DK, Goree JC, et al. Nasal tooth. *Am J Otolaryngol* 1998; 19: 124–126.
8. Medeiros AS, Gomide MR, Costa B, Carrara CF, das Neves LT. Prevalence of intranasal ectopic teeth in children with complete unilateral and bilateral cleft lip and palate. *Cleft Palate Craniofac J* 2000; 37(3): 271–273.
9. Chen A, Huang JK, Chang SJ, Sheu CY. Nasal teeth: report of three cases. *Am J Neuroradiol* 2002; 23(4): 671–673.
10. Kuroda H, Tsutsumi K, Tomisawa H, Koizuka I. A case of an inverted tooth in the nasal cavity. *Auris Nasus Larynx* 2003; 30: 127–129.
11. Ondzotto G. Ectopic tooth in the nasal cavity. *Rev Stomatol Chir Maxillofac* 2003; 104(6): 352–354.
12. Meijer BA, van der Wal KG. Unilateral nasal bleeding due to an intranasal tooth. *Ned Tijdschr Tandheelkd* 2003; 110(9): 362–364.
13. Mc Keown HF, Sandler PJ. A nasal foreign body detected on routine orthodontic radiographs. *Br Dent J* 1998; 185(8): 390–391.
14. Büyükkurt MC, Tozoglu S, Aras MH, Yolcu Ü. Ectopic eruption of a maxillary third molar tooth in the maxillary sinus: a case report. *J Contemp Dent Pract* 2005; 3(6): 104–110.