

1-1-2007

## A Real-Time Transthoracic Echocardiographic Imaging of Pulmonary Embolism in a Patient with Suspected Primary Antiphospholipid Syndrome

HASAN KOCATÜRK

M. CENGİZ ÇOLAK

MUSTAFA YILMAZ

EDNAN BAYRAM

SEBAHATTİN ATEŞAL

Follow this and additional works at: <https://journals.tubitak.gov.tr/medical>



Part of the [Medical Sciences Commons](#)

---

### Recommended Citation

KOCATÜRK, HASAN; ÇOLAK, M. CENGİZ; YILMAZ, MUSTAFA; BAYRAM, EDNAN; and ATEŞAL, SEBAHATTİN (2007) "A Real-Time Transthoracic Echocardiographic Imaging of Pulmonary Embolism in a Patient with Suspected Primary Antiphospholipid Syndrome," *Turkish Journal of Medical Sciences*: Vol. 37: No. 5, Article 11. Available at: <https://journals.tubitak.gov.tr/medical/vol37/iss5/11>

This Article is brought to you for free and open access by TÜBİTAK Academic Journals. It has been accepted for inclusion in Turkish Journal of Medical Sciences by an authorized editor of TÜBİTAK Academic Journals. For more information, please contact [academic.publications@tubitak.gov.tr](mailto:academic.publications@tubitak.gov.tr).

## A Real-Time Transthoracic Echocardiographic Imaging of Pulmonary Embolism in a Patient with Suspected Primary Antiphospholipid Syndrome

Hasan KOCATÜRK<sup>1</sup>  
Mehmet Cengiz ÇOLAK<sup>2</sup>  
Mustafa YILMAZ<sup>3</sup>  
Ednan BAYRAM<sup>4</sup>  
Sebahattin ATEŞAL<sup>5</sup>

**Abstract:** Clinical manifestations of antiphospholipid syndrome (APS) include repeated episodes of arterial and/or venous thrombosis, recurrent fetal wastage, and premature births. Correct diagnosis of APS requires identification of lupus anticoagulant (LA) and anticardiolipin antibodies (aCL). Other antibodies such as anti-β<sub>2</sub> glycoprotein-I have also been detected. A 32-year-old man presented with acute left-sided hemiplegia and was admitted with a possible diagnosis of primary APS. A pulmonary embolus-in-transit was captured incidentally by transthoracic echocardiographic study.

**Key Words:** Intracardiac thrombus, real-time pulmonary embolism

### Primer Antifosfolipid Sendromu Şüphesi Olan Bir Hastada Pulmoner Embolinin Transtorasik Ekokardiografi ile Gerçek Zamanlı Olarak Görüntülenmesi

**Özet:** Antifosfolipid sendromunda gebelikte fetal kayıp, prematüre doğum, vasküler yatakta trombus oluşumu ve pulmoner/ sistemik embolizasyon görülmektedir. Antifosfolipid sendrom tanısında lupus antikoagulanı (LA) ve antikardiyolipin antikörleri (aCL) kullanılmaktadır. Anti-beta glikoprotein I gibi diğer antikörler de kullanılmaktadır. 32 yaşında antifosfolipid sendromu şüphesi olan erkek hasta akut sol taraf hemiplejisi ile başvurdu. Transtorasik ekokardiyografide tesadüfen pulmoner emboli gerçek zamanlı olarak görüntülendi.

**Anahtar Sözcükler:** intrakardiyak trombus, gerçek zamanlı pulmoner emboli

### Introduction

Clinical manifestations of antiphospholipid syndrome (APS) include fetal loss in pregnancy, premature births, vascular thrombosis, and pulmonary and systemic thromboembolism<sup>1</sup>. We report an unusual case of real-time transthoracic echocardiographic demonstration of acute pulmonary embolism in a patient with primary APS.

### Case Report

A 32-year-old man presented with left-sided hemiplegia. Physical examination findings were: rhythmic pulse, 90 bpm; blood pressure, 110/70 mmHg; left-sided hemiplegia involving arm and leg, and a left Babinski sign. Computed tomographic scan of the brain demonstrated an ischemic cerebral infarction.

Transthoracic echocardiography showed a three-lobular and mobile thrombus moving freely in the right atrium. The thrombus suddenly passed from the right atrium into the right ventricular cavity through the tricuspid valve and then into the right ventricular outflow tract during echocardiographic examination (Figures 1-3). Acute pulmonary embolism was definite and intravenous heparin was started. Since no wall motion abnormality or paradoxical septal motion was seen in serial echocardiograms, thrombolytic treatment was not considered.

<sup>1</sup> Department of Cardiology, Şifa Medical Center, Erzurum - TURKEY

<sup>2</sup> Department of Cardiovascular Surgery, Şifa Medical Center, Erzurum - TURKEY

<sup>3</sup> Second Department of Cardiology, High Education Training and Research Hospital, Bursa - TURKEY

<sup>4</sup> Department of Cardiology, State Hospital, Erzurum - TURKEY

<sup>5</sup> Department of Cardiology, Medical Faculty Hospital, Atatürk University, Erzurum - TURKEY

Received: May 08, 2007  
Accepted: October 10, 2007

#### Correspondence

Hasan KOCATÜRK  
Department of Cardiology,  
Şifa Medical Center,  
Erzurum - TURKEY

kocaturk73@yahoo.com

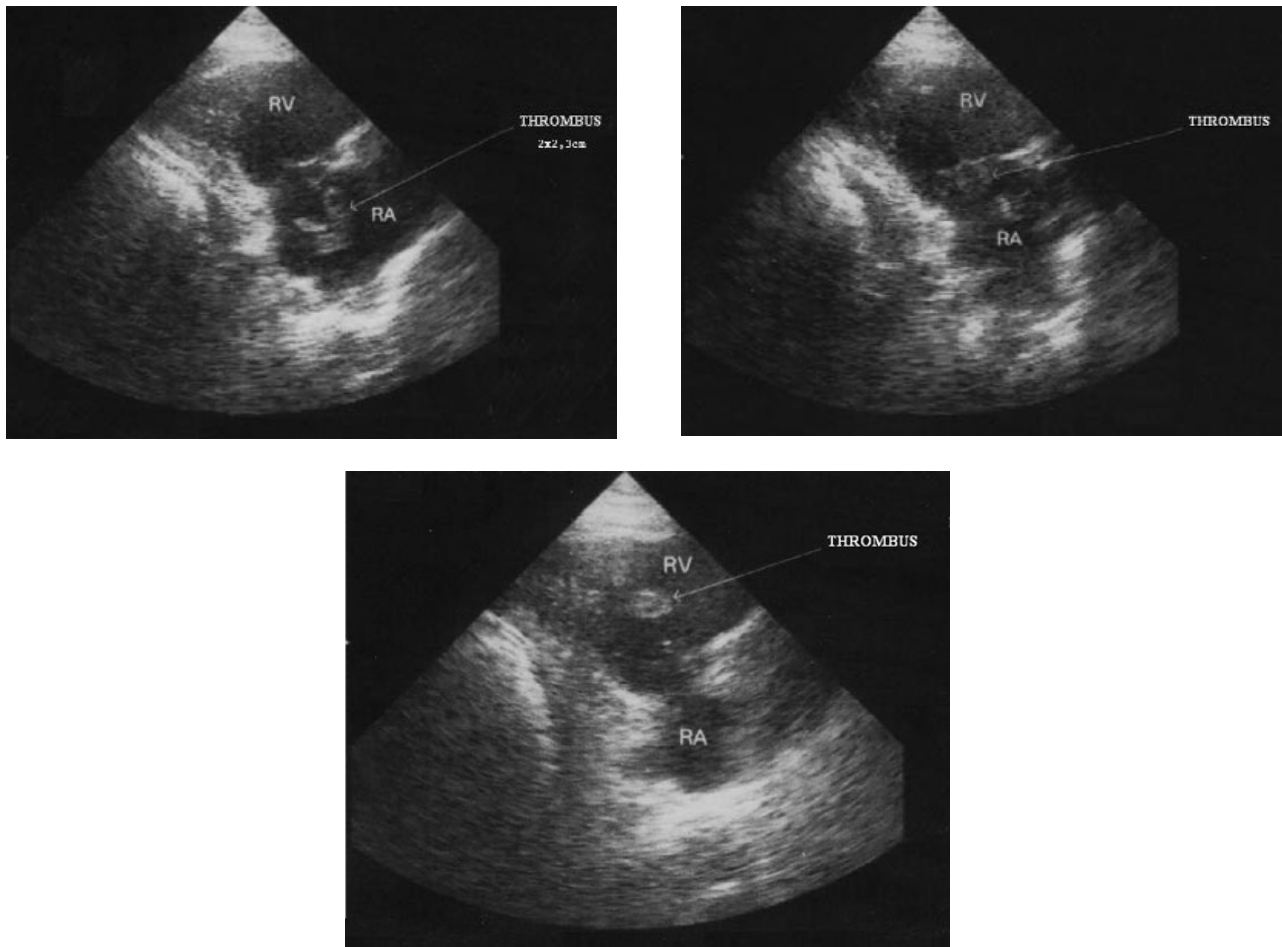


Figure 1-2-3. The real-time images disclosing the acute pulmonary embolism. Modified transthoracic echocardiographic view showing a three-lobular and mobile thrombus 2x2.3 cm in diameter moving freely in the right atrium (Figure 1), the passage of the thrombus from the right atrium into the right ventricular cavity (Figure 2) and then into the right ventricular outflow tract (Figure 3).

Ischemic cerebral infarction concomitant with pulmonary embolism forced us to consider a hypercoagulable disorder. Antinuclear antibody, anti-double-stranded DNA antibody, rheumatoid factor and lupus anticoagulant were found to be negative. Plasma homocysteine and antithrombin III levels were within normal limits. There was no evidence of factor V Leiden mutation or protein C, S deficiencies. International normalized ratio (INR) level was 1.8 due to previous warfarin therapy. However, anticardiolipin IgG and IgM antibodies were present in high titer in blood on two separate occasions, suggestive of primary APS.

Warfarin therapy was started, keeping INR between 2 and 3. PredischARGE transesophageal echocardiographic examination excluded the possibility of patent foramen

ovale (PFO). The patient was discharged with hemiparesis and long-term warfarin therapy was recommended. Because anticardiolipin titers were not tested at a six-week interval, the diagnosis of primary APS could not be confirmed.

### Discussion

This is an unusual case of a real-time detection of "thrombus-in-transit" resulting in a pulmonary embolism due to APS. Clinical manifestations of APS include repeated episodes of arterial and/or venous thrombosis, recurrent fetal wastage, premature births, thrombocytopenia and cardiac abnormalities (1-3). High titers of anticardiolipin antibodies, which probably affect

the function of the endothelial cell membrane and promote thrombus formation, are associated with a high risk of thrombosis (3,4).

This case appears to be rare because of the coexistence of arterial and venous thromboemboli. Left-sided hemiplegia might have resulted from the left-sided intracardiac thrombus, but we could not detect any thrombus formation in his left ventricle or atrium during echocardiography. Since foramen ovale was not patent in the patient, paradoxical thromboemboli was not likely to occur. Previous studies reported the relatively high prevalence of coagulation abnormalities in patients with ischemic stroke and PFO, but the exact prevalence of PFO in hypercoagulable patients is not known. Although the best therapeutic strategy is also not known, patients with a procoagulant tendency and PFO should be treated with warfarin (5,6).

The optimal therapeutic approach in patients with APS is still unknown. Patients who have already experienced thrombotic events must be treated with warfarin, maintaining an INR of 2.0 to 3.0. (1). Some propose that INR should be kept higher (between 3-4) or that aspirin or heparin should be added in resistant cases (7).

However, though a low rate of recurrent thrombosis in both regimens has been reported, the lower dose of warfarin (target INR, 2.0 to 3.0) was as effective as the higher dose (target INR, 3.1 to 4.0) in patients who had previous thrombosis (8).

Successful primary surgical resection of intracardiac thrombus has been reported in some patients (3-5,9,10). If surgical removal is not done for any reason, anticoagulation should be initiated. Patients who experienced thromboembolic events must have life-long anticoagulation (1). Willens et al. (2) reported thrombus in the left ventricular outflow tract in a patient with APS, successfully treated with heparin therapy. Treatment with low-dose aspirin (50-100 mg/day) provides a protection against thrombosis in women with pregnancy loss due to APS. This approach is the accepted standard for the prevention of pregnancy loss (1,11). Patients resistant to warfarin therapy may also require low-dose aspirin treatment (7).

This case appears to be rare because pulmonary embolus-in-transit was captured incidentally by transthoracic echocardiographic study.

## References

1. Cervera R, Asherson RA. Clinical and epidemiological aspects in the antiphospholipid syndrome. *Immunobiology* 2003; 207: 5 - 11.
2. Willens HJ, Lowery MH, Lopez E, Ewing MH, Myerburg RJ. Rapid resolution of left ventricular thrombus in antiphospholipid syndrome. *Echocardiography* 2003; 20: 67-70.
3. Mottram PM, Gelman JS. Mitral valve thrombus mimicking a primary tumor in the antiphospholipid syndrome. *J Am Soc Echocardiogr* 2002; 15: 746-8.
4. Aguilar JA, Summerson C. Intracardiac thrombus in antiphospholipid antibody syndrome. *J Am Soc Echocardiogr* 2000; 13: 873-5.
5. Thompson CA, Skelton TN. Thromboembolism in the right side of the heart. *South Med J* 1999; 92: 826-30.
6. Chaturvedi S. Coagulation abnormalities in adults with cryptogenic stroke and patent foramen ovale. *J Neurol Sci* 1998; 160: 158-60.
7. Safley DM, McCullough PA. Antiphospholipid syndrome with renal artery embolism: case report. *Rev Cardiovasc Med* 2002; 3: 196-201.
8. Crowther MA, Ginsberg JS, Julian J, Denburg J, Hirsh J, Douketis J et al. A comparison of two intensities of warfarin for the prevention of recurrent thrombosis in patients with the antiphospholipid antibody syndrome. *N Engl J Med* 2003; 349: 1133-8.
9. Yusuf S, Madden BP, Pumphrey CW. Left atrial thrombus caused by the primary antiphospholipid syndrome causing critical functional mitral stenosis. *Heart*. 2003; 89: 262.
10. Brancaccio G, Di Gioia C, Prifti E, D'Amati G, Michielon G, Miraldi F. Antiphospholipid antibodies and intracardiac thrombosis. A case report. *J Cardiovasc Surg* 2002; 43: 479-82.
11. Erkan D, Merrill JT, Yazici Y, Sammaritano L, Buyon JP, Lockshin MD. High thrombosis rate after fetal loss in antiphospholipid syndrome: effective prophylaxis with aspirin. *Arthritis Rheum* 2001; 44: 1466-7.